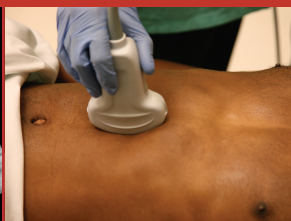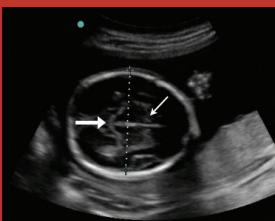

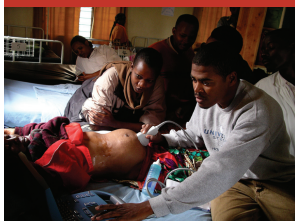


Partners
In Health

Over 20 years of health and social justice

MANUAL OF ULTRASOUND



FOR RESOURCE-LIMITED SETTINGS

Sachita Shah MD

Daniel Price MD

Gene Bukhman MD

Sachin Shah MD

Emily Wroe MD

The Partners in Health

Manual of Ultrasound for Resource Limited Settings

First Edition
2011

Partners in Health

Program in Infectious Disease and Social Change
Harvard Medical School

Division of Global Health Equity
Brigham and Women's Hospital

Co-Editors in Chief

Sachita P Shah MD

Director of Ultrasound Education, Partners in Health
Rwanda & Haiti

Director, Emergency Ultrasound Fellowship

Department of Emergency Medicine, Rhode Island Hospital
Providence RI USA

Daniel D Price MD

Director of International Ultrasound

Department of Emergency Medicine

Alameda County Medical Center

Oakland CA USA

Senior Advisor, Division of Global Health & Human Rights
Massachusetts General Hospital

Section Editors

Gene Bukhman MD PhD

Director, Program in Non-Communicable Disease & Social Change
Harvard Medical School

Director of Cardiology, Partners in Health

Boston MA USA

Sachin Shah MD MBA

Hospital Medicine Program

Beth Israel Deaconess Medical Center

Boston MA USA

Emily Wroe MD

Department of Medicine

Brigham & Women's Hospital

Boston MA USA

Chapter Authors

Ghada Bakhidar MD

Department of Emergency Medicine
Massachusetts General Hospital
Boston MA USA

Jennifer Carnell MD

Department of Emergency Medicine
Alameda County Medical Center
Oakland CA USA

Garry Choy MD MSc

International Radiology Exchange (iRadX.org)
Department of Radiology
Massachusetts General Hospital
Boston MA USA

Supriya Gupta MD

International Radiology Exchange (iRadX.org)
Department of Radiology
Massachusetts General Hospital
Boston MA USA

James Hwang MD RDMS RDCS

Department of Emergency Medicine
Brigham & Women's Hospital
Boston MA USA

Sung Han Kim MD

International Radiology Exchange (iRadX.org)
Department of Radiology
Mount Auburn Hospital
Boston MA USA

Heidi Kimberly MD

Department of Emergency Medicine
Brigham & Women's Hospital
Boston MA USA

Adam C Levine MD MPH

Department of Emergency Medicine
Rhode Island Hospital
Providence RI USA

Otto Liebmann MD

Department of Emergency Medicine
Rhode Island Hospital
Providence RI USA

Allison Mulcahy MD

Department of Emergency Medicine
Alameda County Medical Center
Oakland CA USA

Arun Nagdev MD

Department of Emergency Medicine
Alameda County Medical Center
Oakland CA USA

Vicki Noble MD

Department of Emergency Medicine
Massachusetts General Hospital
Boston MA USA

Teri Reynolds MD PhD

Departments of Emergency Medicine
& Global Health Sciences
University of California at San Francisco
San Francisco CA USA

Jacklin Saint-Fleur MD

Inshuti Mu Buzima/Partners in Health
Rwanda

Nathan Teismann MD

Department of Emergency Medicine
University of California at San Francisco
San Francisco CA USA

Brita Zaia MD

Department of Surgery
Division of Emergency Medicine
Stanford University Medical Center
Palo Alto CA USA

Case authors

**Department of Emergency Medicine
Rhode Island Hospital**

Meera Muruganandan MD

**Kigutu Hospital
Village Health Works, Burundi**

Melino Ndayizigiye MD

**Kirehe Hospital
Inshuti Mu Buzima/Partners in Health Rwanda**

Jean Marie Dushimiyimana MD

Raymond Dusabe MD

Felix Sayinzoga MD

**Butaro Hospital
Inshuti Mu Buzima/Partners in Health Rwanda**

Protogene Ngabitsinze MD

Juvenal Musavuli MD

Jean Nepomuscene Kamugisha MD

Illuminee Uwicyeza MD

Jacklin Saint-Fleur MD

Agaba Faustin MD

Butaro Hospital

Inshuti Mu Buzima/Partners in Health Rwanda

Egide Mpanumusingo MD

Tharcisse Kampunga

Leonidas Banyuzuwabo

Partners in Health Rwanda

Corrado Cancedda MD MPH

Hopital Bon Sauveur, Cange

Zanmi Lasante/Partners in Health Haiti

Joanel Joasil MD

Walkens Desir MD

Reginald Fils-Aime MD

Mackinley Saint Louis MD

Arnould Val MD

Romain Jean Louis MD

Jean Hamiltong Pierre MD

Contributors

David Elijah LaTouche

Photographic ultrasound model

Chris Gralapp

Medical illustrator

Thomas Ptak MD

Ultrasound images

Enrico Brunetti MD

Ultrasound images

Carlo Filice MD

Ultrasound images

Giovanna Ferraioli MD

Ultrasound images

Andrew Marx

Cover design

Sonosite

Image contribution

Phillips Healthcare

Image contribution

Published in the United States of America by Partners in Health.
Subject to the rights of Partners in Health, this publication may be freely reviewed, abstracted, reproduced, or translated provided that all copyright, trademark, and other proprietary notices are included in each such use. No portion of this publication may be sold or otherwise used or distributed in conjunction with any commercial purpose.

Copyright 2011 Partners in Health. All rights reserved under International and Pan-American Copyright Conventions.

Cover design by Andrew Marx.

Book design by Dan Price MD.

ISBN: 978-0-9828968-0-8

Notice

This guide is intended to be a resource for health care providers who use clinician-performed, point of care ultrasound while working in resource poor settings. The use of bedside ultrasound by health care providers has revolutionized care of patients worldwide, providing clinicians with immediate answers to clinical questions, and guiding procedures for improved safety. This book is a concise review of bedside, clinician-performed ultrasound, with focus on specific diagnostic questions and disease processes common in the developing world. The book should be used in conjunction with an ultrasound training course, and is not a substitution for practical training in ultrasound.

Every possible effort has been made to ensure that the material presented herein is accurate, reliable, and in accord with current standards. However, as new research and experience expand our knowledge, some recommendations for care and diagnosis may change. It is therefore the responsibility of the individual health care provider to use his/her best medical judgement in determining appropriate patient care.

To the maximum extent permitted under applicable laws, no responsibility is assumed and is hereby disclaimed by all parties involved in the production of this manual, including, without limitation, each of the contributors and authors, Partners in Health, Program in Infectious Disease and Social Change, Harvard Medical School; the Division of Global Health Equity, Brigham and Women's Hospital; and each of their affiliates, divisions, directors, officers, trustees, agents and employees, for errors, omissions, or any injury

and/or damage (actual or perceived) to persons or property as a result of any actual or alleged libelous statement, infringement of intellectual property or privacy rights, or product liability, whether resulting from negligence or otherwise, including, without limitation, from any reliance upon, use or operation of any ideas, instructions, procedures, products, or methods contained in the material included in this guide.

Mention of specific products, technologies or medications within this guide does not constitute endorsement by any of the above-named individuals or entities. With regard to specific medications, technology or products, health care providers are advised to consult their normal resources before prescribing to their patients.

Your use of this guide is provided on an “as is” basis without warranty of any kind, and none of the individuals or entities listed above represent or warrant that the information contained herein is complete or accurate or free from error.

By choosing to use this guide, you acknowledge and agree to the terms of this disclaimer.

Table of Contents

Foreword	14
Acknowledgements	17
Abbreviations	20

Chapters

Fundamentals	21
Trauma	37
Echocardiography	69
Obstetrics: 1 st Trimester	103
Obstetrics: 2nd & 3rd Trimesters	116
Liver	139
Gallbladder	181
Spleen	204
Kidney	222
Abdominal Aortic Aneurysm	243
Deep Venous Thrombosis	257
Volume Status	272
Bladder	284
Skin	292
Procedures	307
Vascular Access	332

Cases	353
--------------	------------

Foreword

Modern day public health began in the 1854 when John Snow first identified the source of the London Cholera Epidemic as the Broad Street pump. Snow's intervention was to take the handle off the pump, cutting off the flow of contaminated water to residents of the area. This approach to health — identifying a problem and preventing its spread — has been the platform of public health research and practice now for more than a century. It is widely viewed as the most efficient use of resources. Thus, for countries with constrained resources, the “public health approach” has been promoted widely in a variety of ways, from slogans such as “prevention is better than cure” to analysis of cost effectiveness, often pitting prevention against treatment. Yet while broad-based approaches to prevention have a role to play in improving the health of the poor, it is not the case that “prevention is better than cure,” particularly not if you are a person suffering from a disease. To improve the health of the world's poorest people, those among whom the burden of disease and suffering is greatest, medical care is needed. Yet, the delivery of health care — from the diagnosis of conditions to the treatment of a disease and from the enabling of health promotion via access to family planning or insecticide-treated nets against malaria or the consistent delivery of prevention such as infant vaccination — requires a robust health system. One which has adequate facilities to support the needs

of the community, a staff that is well trained, supervised and compensated, adequate diagnostic capability and sufficient medicines and supplies to deliver care. Sadly, this list, as inherently logical as it may seem, is a very tall order for most of the health systems in the developing world; as they have for decades been caught in a vicious cycle of under-resourcing leading to lack of staff and supplies leading to poor care and a resultant discounting of the ability to deliver medical diagnosis and treatment in such settings driving a focus on prevention.

The movement of antiretroviral access to treat people with AIDS has taught us much about the delivery of diagnosis and treatment of a complex disease in the setting of extreme poverty. We at Partners in Health have used the energy and funding around HIV to build and argue for strengthening health systems to deliver care and to provide a host of services within the public sector under the rubric of delivering health care as a right. Our first grant from the Global Fund to Fight AIDS, TB and Malaria in 2003 in Haiti marked the beginning of revitalizing public facilities to deliver a broad base of services in Haiti and is the very work that has lead us to be invited by Ministries of Health and other partners in Africa. As of 2010, PIH is supporting 60 public facilities in 12 countries around the world.

In the movement to establish health care as a right, building adequate diagnostic capability is essential. Few tools have proven more valuable in the hands of well-trained health

workers than ultrasound. Use of ultrasound in the hands of local providers is now part of our diagnosis and follow-up of heart failure, assessment of gestational age and pregnancy status, and the management of acute conditions from empyema to perforated viscus. Our field experience has informed many of the cases in this manual, and the cases have been used to train doctors in Haiti, Rwanda and elsewhere. It is our firm belief that providing the tool of ultrasound and adequate training and support is a critical component in global health delivery and should be part of the evolving pedagogy of global health.

We are privileged to have the leadership of Dr. Sachita Shah and many of our colleagues in the United States and abroad in creating this excellent manual for training and supporting providers to use ultrasound in resource-poor settings.

Joia S Mukherjee MD, MPH

Chief Medical Officer, Partners In Health

Associate Professor, Harvard Medical School

Acknowledgements

Sachita Shah

My life is enriched because of the love and support of my husband, Andrew, and my family, without whom we could not have gotten the book finished. I am so grateful for the guidance of my mentors in ultrasound and international health, Vicki Noble, Arun Nagdev, Hilarie Cranmer, Henry Epino, and Joia Mukherjee. Special thanks to my Partners in Health colleagues in Rwanda and Haiti, whose compassion and dedication to improving patient care continually inspires and rejuvenates me.

Dan Price

My deepest appreciation and love go out to my family: 1) My daughters Zoe and Maya, who tolerated a laptop on vacations and “I’ll be there in 10 more minutes”. Their play with kids all over the world inspires me. 2) My wife, Linda Christensen-Price MD MS, for her patience and advice as an obstetrician gynecologist, who has worked in under-resourced settings. 3) My friend and brother, David LaTouche, who worked many photo shoots into his schedule. 4) My contribution never would have been possible without the love and sacrifice of my mother, Kathleen Anderson, who I miss greatly.

Gene Bukhman

Thanks to Alice, my wife and colleague, who has worked together with me on this from the very beginning. My parents and grandmother. Our friends and coworkers at PIH and in the Rwandan Ministry of Health, especially Agnes Binagwaho, Joseph Mucumbitsi, Gene Kwan, Corrado Cancedda, Sara Stulac, Peter Drobac, Emilien Nkusi, Bonaventure Nzeyimana, Gedeon Ngoga, Symaque Dusabeyezu, Francis Mutabazi, Mariam Uwase, Valens Rudakubana, Cadet Mutumbira, Charlotte Bavuma, Emmanuel Rusingiza, and Nathan Ruhamy. To Paul Farmer, of course, who always sheds a light on the neglected problems of the poor, as well as Warren Manning, Elyse Foster, and Nelson Schiller who taught me what I know about echocardiography, and especially to our patients in Rwanda and Haiti.

Sachin Shah

The support that my family and wife, Allison, provide allows me to act on any passion I may have. My sister Sachita and Gene Bukhman have been great mentors to me. They have given me a glimpse into the wonderful world in which they work and the lovely patients they care for.

Emily Wroe

Deepest gratitude to my parents for their endless encouragement and support, to my siblings and best friends who always have a couch for me when I come home. And to my aunt and uncle whose generosity and support through the years have helped my path be possible. I am specifically grateful to my mentors, Peter Drobac and Sachita Shah among many others, for providing guidance, opportunities, and humor. And most of all, to my colleagues, patients, and teachers in Rwanda who have given me lifelong inspiration and motivation, and a home away from home.

Abbreviations

AAA	Abdominal Aortic Aneurysm
AIDS	Adult Immunodeficiency Syndrome
CT	Computed Tomography
CFV	Common Femoral Vein
CFA	Common Femoral Artery
CI	Caval Index
CVP	Central Venous Pressure
DPA	Diagnostic Peritoneal Aspiration
DPL	Diagnostic Peritoneal Lavage
DVT	Deep Venous Thrombosis
FAST	Focused Assessment with Sonography in Trauma
HIV	Human Immunodeficiency Virus
IVC	Inferior Vena Cava
LA	Left Atrium
LV	Left Ventricle
MRI	Magnetic Resonance Imaging
RV	Right Ventricle
RVOT	Right Ventricle Outflow Tract
RA	Right Atrium
SFV	Superficial Femoral Vein
SMA	Superior Mesenteric Artery
TB	Tuberculosis

Fundamentals

SACHITA SHAH MD

Introduction

This chapter will familiarize the reader with basic principles of ultrasound physics, instruments, understanding the probes and images, and maximizing image quality. Modes of scanning and artifacts will also be discussed.

Basic Principles

The ultrasound machine and probes create sound waves that cannot be heard by the human ear. These waves are generated from the probe, and travel through the tissues of the patient, and then return to the probe as they encounter tissues of different densities. The intensity of the returning echo determines brightness of the image on the screen. Strong signals produce white,

or *hyperechoic*, images. Weak echo signals returning to the probe translate into dark black, or *hypoechoic*, images on the ultrasound screen. Different tissues are shown in many shades of gray, from white to black, depending on their density.

Frequency is the number of times per second the sound wave is repeated, and diagnostic ultrasound uses waves that are generally between 2 to 15 MHz. Higher frequency ultrasound waves visualize superficial structures best, and create high resolution good quality images. Lower frequency ultrasound waves are able to penetrate better to visualize deeper structures. Different ultrasound probes are used to see deeper or more superficial in the body. In Figure 1, a linear probe can be used to see a superficial abscess of the skin with good quality images.

Conversely, a curved probe of lower frequency (Figure 2) can visualize deep structures, such as the aorta. The decision of which probe to use for a particular ultrasound exam is based on which frequency is most appropriate.

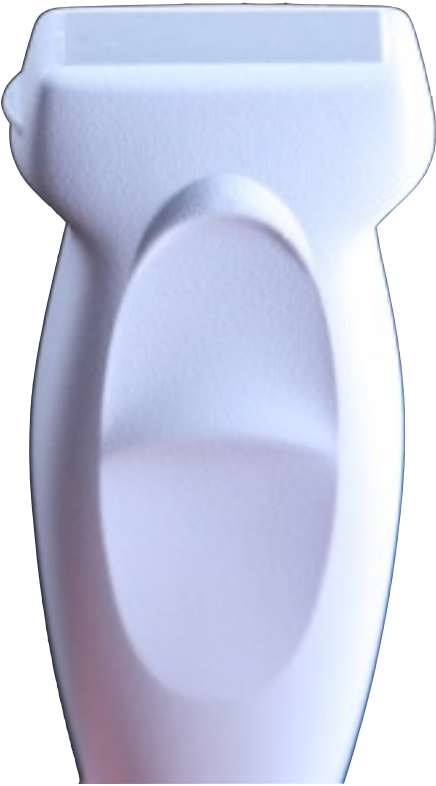

Figure 1. Linear probe



Figure 2. Curved transducer

Attenuation means that as the ultrasound beam travels through the body, it loses strength and returns less information to the probe as it goes deeper. Certain tissue densities, such as bone, diaphragm, pericardium, and air, slow the ultrasound beam, reflecting the waves and producing a bright or hyperechoic image. Other tissues

allow ultrasound beams to pass and reflect at moderate speeds, creating a gray image on the screen, such as muscle, liver or kidney. Some tissues allow ultrasound waves to pass easily and retain their strength, creating dark black or hypoechoic images on the ultrasound screen, such as blood, ascites, and urine.

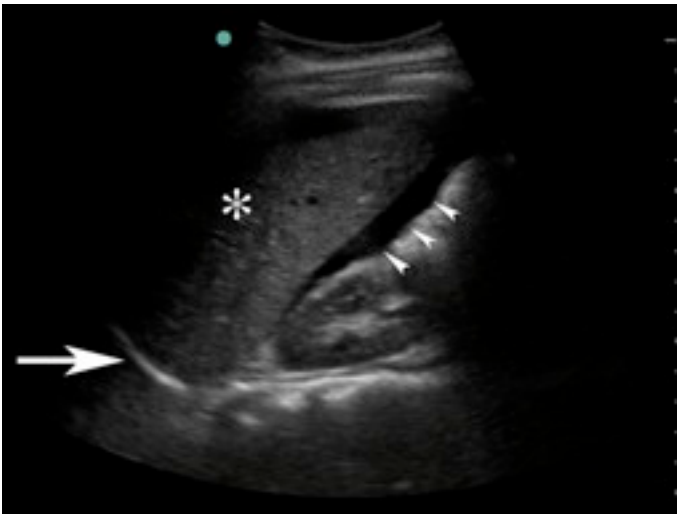


Figure 3. Free fluid in hepato-renal pouch appears black (arrowheads). The hyperechoic diaphragm appears bright white (arrow), and the moderately echogenic liver appears gray.

Basic Instrumentation and Transducer Use

Ultrasound waves are generated by an electric current that travels through quartz crystals in the probe surface. Ultrasound waves are emitted from these crystals, and are able to travel through tissues at varying speeds. Because air scatters the sound waves and creates poor quality images, it is necessary to use a liquid gel on the probe surface to improve the contact between the patient's skin and the probe surface. Water can also be used for this purpose (Figure 4).




Figure 4. Probe with gel (a) and water bath submersion (b)

The ultrasound probe should be held lightly in your hand with the probe marker facing the patient's right or toward the patient's head. For all ultrasound exams, except echocardiography, the probe marker is kept in this orientation. In the echocardiography chapter, other probe orientations are described. The probe marker is a

bump or marking on the side of the ultrasound probe that corresponds to a logo or dot on the top of the ultrasound screen (Figure 5).

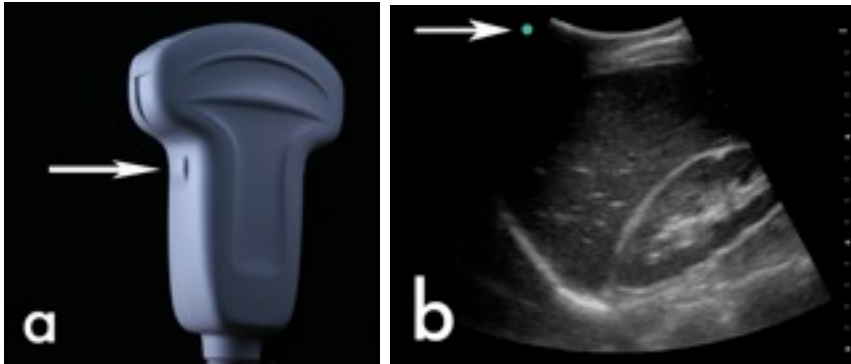


Figure 5. The probe marker (a) corresponds to the screen marker (b).

Use plenty of gel to improve your image quality and do not apply too much pressure to the skin with the ultrasound probe.

Improving Image Quality

Depth should be adjusted to improve the quality of the image by putting the object of interest in the center of the screen. On the right side of the ultrasound screen, markings show depth in centimeters (Figure 6).

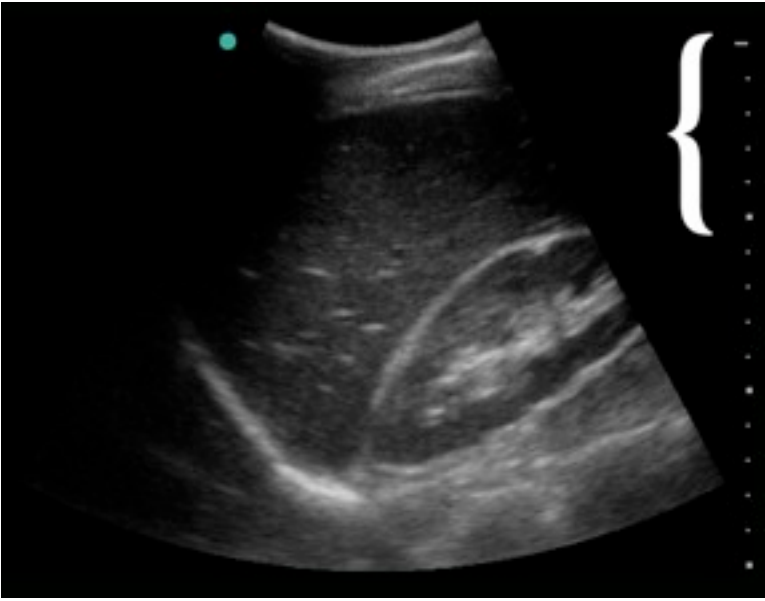


Figure 6. Depth markings on the ultrasound screen correspond to actual tissue depth.

Gain is the brightness of an image, and can be adjusted for each scan to ensure that dark hypoechoic objects such as urine or blood are black on the screen, while bright hyperechoic objects such as bone appear white. Be careful not to use too much or too little gain, as shown in Figure 7.

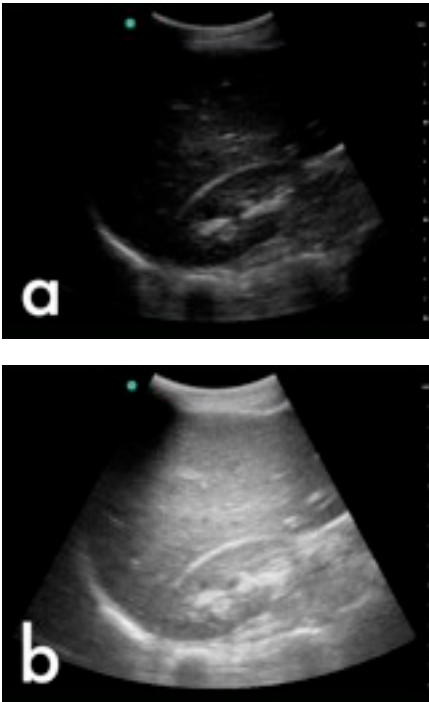


Figure 7. Gain is used to adjust the brightness of the screen. In 7a, the gain is too low or hypoechoic. In 7b, the gain is too high or hyperechoic.

Modes of Scanning

There are buttons on the side of the ultrasound machine labeled B, M mode, Color, and Doppler. These are the various scanning modes a sonographer can choose from. For usual diagnostic imaging, use B mode ultrasound. For visualizing motion, choose M-mode.

M Mode applies a reference line on the ultrasound screen that will show motion towards and away from the ultrasound probe at any depth along that line. M mode can be used to measure the fluttering of a fetal heartbeat, as shown in Figure 8.

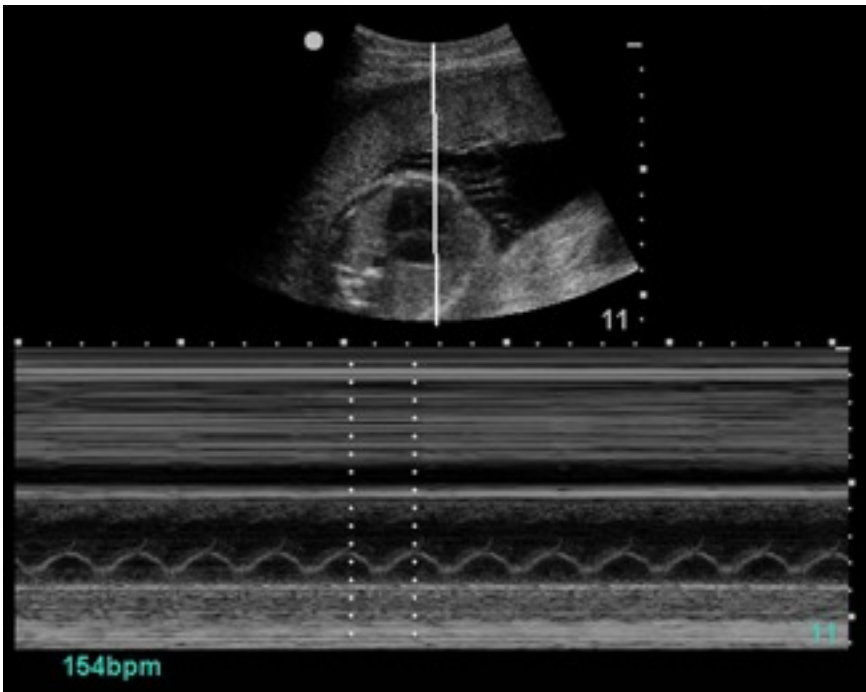


Figure 8. M mode allows measurement of fetal heart rate.

Color Doppler mode applies a reference box to your ultrasound image, within which you can see color representing motion toward or away from the probe. This can be helpful to identify motion within a vessel to

see if the vessel is patent. The blue or red color corresponds to direction of flow, but does not determine whether the vessel is an artery or vein.

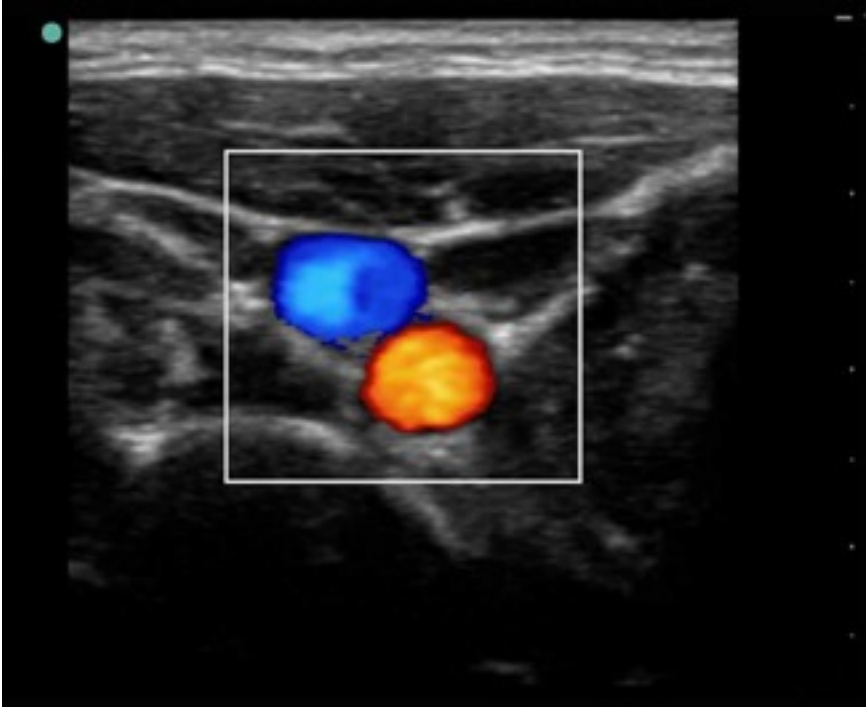


Figure 9. Color Doppler of vessels demonstrate active flow.

Spectral, or pulse wave Doppler, provides a reference point which is applied over a vessel of interest to hear and see changes in the flow over time as shown by changes in the Doppler waveform (Figure 10). This mode is useful for determining if a vessel is an artery or vein, or for

measuring the velocity of flow across an opening, such as a cardiac valve, to determine degree of stenosis.

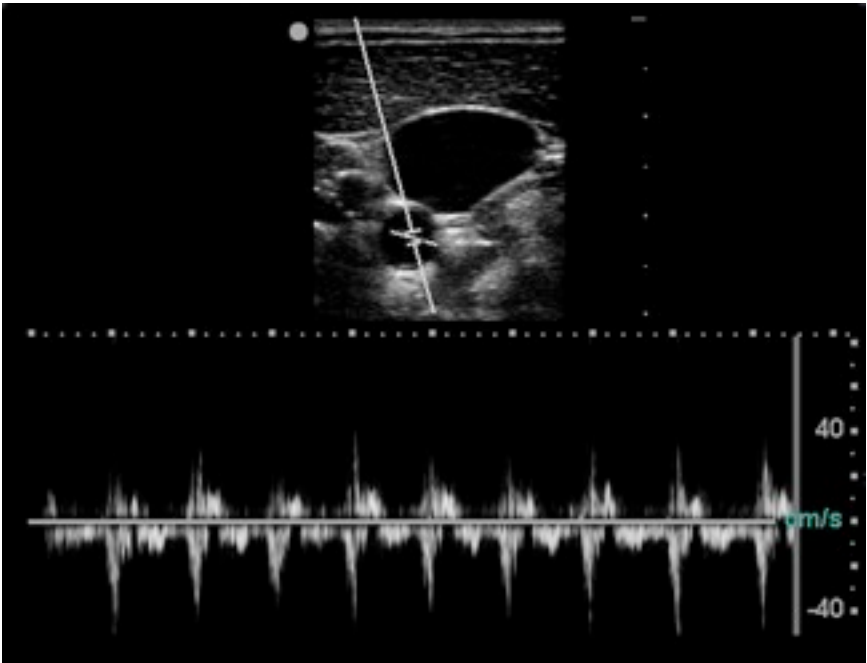


Figure 10. Pulse wave Doppler on a vessel shows pulsatile arterial flow.

Artifacts

Occasionally the ultrasound image will not truly reflect what is going on inside the body. Artifacts seen on the ultrasound screen are due to principles of ultrasound physics and how the machine processes them. Artifacts should be understood to avoid misdiagnosis.

Shadowing is an artifact that occurs deep to a very dense, hyperechoic structure, such as a gallstone or a rib. The dark line of a shadow is seen deep to the bright object, because the ultrasound waves reflect back towards the probe when they reach the highly reflective surface of a stone or bone (Figure 11).

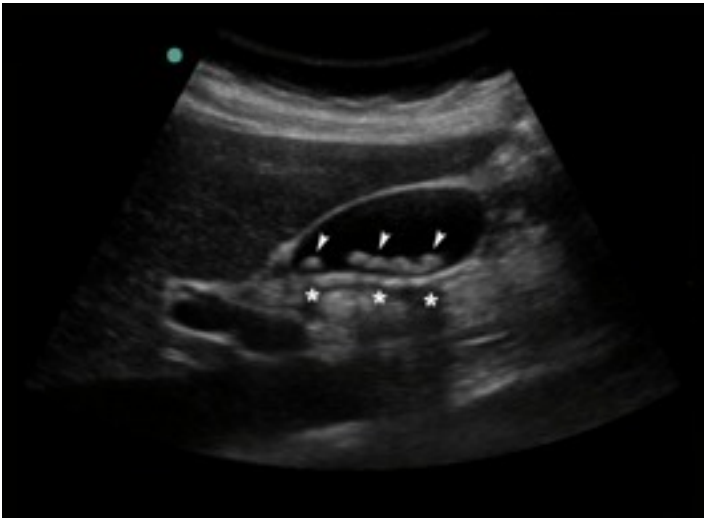

Figure 11. Gallstones (arrows) create shadow artifact (*).

Mirror Image Artifact occurs when an ultrasound beam is reflected multiple times. A false representation showing two images of a single object is created on the ultrasound screen. The mirrored object appears deeper compared to the real image of the object and will disappear if the probe position is changed.

Posterior Acoustic Enhancement occurs when ultrasound waves travel quickly through a low density medium, such as urine in the bladder, and then reflect back quickly from the next structure encountered that is higher in density, such as the posterior bladder wall. This causes structures deep to the hypoechoic object to become falsely hyperechoic, and may require you to adjust the gain.

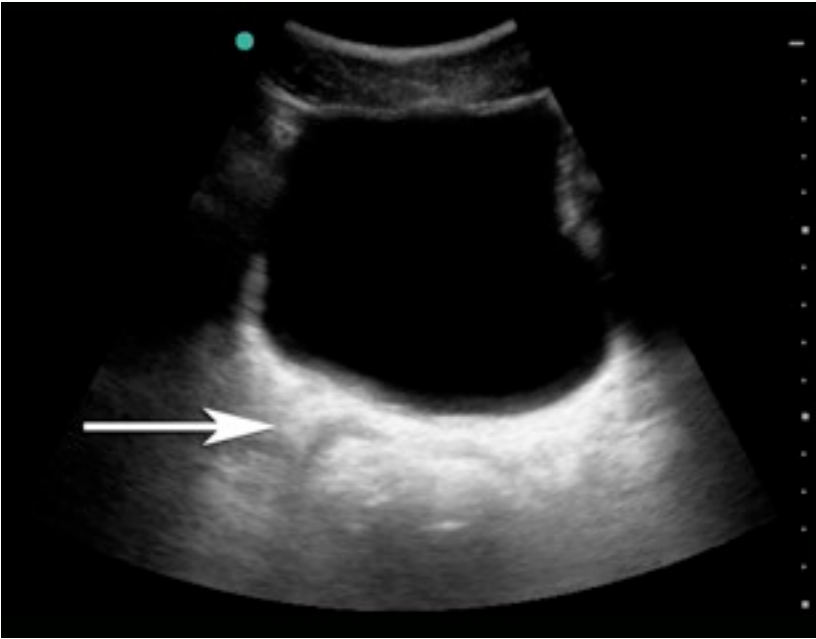


Figure 12. Posterior acoustic enhancement causes the area deep to the bladder (arrow) to appear hyperechoic.

Conclusion

Comprehension of ultrasound physics and instrumentation allows the sonographer to approach specific ultrasound exams and techniques with greater confidence. Try to develop ease with handling the ultrasound probe and machine controls. Be aware of artifacts that may change the interpretation of images. And, attempt to maximize image quality by adjusting depth and gain as needed.

Recommended reading

1. Brant WE. *Ultrasound: The Core Curriculum*. Philadelphia, PA: Lippincott Williams & Wilkins, 2001.
2. Cosby K, Kendall J. *Practical Guide to Emergency Ultrasound*. Philadelphia, PA: Lippincott Williams & Wilkins, 2006.
3. Lutz HT, Gharbi HA. *Manual of Diagnostic Ultrasound in Infectious Tropical Diseases*. Berlin, Germany: Springer, 2006.
4. Ma OJ, Mateer JR, Blaivas M. *Emergency Ultrasound*. New York, NY: McGraw-Hill, 2007.
5. Noble V, Nelson B, Sutingo AN. *Fundamentals. Manual of Emergency and Critical Care Ultrasound*. Cambridge, England: Cambridge University Press, 2007.
6. Rumack CM, Wilson SR, Charboneau JW. *Diagnostic Ultrasound*. 1st ed. St Louis, MO: Mosby, 1991.

Trauma

ALLISON MULCAHY MD

Introduction

Focused assessment with sonography for trauma (FAST) is a screening tool to identify free intrathoracic fluid, intraperitoneal fluid, pericardial effusion and pneumothorax in trauma patients. Hemorrhage due to blunt and penetrating trauma is a common cause of morbidity and mortality among acutely injured patients, and the FAST exam may help identify the area of hemorrhage. The rapid assessment and diagnosis of injuries in trauma patients is often challenging due to altered mental status and distracting injuries. The FAST exam has become an extension of the physical exam in trauma patients and helps clinicians determine whether a patient has intra-peritoneal bleeding or intra-thoracic bleeding to guide operative management of unstable patients.

Abdominal trauma

Diagnostic peritoneal lavage or aspiration (DPL or DPA), CT of the abdomen and ultrasonography are the three diagnostic techniques used in patients with abdominal trauma. DPL and DPA are sensitive but carry the risk of clinician-induced injury, are not specific and do not detect retroperitoneal injuries. CT is sensitive and specific but has limited availability in many parts of the developing world. CT is more time consuming, expensive and carries the risks of radiation and contrast nephropathy. Ultrasound is rapid, accurate, noninvasive, portable, repeatable and carries no risks. It is most helpful when a positive result shows free fluid in the chest or abdomen, and numerous studies have shown it is a readily learned skill. Free peritoneal fluid accumulates in dependent spaces including Morison's pouch, the splenorenal recess, the rectovesical pouch in males and the pouch of Douglas in females. The abdominal FAST exam is used to rapidly identify free fluid in these spaces. Approximately 300 mL of free fluid in the abdomen is required for free fluid to be reliably detected using this ultrasound technique. If the FAST exam is negative, additional measures should be taken

to further evaluate the patient, if the mechanism or clinical index of suspicion is high.

Clinical application

- Detection of free intraperitoneal fluid

Ultrasound findings

Right upper quadrant views

Use the intercostal oblique & coronal views to identify free fluid in the right chest, Morison's pouch and the paracolic gutter. Free fluid will appear as anechoic black or hypoechoic dark gray stripes on ultrasound.

Morison's pouch is the potential space between the liver and right kidney. It is also the most dependent supramesocolic area in a supine patient. The right paracolic gutter connects Morison's pouch with the pelvis and thus will drain free fluid to the pelvis. The right diaphragm, right lobe of the liver and right kidney should also be examined.

Left upper quadrant views

Use the intercostal oblique & coronal views to identify free fluid in the left chest, subphrenic space, left paracolic gutter and splenorenal recess. Free fluid will appear as anechoic black or hypoechoic dark gray stripes on ultrasound. The Splenorenal recess and the space between the diaphragm and spleen are the most dependent spaces in the left upper quadrant. The passage from the splenorenal recess to the pelvis is blocked by the phrenicocolic ligament. Thus, free fluid flows more freely on the right side. The left diaphragm, the spleen and the left kidney should be examined carefully.

Pelvic view

Use this view to identify fluid in the anterior pelvis or cul-de-sac. Free fluid will appear as anechoic stripes or hypoechoic stripes. The pouch of Douglas is the most dependent area in the peritoneum of females and the rectovesical pouch is the most dependent area in males.

Technique

For this ultrasound exam, use the curved or phased array probe (Figure 1). The ultrasonographer should develop a standardized order for performing the exam. The author recommends that the ultrasonographer stands on the right side of the patient and scans the right upper quadrant first, left upper quadrant second and the pelvis third. The patient can be positioned in Trendelenberg, or head-down position, if possible to increase the fluid flow to the dependent spaces of Morison's pouch and the splenorenal recess. This is not always successful as clotted blood does not flow well. The index marker should point toward the patient's right side in the transverse plane or the patient's head in a longitudinal or sagittal plane. For the views of Morison's pouch and the splenorenal recess, the probe may need to be rotated to view in between the ribs.



Figure 1. Curved probe used for the FAST exam

Step by step approach

Right upper quadrant view

1. Place the transducer in the mid-axillary line between the 8th and 11th ribs and point the index marker toward the patient's head or right posterior axilla, as shown in Figure 2.

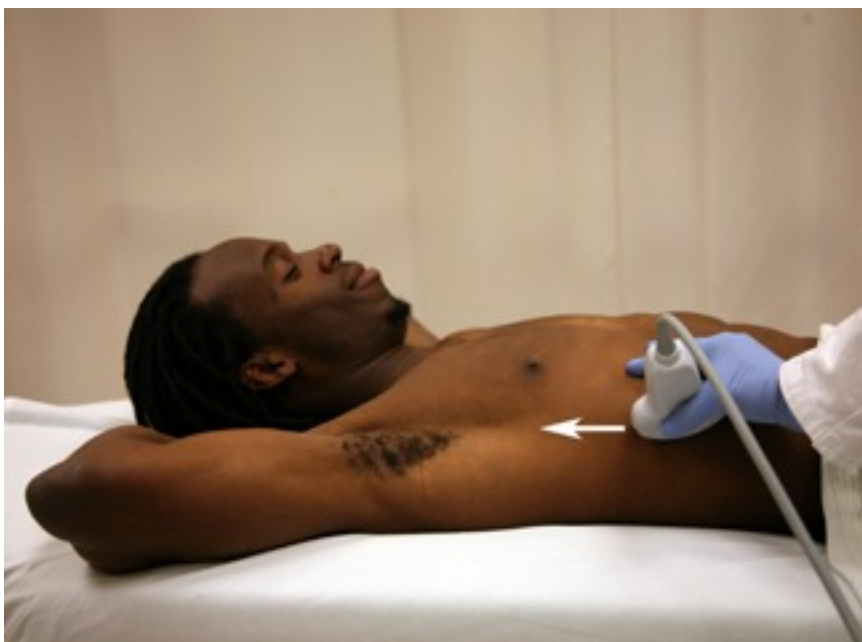

Figure 2. Probe position for Morison's pouch view with the index marker pointing toward the patient's head (arrow)

2. Adjust the probe position by rotating it and moving it up or down a rib space in order to get the liver, kidney and Morison's pouch into view, as shown in Figure 3.

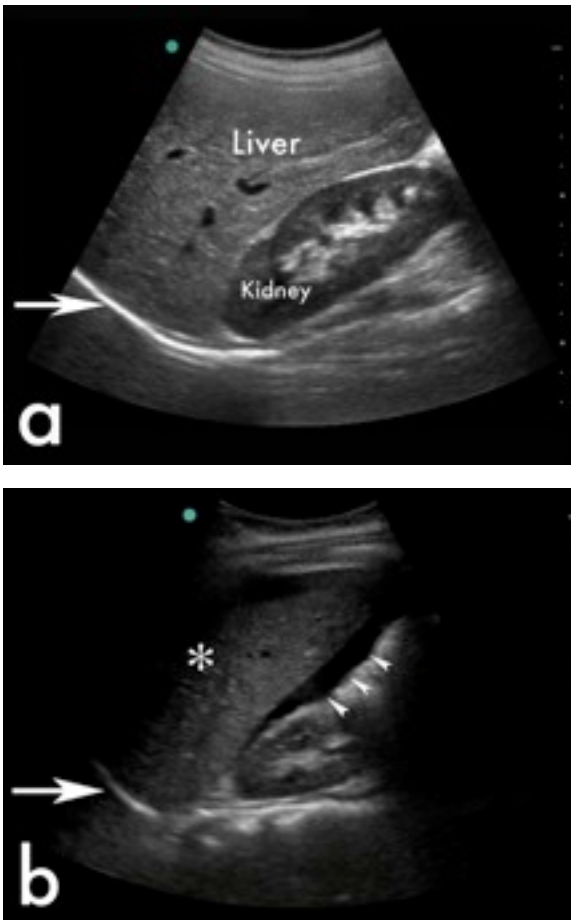


Figure 3. a: Morison's pouch view including the diaphragm (arrow), liver, and kidney. b: Note blood in Morison's pouch (arrowheads)

3. Adjust the transducer so it points slightly more toward the patient's head and look for free fluid cephalad to the diaphragm. The diaphragm is a hyperechoic structure, and pleural fluid will appear as an anechoic stripe above the diaphragm. An example

of fluid superior to the diaphragm is shown in Figure 4. For additional techniques to identify pleural effusions see the next section on Thoracic trauma.

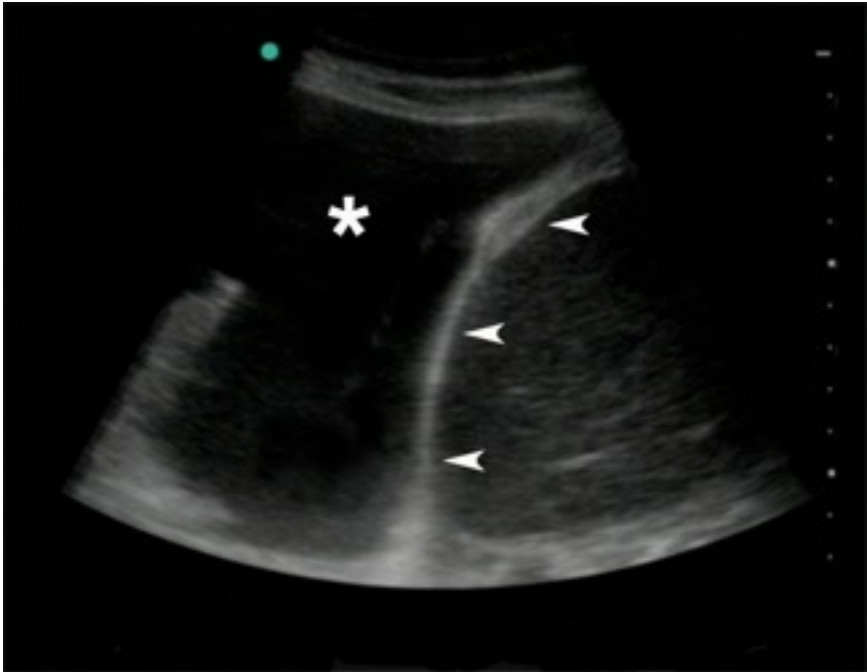


Figure 4. Pleural effusion above the diaphragm

4. Move the probe down below the 11th rib mid-axillary line and point the index marker to the right axilla. From this view you can identify fluid in the right paracolic gutter and right pararenal retroperitoneum. Retroperitoneal free fluid will appear as a hypoechoic stripe adjacent to the psoas muscle along the inferior pole of the kidney.

Left upper quadrant view

1. Place the abdominal transducer in the left posterior axillary line between the 8th and 11th ribs. The knuckles of your hand should touch the bed to assure proper positioning. The index marker should be pointing toward the patient's head or left posterior axilla as shown in Figure 5.

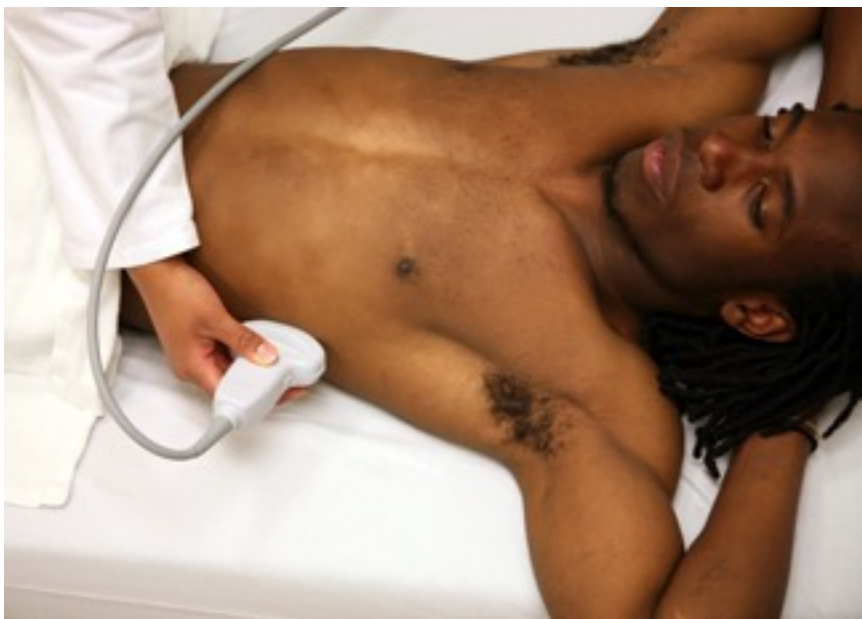

Figure 5. Probe position for the LUQ view

2. Adjust the probe position by rotating it and moving it up or down a rib space in order to get the kidney and spleen into view, as demonstrated in Figure 6. If you

see the kidney first, move the probe up a rib space to find the spleen. The left kidney is more difficult to identify because it sits higher in the abdomen, stomach and colon gas often obscure views, and the spleen is a smaller acoustic window. Asking the patient to take a deep breath may improve the view.

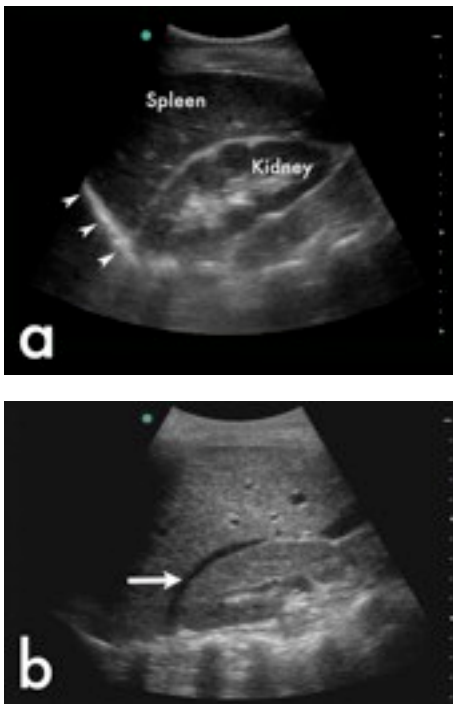


Figure 6. Normal LUQ view including the diaphragm (arrowheads), spleen and kidney

3. Adjust the transducer so it points slightly more toward the patient's head and look for free fluid

cephalad to the diaphragm. The diaphragm is a hyperechoic structure, and pleural fluid will appear as an anechoic stripe above the diaphragm as shown in Figure 4. For more techniques to identify pleural effusions see the next section on Thoracic trauma.

4. Move the probe down below the 11th rib mid to posterior-axillary line and point the index marker to the left axilla. From this view one can identify fluid inferior to the left kidney.

Pelvic views

1. These views are best done before a Foley catheter is inserted into the bladder. Place the abdominal probe 2 cm superior to the pubic symphysis in a longitudinal sagittal plane with the index marker pointing toward the patients head, as demonstrated in Figure 7.

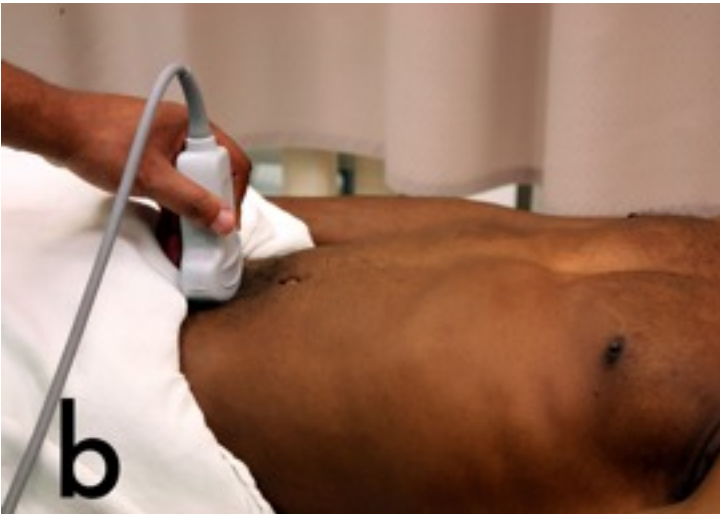
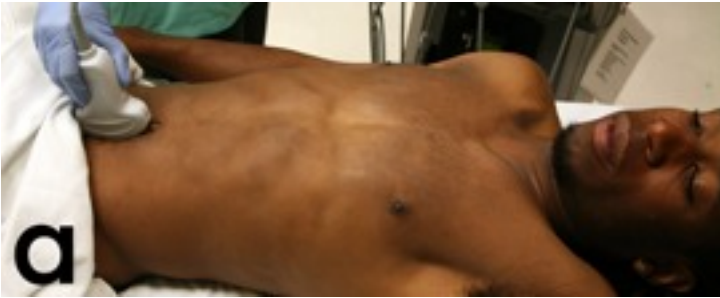
Figure 7. Probe position for longitudinal (a) and transverse (b) views of the pelvis

2. Scan longitudinally, inspecting the bladder and prostate or uterus. Look for free fluid. See Figure 8.
3. Rotate the probe 90 degrees so that the index marker is pointing to the patient's right.

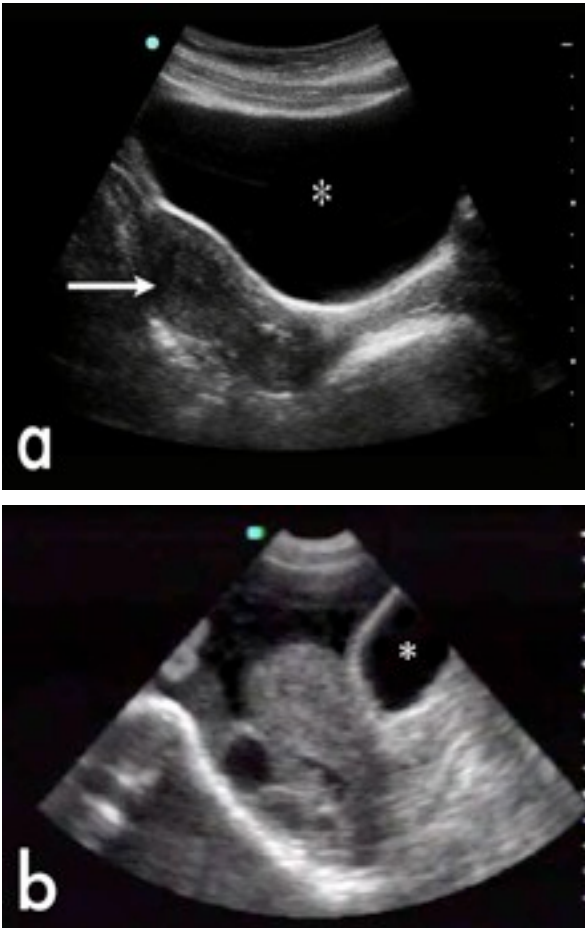


Figure 8. a. Normal pelvic view showing the uterus (arrow) and bladder (*). b. Blood in the pelvis of a trauma patient.

4. Scan through the bladder vertically inspecting bladder, prostate or uterus. Look for free fluid.

5. Lower the far gain to decrease the brightness of the image deep to the bladder. This will make it easier to see fluid collecting in that space.

Thoracic trauma: pleural & pericardial effusions

In patients who have sustained penetrating trauma to the torso, the cardiac portion of the FAST exam can rapidly guide the provider to life saving interventions. Physical exam findings of tamponade are present in less than 40% of patients with surgically proven cardiac tamponade. Ultrasound allows rapid diagnosis of this life threatening condition. Pericardial effusions are seen in both penetrating and blunt trauma in addition to medical conditions. Ultrasound allows for rapid diagnosis and intervention. It should be noted that a negative pericardial ultrasound does not rule out pericardial effusion in cases of concurrent lacerations of the pericardial sac. The thoracic cavity can be inspected for pericardial and pleural effusions during the FAST exam. Pleural effusions can be rapidly identified as noted in the section on abdominal trauma ultrasound. If the patient has stable vital signs and no evidence of spinal injury following the initial FAST exam, smaller

pleural effusions can be identified by having the patient sit up. Ultrasound can detect pleural effusions as small as 20 mL, which is much smaller than the 175 mL needed to be detected on supine chest x-ray.

Clinical Applications

- Detection of pericardial effusion
- Detection of pleural effusion

Ultrasound findings

The subxyphoid four-chamber view is used to examine for pericardial effusion. A pericardial effusion is found by looking for an anechoic stripe around the heart within the parietal and visceral layers of the pericardial sac. Pleural effusions are anechoic stripes found cephalad to the hyperechoic diaphragm.

Step by step approach

Pericardial Effusions

1. Place the abdominal abdominal probe in the subxyphoid area and angle it toward the patients left shoulder. The index marker will be pointing toward the right shoulder, as shown in Figure 9. From this position, one should be able to get a coronal four chamber view.

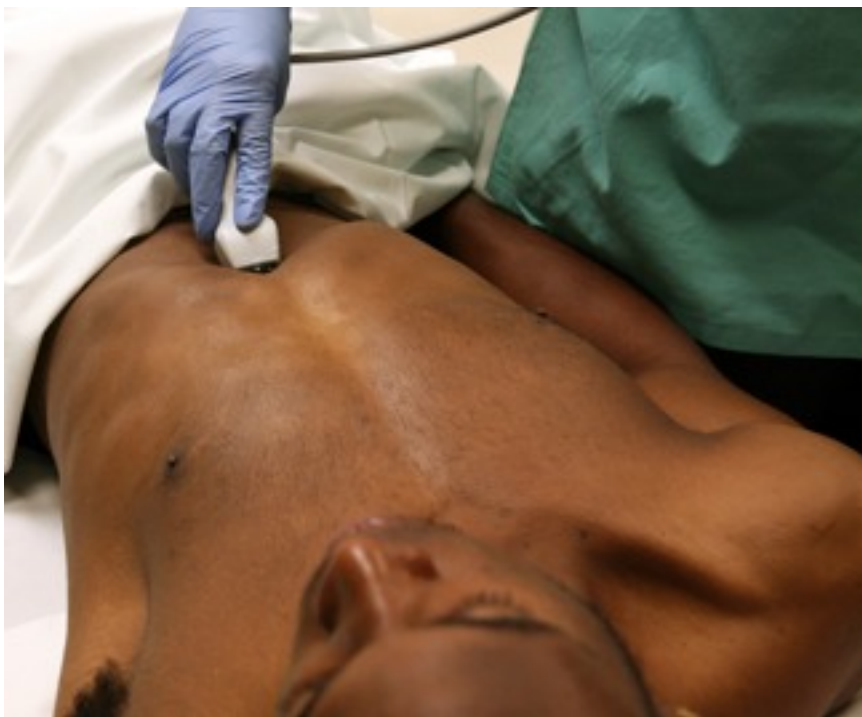

Figure 9. Probe position for the subxyphoid view

2. Scan the heart to identify an anechoic fluid stripe between the heart muscle, which appears grey on ultrasound, and the hyperechoic pericardium, as demonstrated in Figure 10.

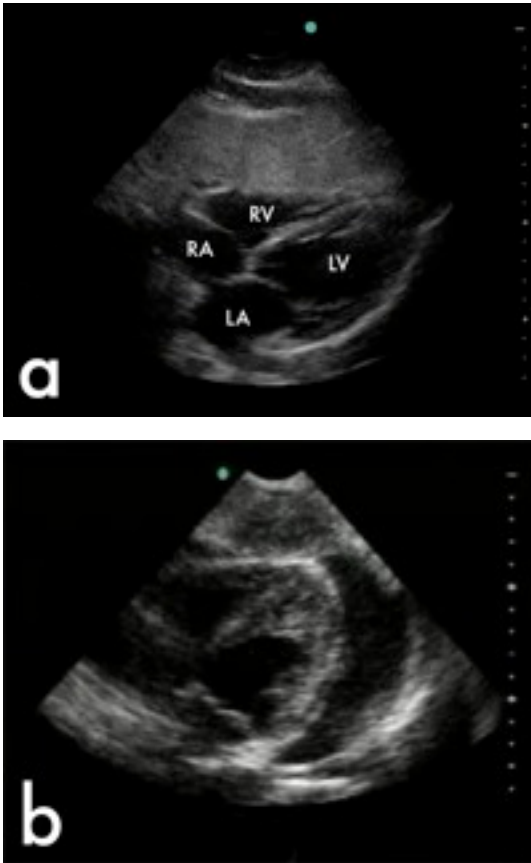


Figure 10. Normal subxyphoid view (a) and pericardial effusion (b)

3. If you are unable to view the heart with the subxyphoid view, you can use parasternal long,

parasternal short or Apical four chamber views to inspect for pericardial effusion, which will appear as an anechoic stripe surrounding the hyperechoic pericardium. See the Echocardiography chapter for more information.

Pleural Effusions

1. If you are unable to see an effusion with the abdominal FAST exam, and the patient's is stable with an uninjured spine, have the patient sit up in a thoracentesis position. Place the abdominal probe below the 11th rib space in the mid-axillary line between the patients ribs, as shown in Figure 11.

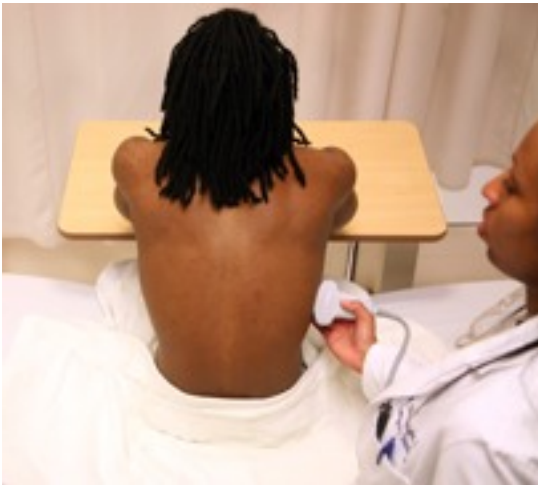

Figure 11. Probe position for identifying a pleural effusion with patient sitting upright

2. The probe will need to be rotated to fit in between the rib spaces.
3. Look for the hyperechoic diaphragm.
4. Look for hypoechoic fluid superior to the diaphragm.

Thoracic trauma: pneumothorax

Thoracic ultrasound can be used as part of the FAST exam to detect a pneumothorax before a chest x-ray can be completed and to identify small pneumothoraces not easily visible on supine chest x-rays. Ultrasound of the lung, when performed by trained individuals, is 92-100% sensitive for detection of all pneumothoraces. The pneumothorax exam evaluates the interface of the parietal and visceral pleura. These surfaces normally slide against one another, because there is normally a small amount of lubricating fluid between these layers. This motion, known as lung sliding, is visible on ultrasound. If air separates the layers of pleura, as in a pneumothorax, they will not slide, and ultrasound will demonstrate this absence of this motion. The ultrasound evaluation for pneumothorax can also be used after

thoracentesis or chest tube placement to quickly determine if a pneumothorax is present.

Clinical application

- Detection of pneumothorax

Ultrasound findings

Ants marching or lung sliding

Pleural sliding resembles ants marching along the pleural interface. While best seen in an ultrasound video, a still image of the pleural line is shown in Figure 12. In patients with pleural adhesions from previous pathology, such as obstructive lung disease from long-standing tobacco use or history of pleurisy, this finding may not be detected, even in the absence of a pneumothorax.

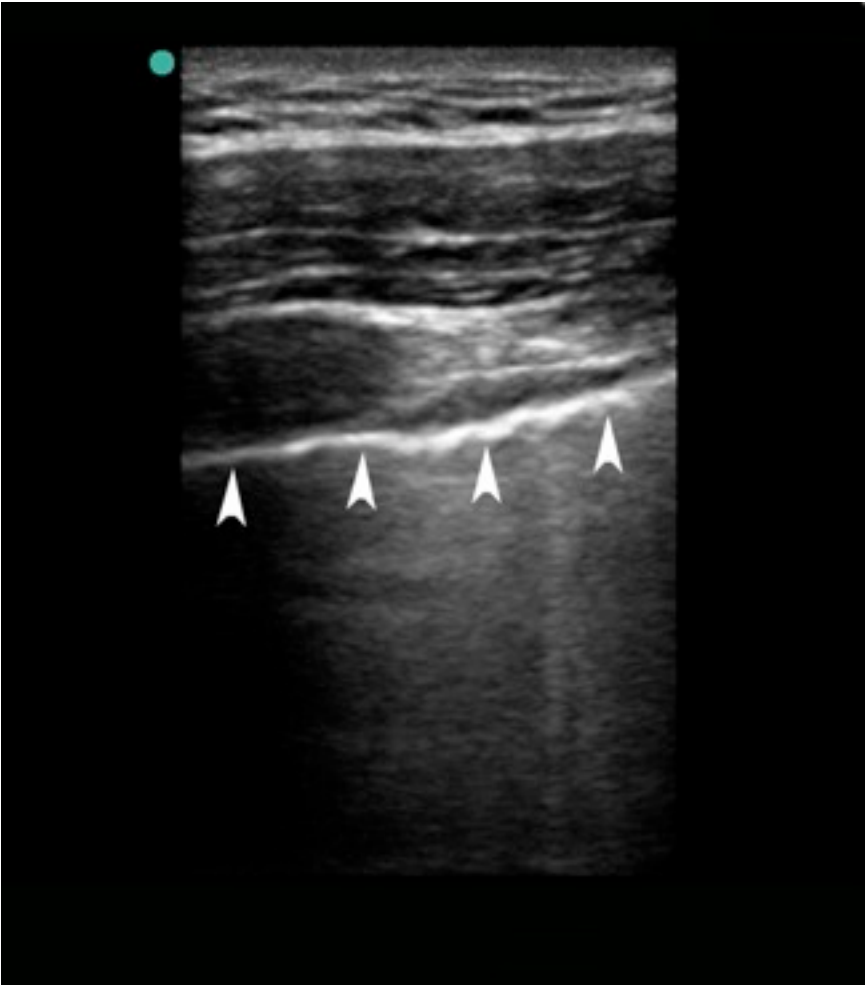


Figure 12. Hyperechoic pleural line (arrowheads)

Seashore sign

In M mode, the motion of the pleural sliding will produce a grainy pattern deep to the chest wall-lung interface. The grainy pattern resembles sand on a beach, and the pattern of the stationary chest wall resembles waves in a body of water, as shown in Figure 13.




Figure 13. M mode tracing of normal lung

Stratosphere Sign

In M mode, a pneumothorax will not produce a grainy pattern, as with the seashore sign, but a continued pattern of horizontal lines deep to the chest wall-lung interface, as shown in Figure 14.

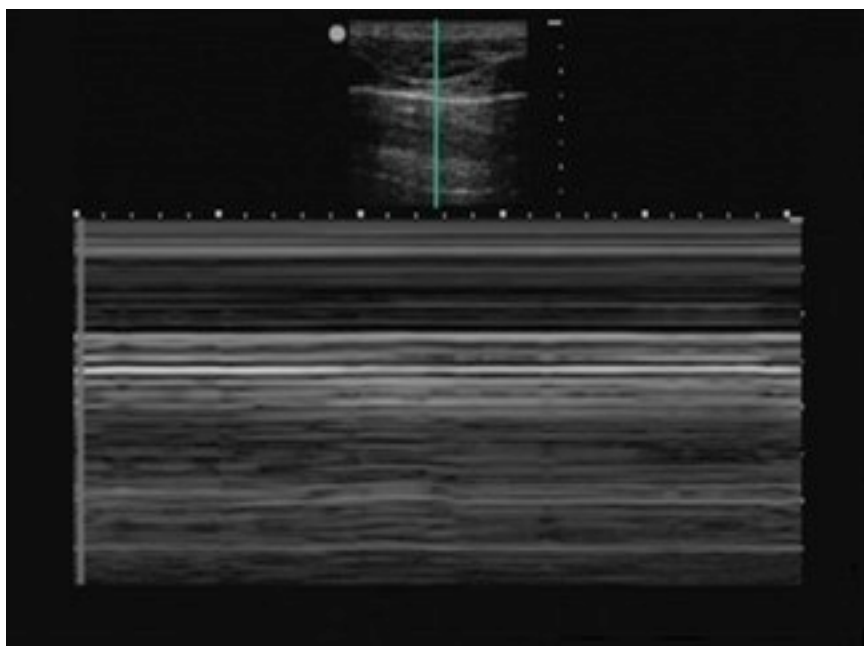


Figure 14. M mode tracing of a pneumothorax

Comet Tail Artifacts

Artifacts that normally arise from interlobar septae under the visceral pleura. Comet tails appear as hyperechoic lines beginning at the pleural line and

extending downward, as shown in Figure 15. The absence of comet tails may indicate the presence of a pneumothorax.

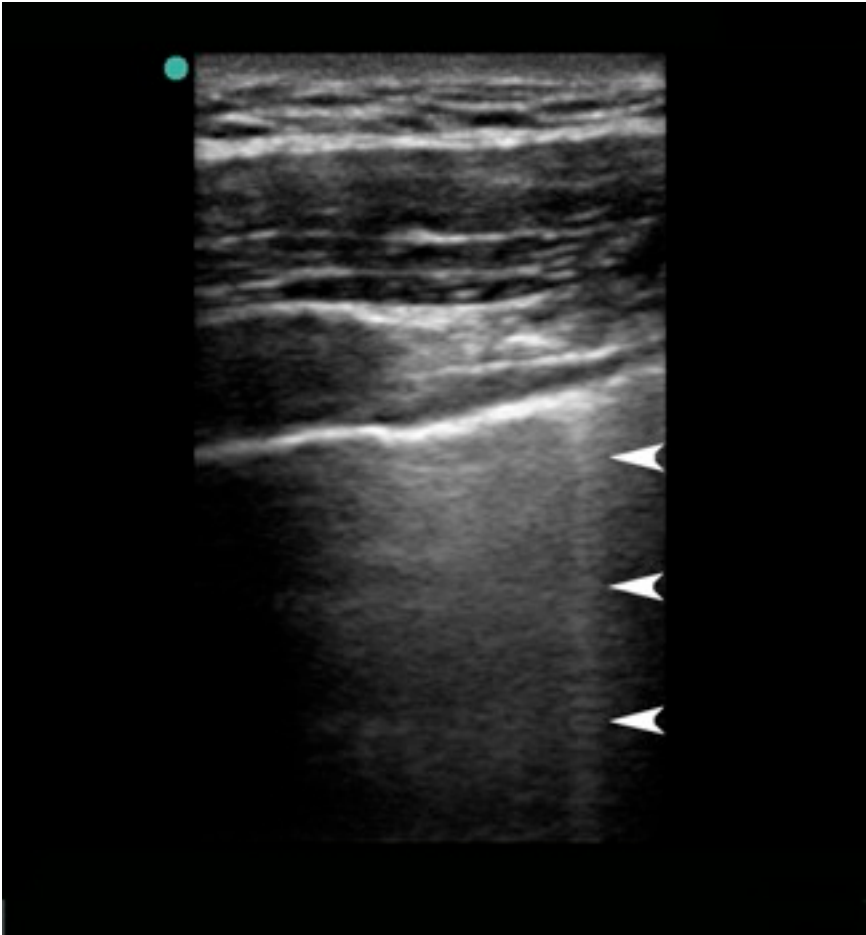


Figure 15. A comet tail artifact (arrowheads) seen in normal lung

Technique

Use the linear transducer or curved array probe (Figure 16). The linear transducer will provide better visualization of the pleural interface and pleural sliding, but the abdominal probe may be more convenient as it is used for the rest of the FAST exam.

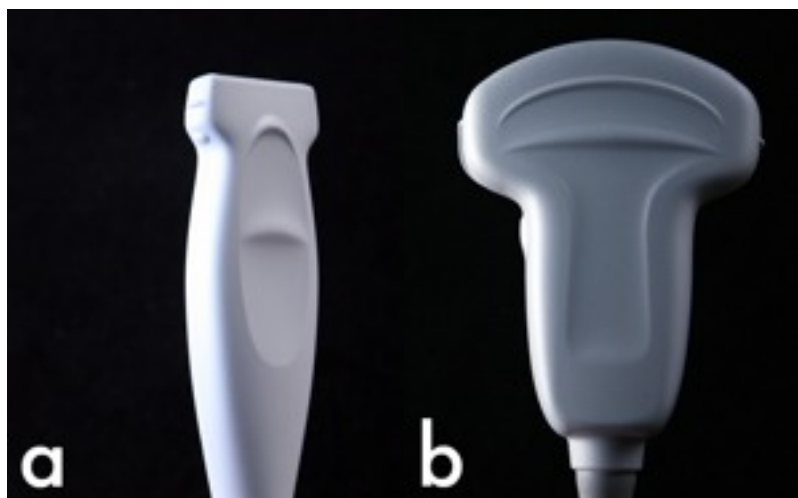

Figure 16. Linear (a) and curved array (b) transducers used for the pneumothorax exam

The probe should be placed longitudinally on the chest wall in the mid-clavicular line. The operator should look for pleural sliding and comet tails, as described above. If there is no pleural sliding noted, M mode should be

used to confirm diagnosis. The exam should be repeated in at least 4 intercostal spaces on each side.

Step by step approach

1. Place the linear transducer over the anterior chest, mid-clavicular in the first intercostal space in which you can identify the pleural line between two ribs, as shown in Figure 17.

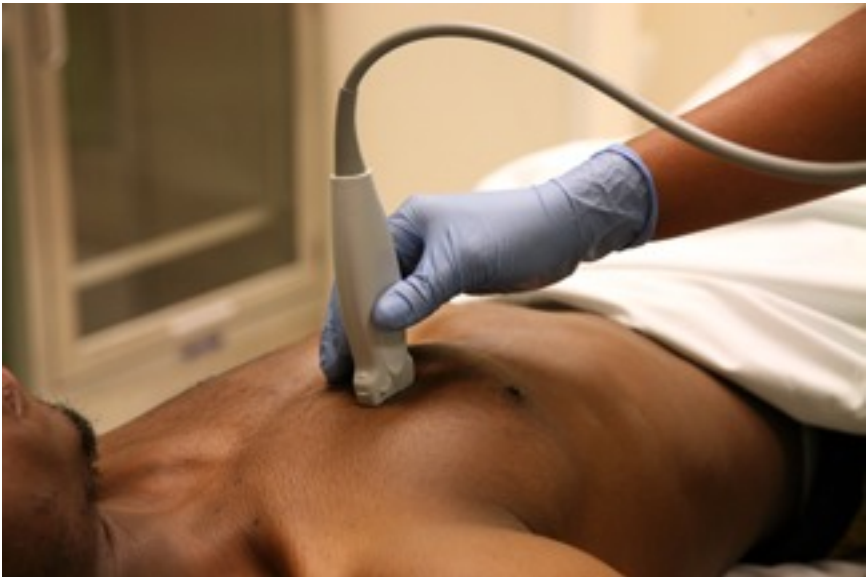

Figure 17. Probe position for pneumothorax exam

2. The index marker should point toward the patient's head in the sagittal plane.
3. Look for the pleural interface flanked by rib shadows. Center the image between two rib spaces, as shown in Figure 18.

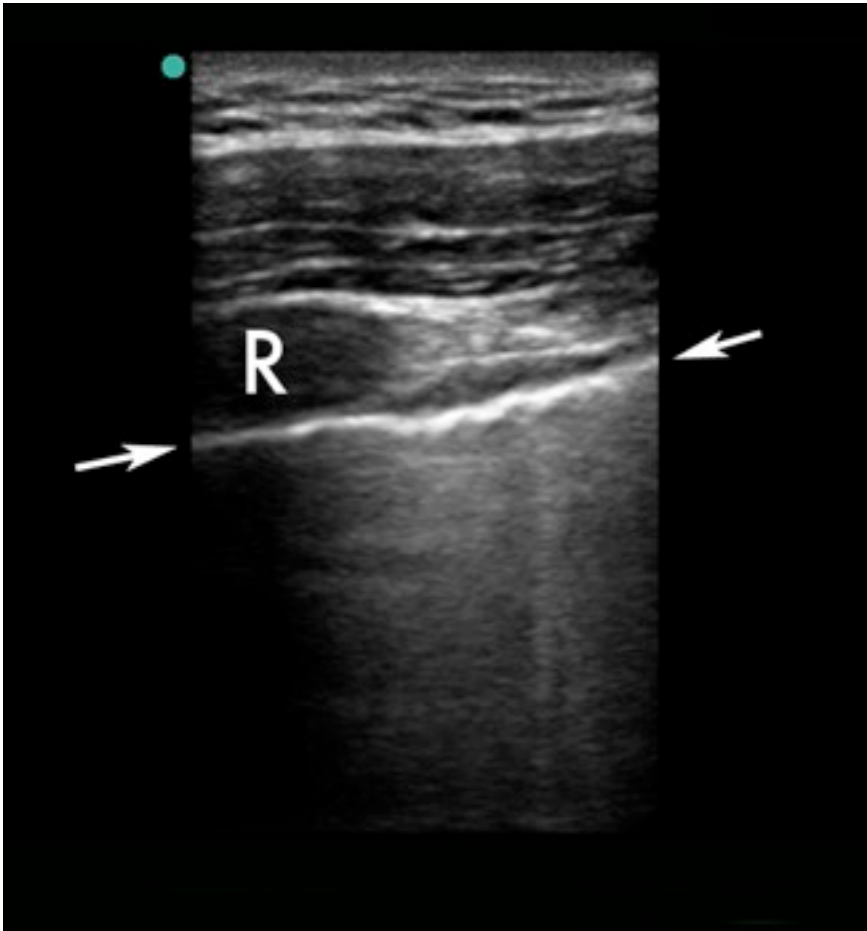

Figure 18. Normal pleural line (arrows) and a rib (R) with shadow

4. Look for pleural sliding with respirations. This will look like ants marching along the pleural interface.
5. Look for comet tail artifacts.
6. If it looks like there is no pleural sliding, or it is a difficult study, use M mode to look for the seashore or stratosphere sign.
7. Repeat steps 3-6 in three additional intercostal spaces on each side.
8. If a pneumothorax is present, place the patient on oxygen, consider chest radiography and placement of a chest tube.

Conclusions

Ultrasound is a useful and important tool for evaluating, diagnosing, and managing traumatic injuries. Ultrasound can be considered an extension of the physical exam and allows the practitioner to quickly identify free fluid in the abdominal and thoracic cavities, pericardial effusion and pneumothorax noninvasively and without radiation. The FAST exam does not adequately evaluate the retroperitoneum, cannot differentiate between

ascites and hemoperitoneum, and should be used to rule in rather than rule out hemoperitoneum. The FAST techniques described in this chapter can also be used to evaluate undifferentiated hypotension and other medical and surgical conditions in which it is important to rapidly identify free fluid in the abdominal or thoracic cavities, pneumothoraces or pericardial effusions not related to traumatic injuries.

Recommended reading

1. Mariani P.J, Wittick L. Pneumothorax diagnosis by extended focused assessment with sonography for trauma. *J Ultrasound Med* 2009;28:1601;author reply 1602.
2. Hsu JM, et al. The accuracy of focused assessment with sonography in trauma (FAST) in blunt trauma patients: experience of an Australian major trauma service. *Injury* 2007;38:71-5.
3. Brooks A, et al. Prospective evaluation of non-radiologist performed emergency abdominal ultrasound for haemoperitoneum. *Emerg Med J* 2004;21:e5.

4. Gaarder C, et al. Ultrasound performed by radiologists- confirming the truth about FAST in trauma. *J Trauma* 2009;67:323-7; discussion 328-9.
5. Friese RS, et al. Abdominal ultrasound is an unreliable modality for the detection of hemoperitoneum in patients with pelvic fracture. *J Trauma* 2007;63:97-102.
6. Kendall JL, et al. Emergency Department Ultrasound Is not a Sensitive Detector of Solid Organ Injury. *West J Emerg Med* 2009; 10:1-5.
7. Karrel R, Shaffer MA, Franaszek JB. Emergency diagnosis, resuscitation, and treatment of acute penetrating cardiac trauma. *Ann Emerg Med* 1982;11:504-17.
8. Ball CG, et al. A caveat to the performance of pericardial ultrasound in patients with penetrating cardiac wounds. *J Trauma* 2009;67:1123-4.
9. Rothlin MA, et al. Ultrasound in blunt abdominal and thoracic trauma. *J Trauma* 1993;34:488-95.
10. Ball CG, Kirkpatrick AW, Feliciano DV. The occult pneumothorax: what have we learned? *Can J Surg* 2009; 52:E173-9.
11. Lichtenstein DA, et al. Ultrasound diagnosis of occult pneumothorax. *Crit Care Med* 2005;33:1231-8.

12. Cunningham J, et al. Enhanced recognition of "lung sliding" with power color Doppler imaging in the diagnosis of pneumothorax. *J Trauma* 2002;52:769-71.

Echocardiography

SACHIN SHAH MD

GENE BUKHMAN MD, PHD

Introduction

Echocardiography or cardiac ultrasound has been used extensively in cardiology for the past 30 years. This imaging technique has revolutionized cardiology as a specialty and has aided in diagnosis and disease management. This chapter focuses on the indications for performing an echocardiogram as well as basic interpretation skills. This is meant to help generalist health care practitioners use echocardiography to diagnose the most commonly encountered abnormalities and to gauge severity. Treatment and triage decisions, such as referral to a cardiologist or initiation of medications, can be based on the findings of the basic echocardiogram.

Indications

This tool is helpful as an adjunct to basic history and physical exam. Oftentimes a disease process can be suspected based on history or physical exam and echocardiography is used for confirmation. For example, a patient may present with clinical symptoms of heart failure, such as dyspnea on exertion, lower extremity swelling and orthopnea (difficulty breathing while lying flat). Clinically, the health care provider may suspect a diagnosis of heart failure. An echocardiogram will help to distinguish between the multiple possibilities including idiopathic cardiomyopathy with reduced systolic function, severe valvular disease related to rheumatic fever, or a ventricular septal defect that has been present since childbirth and never closed. The treatment for these possibilities would be very different for each of these diagnoses. The following is a list of indications for basic echocardiography. The list encompasses the most common indications but is not meant to be exhaustive.

- Shortness of breath and pulmonary edema
- Dyspnea on exertion

- Orthopnea
- Lower extremity edema
- Atrial fibrillation or palpitations
- Chest pain
- Stroke or other embolic phenomenon
- Sepsis or fever without a clear cause
- Murmurs
- Hypotension
- Quiet heart sounds

This chapter focuses on the needs of generalist physicians, clinical officers, and specialized nurse practitioners working in settings such as rural Haiti or Sub-Saharan Africa. Barriers to access to complete echocardiography by a cardiologist are an important feature of these settings.

Fortunately, basic echocardiography can help define the nature of a patient's problem sufficiently to guide their medical management, and identify patients that are unlikely to be good candidates for cardiac surgery. All patients with a possibility of surgically treatable valvular,

congenital, or pericardial disease should ultimately have a complete echocardiogram performed at a referral center.

The principle goal of basic echocardiography is to better place patients in one of 7 diagnostic categories with associated clinical pathways. Discussion of the management of these conditions is discussed further in the forthcoming *PIH Guide to Diagnosis and Treatment of Cardiovascular Disease, Diabetes, and Chronic Respiratory Disease in Resource-poor Settings*.

Diagnosis	Findings	Exam	Management
Cardiomyopathy	Severely depressed LV function	Non-specific	Medical
Mitral stenosis	Elbow deformity of anterior mitral valve, limited movement	Subtle	Medical & possibly surgical
Hypertension	Subtle	BP>180/110	Medical
Endocarditis	Dramatic mobile structures adherent to one or more valves	Loud murmur, fever	Medical & possibly surgical
Pericardial disease	Subtle in constrictive pericarditis, unlikely if IVC normal size	Ascites, dilated neck veins	Medical & possibly surgical
Congenital or other valvular	Can be subtle	Cyanosis, or loud murmur	Medical & possibly surgical
Non-cardiac	No findings	No cardiac findings	Medical & possibly surgical

The goals of this chapter are to familiarize you with common and important abnormalities that can be detected on echocardiography.

- Cardiomyopathy (reduced systolic function)
- Severe right ventricular dilatation
- Pericardial effusion
- Mitral stenosis
- Dramatic endocarditis
- Dilatation of the inferior vena cava

Basic echocardiographers should systematically assess for the presence or absence of each of these abnormalities, and place patients in a diagnostic category based on their imaging findings in combination with physical examination and history.

Technique

Notice that the indicator marker is on the right side of the screen. During non-cardiac ultrasound the indicator is on the left side of the screen, but this is reversed during cardiac ultrasound.

The ultrasound probe can be held in either hand while the other hand is operating the ultrasound machine. Try using each hand and see which feels more comfortable. Sit on the left side of the patient, if you are using your

left hand. Sit on the right side of the patient if you are using your right hand. The ultrasound machine should be on the side of the patient that you are on, so you can easily operate the controls. The ultrasound machine should be placed on a stable flat surface. Most people find the most comfortable technique is to hold the probe in the underhand fashion with the thumb on one side and forefinger and middle finger on the other side.

While performing an echocardiogram, you may need to move the probe around on the patient's chest until you find a good image. The position of each patient's heart is slightly different. If you are having difficulty obtaining an image despite moving the probe to slightly different locations on the patient's chest, you may have to position the patient differently. Each view is discussed in more detail below.

There are certain controls that are helpful in optimizing image quality, such as depth and gain. For further discussion of how to improve image quality, please see the Fundamentals chapter at the beginning of this book. The depth buttons will help make your image the correct size for the screen. There are three controls that will help adjust the gain. If you notice that your image is too dark, you may need to increase the overall gain. If

the image is too bright, you may need to decrease the overall gain. If you notice the area close to the top of the display screen is too dark, but the lower part of the screen looks good, you need to adjust the near gain. Near gain adjusts the gain on the part of the image closest to the ultrasound probe — the area near the top half of the screen. If you need to adjust the gain in the area of the lower half of the screen (structures farthest from the ultrasound probe), use the far gain.

It is important to know that when color Doppler is in use (see below), the gain controls change the degree of color gain. The color gain should be adjusted initially by looking at the part of the color sector closest to the transducer. The gain should first be increased, then decreased until random color pixels are no longer visible. After this, the color gain should not be adjusted. The color Doppler pattern is better visualized when the 2-dimensional image gain is minimized beforehand.

Cardiac views & Common Pathology

This chapter will focus on four main views. The first two views are performed from the same location — the parasternal long axis and parasternal short axis views.

Next is the apical four chamber view, and finally, the subxyphoid or subcostal view.

Parasternal long axis

Conventionally, for adult patients, the parasternal long axis view is performed first in the exam. This view is extremely useful. The patient should be placed on their left side. The probe is placed to the left of the patient's sternum, in the area of the 3rd to 5th rib space, as shown in Figure 1.

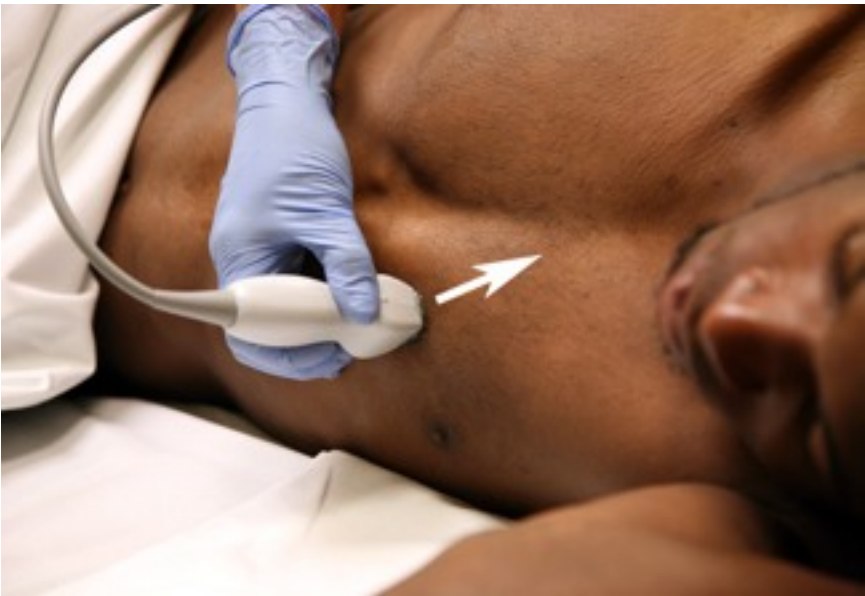
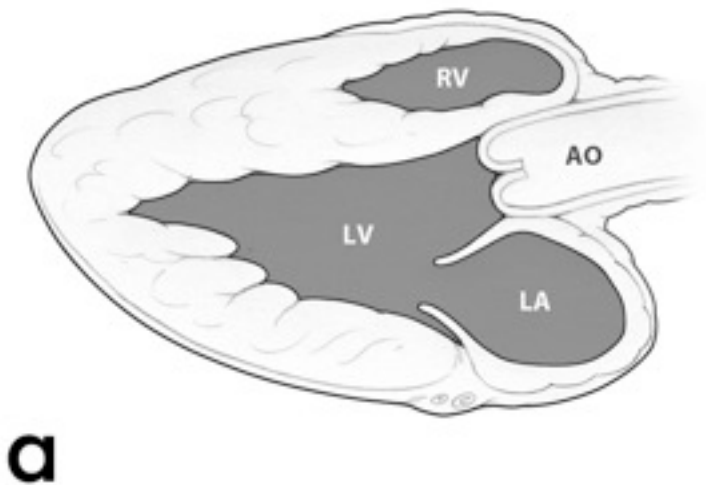


Figure 1. Probe position for parasternal long axis view. The arrow points to the right shoulder

The probe marker should be pointed toward the patient’s right shoulder. The exact location of the probe is not as important as finding an image that has a similar orientation to Figure 2. In this view, the operator is able to image the left atrium, left ventricle, aorta and right ventricular outflow tract (RVOT), a portion of the right ventricle.



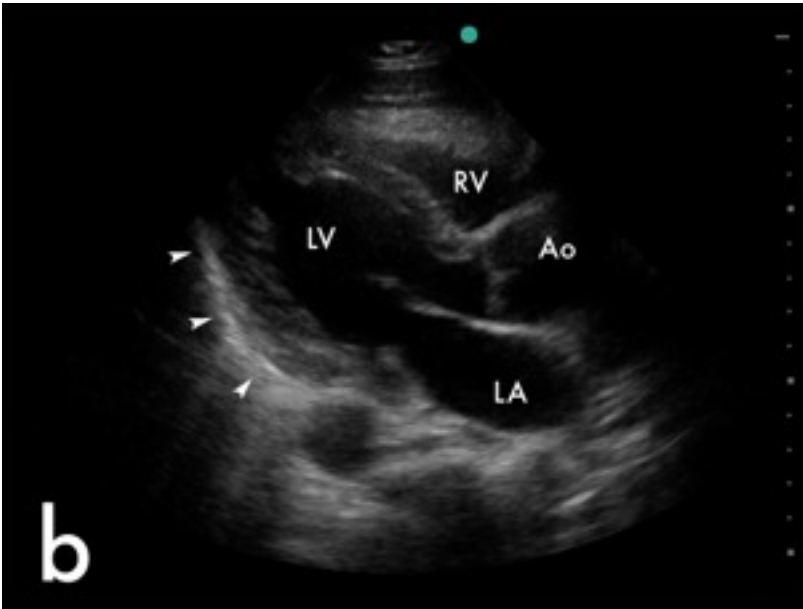


Figure 2. An illustration (a) and an ultrasound image (b) of the parasternal long axis view showing the left atrium (LA), left ventricle (LV), aorta (Ao), and pericardium (arrowheads)

The structure closest to the probe, and therefore closest to the top of the screen, is the right ventricle. This makes sense, as the closest cardiac structure to the patient's sternum is the right ventricle. The furthest structure (seen at the bottom of the display screen) is the left atrium.

Make sure that the walls of the left ventricle are close to parallel. The apex of the left ventricle usually is not included in the image. This allows more attention and

focus to be paid to the mitral and aortic valves. One should be able to see the aortic and mitral valves well, but the tricuspid valve should not be visualized.

In a normal heart, the right ventricle, aortic root, and left atrium appear to be roughly the same size in this view. If one of these structures, such as the right ventricle, appears much larger than the others, it suggests significant dilatation.

Turning the probe clockwise and counter-clockwise will cause the ventricle to become more round (foreshortened). If you notice that the left ventricular walls are not parallel, you may have turned the probe too much in the clockwise or counter clockwise direction.

If you notice that the apex is included in the image, as in Figure 3, then you must move the probe away from the apex of the heart.

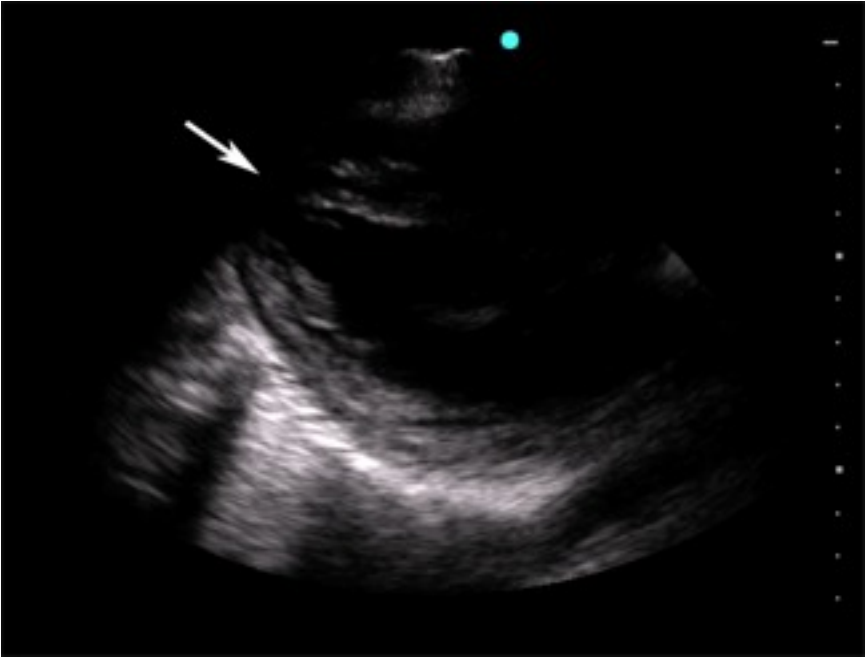

Figure 3. Parasternal long axis view showing the apex (arrow)

There are a few ways to do this. First, the probe can be moved closer to the patient's sternum. If the probe is already close to the patient's sternum and the apex is still visible, then try moving the probe one rib space toward the patient's head. If this is ineffective, try placing the patient further onto their left side. This will help move the heart away from the patient's sternum.

If the tricuspid valve is seen in the image, as shown in Figure 4, a valve will become visible in the right ventricle and will be seen superior to the aortic valve on

the screen. The probe should be tilted up towards the patient's head slightly.

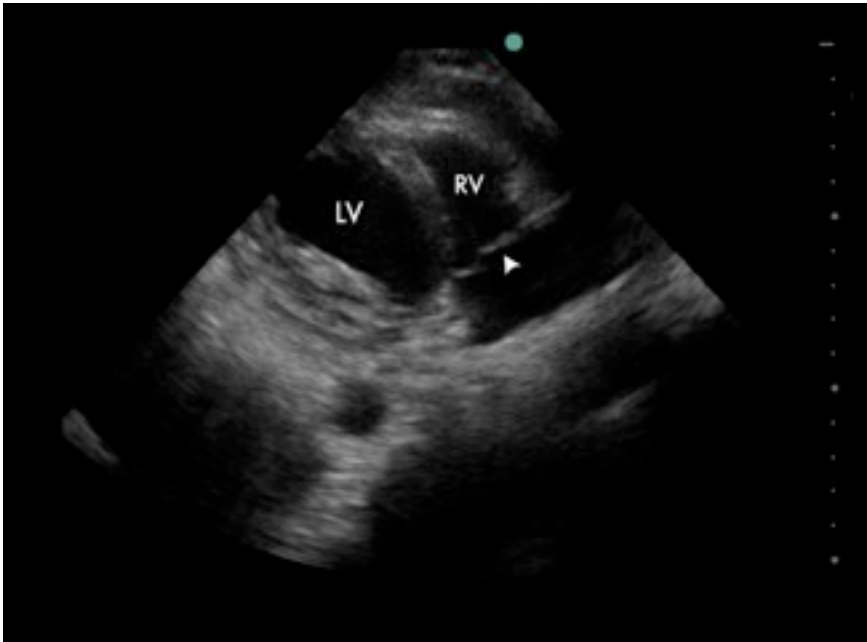


Figure 4. Modified parasternal long axis view showing the tricuspid valve (arrow)

Try to not move the probe around on the patient's skin and just tilt the probe slightly upwards, and this should remove the tricuspid valve from the image.

The parasternal long axis view is very useful for evaluating for pericardial effusion. A pericardial effusion will appear as an echo-lucent (black) area surrounding the heart, as demonstrated in Figure 5.

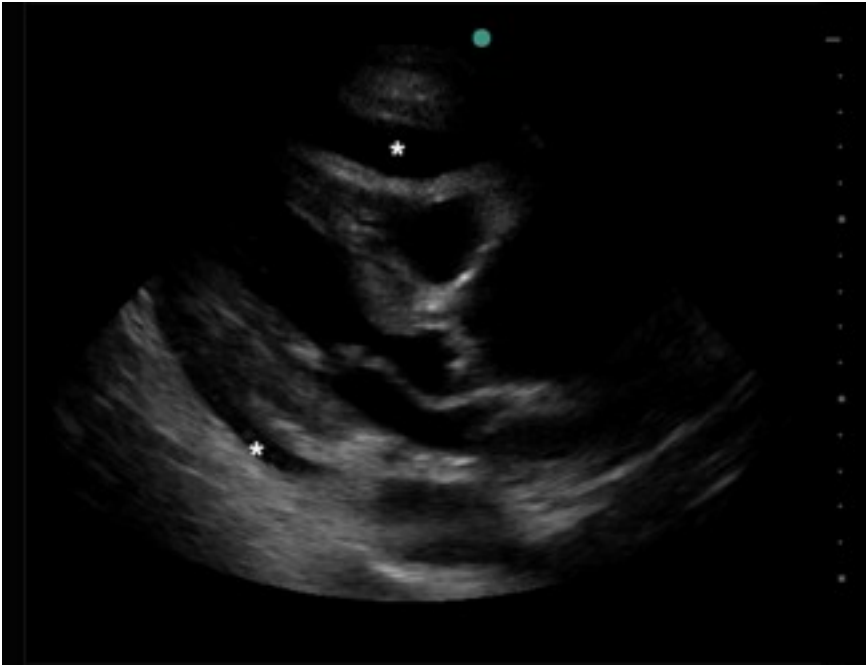

Figure 5. Parasternal long axis view showing a pericardial effusion (*)

The effusion will be seen between the heart and the pericardium — a thin bright white line on echocardiography. Please see the corresponding narrated lecture for video of pericardial effusion. Pericardial effusions can be of different sizes. They can be loculated (around a portion of the heart) or circumferential (around the entire heart). Sometimes they are completely echo-lucent (black), and sometimes gray-colored stranding may be visualized, as seen in the pericardial effusion from tuberculosis in Figure 6.

Small pericardial effusions (less than one centimeter at the smallest during the cardiac cycle) are commonly seen incidentally in the setting of heart failure due to other causes, such as valvular heart disease or cardiomyopathies. Large pericardial effusions in the absence of other obvious cardiac abnormalities on echocardiography or auscultation should raise concern for possible tuberculosis (see forthcoming *PIH Guide to Diagnosis and Treatment of Cardiovascular Disease, Diabetes, and Chronic Respiratory Disease in Resource-poor Settings*).

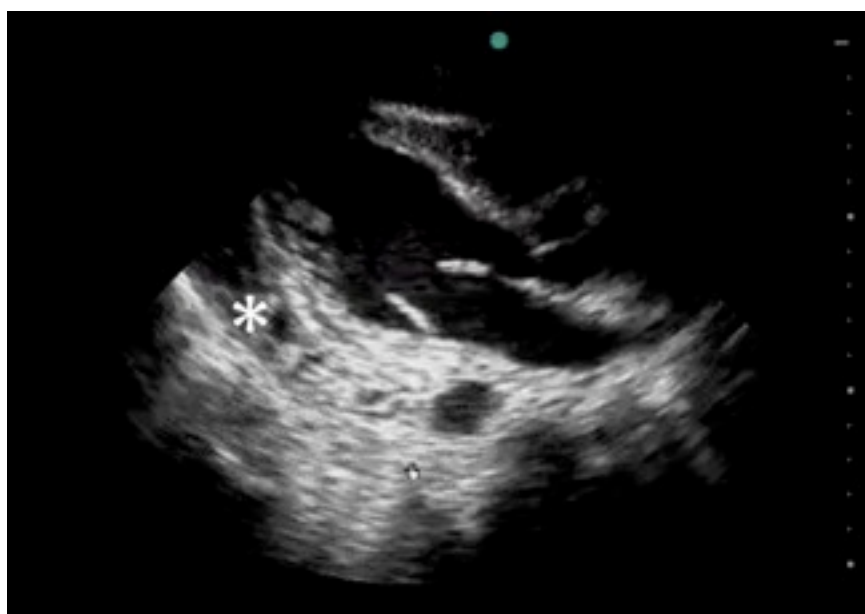


Figure 6. Pericardial effusion from TB appears more hyperechoic and sometimes heterogeneous because of proteins in the fluid

General systolic function can be assessed from this view. However, this is better assessed from the parasternal short axis view. Normal ejection fraction is greater than 55%. This means that greater than 55% of the blood is ejected from the heart during each beat. Because most of the blood is ejected from the heart at the beginning of contraction, the walls of the left ventricle only need to move in and out by about 30% with each heartbeat. This is most often estimated by the operator. It is most important for the generalist practitioner to distinguish between normal and abnormal function.

From the parasternal long axis view, the mitral valve is easily visualized. The mitral valve is made of two leaflets, and both leaflets can be visualized from this view. The leaflet closer to the probe (and therefore closer to the top of the screen and closer to the aortic valve) is the anterior leaflet. The leaflet farther from the probe (at the bottom of the display screen) is the posterior leaflet. Normally, these leaflets are thin and open and close well. If there is mitral stenosis, a few features may be visualized. The valve may be thickened and calcified (which appears bright white, as shown in Figure 7), and the valve does not open well. Typically, the tips of the leaflets move much less than the base of

the leaflet, resulting in a so-called “elbow deformity” of the anterior leaflet.

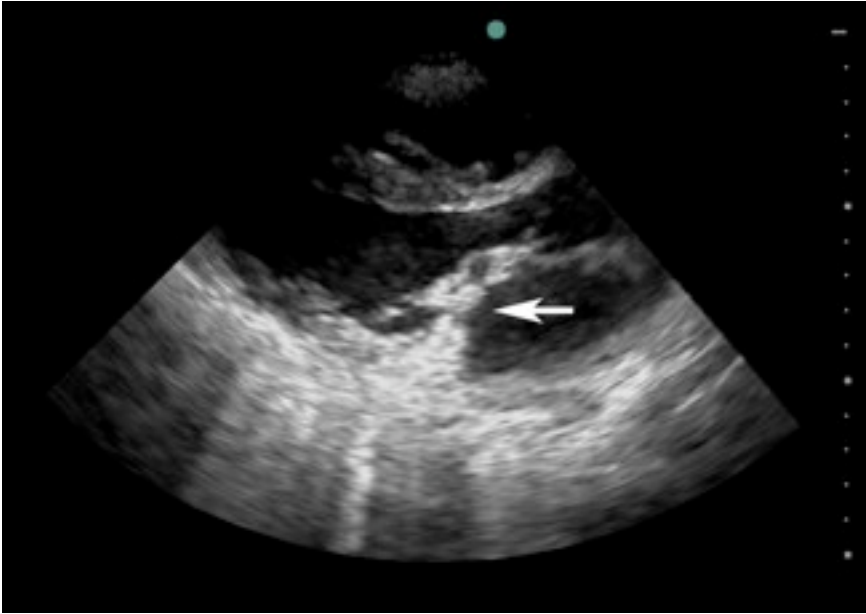


Figure 7. The mitral valve becomes thickened and hyperechoic in rheumatic heart disease (arrow)

The valve may even be “fixed”, meaning completely immobile on echocardiography. It is important to have a very sharp parasternal long axis image when assessing the mitral valve. A poorly visualized valve may mistakenly appear stenotic. Mitral stenosis is almost always a result of rheumatic heart disease.

Rheumatic heart disease can also cause mitral regurgitation, and patients with mitral stenosis may have mitral regurgitation as well. Normally, the mitral valve allows blood to flow from the left atrium into the left ventricle, but it prevents blood from flowing backwards from the left ventricle to the left atrium. Mitral regurgitation can be visualized on echo by using color Doppler. Press the “Color” button and place the color box over the mitral valve and the entire left atrium. Remember the issues with color gain mentioned above.

Resize the color box by hitting the “Select” button and using the touch pad to resize the box. Hit the “Select” button again to allow movement of the box around the screen. The color on echo will either be red or blue. The red color means blood is flowing towards the ultrasound probe. The blue color means blood is flowing away from the ultrasound probe. In the parasternal long axis view mitral regurgitation will most often appear as blood flowing away from the probe (blue) during systole, when no blood should normally be flowing across the mitral valve. See Figure 8 for an example of mitral regurgitation.

The degree of mitral regurgitation can be difficult for relatively inexperienced practitioners to assess

accurately. Fortunately, patients with moderate-to-severe mitral regurgitation generally have dramatic murmurs on physical examination.

We recommend that basic echocardiographers focus on the presence or absence of severe mitral stenosis, which requires a specific management strategy. Physical examination is the best guide the presence or absence of other valvular or congenital heart disease.

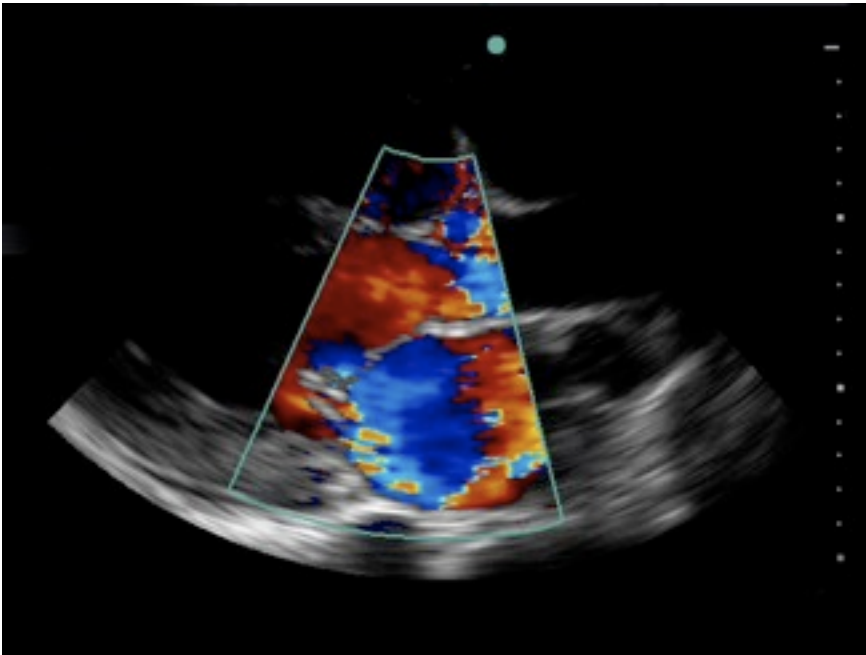


Figure 8. Mitral regurgitation show by blue color flow back into the left atrium during systole

Mitral regurgitation can be due to a number of causes, including rheumatic heart disease, endocarditis, and cardiomyopathies (due to stretching of the mitral valve annulus).

Basic echocardiography is useful for excluding cardiomyopathy in the case of a patient with loud cardiac murmurs.

Mitral regurgitation due to rheumatic heart disease is often due to scarring and tethering of the posterior leaflet and, as a result, prolapse of the anterior leaflet. In this case, the jet of mitral regurgitation is directed toward to posterior wall of the left atrium (an eccentric jet), and can be difficult to assess severity.

Parasternal short axis view

The parasternal short axis view uses the same area on the patient's chest as the parasternal long axis view. The probe is turned clockwise 90 degrees so the probe marker is pointing near the patient's left shoulder, as shown in Figure 9.

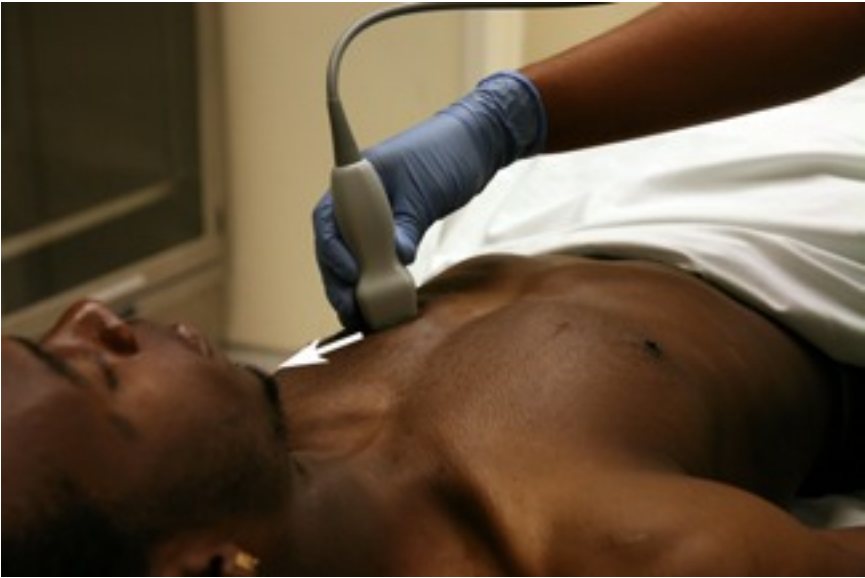

Figure 9. Probe position for parasternal short axis view. The probe marker (arrow) points toward the left shoulder

The left ventricle should look round like a circle, and the right ventricle usually looks like a “C” attached to the side of the left ventricle. See Figure 10 for an example of the ultrasound image from parasternal short axis position.

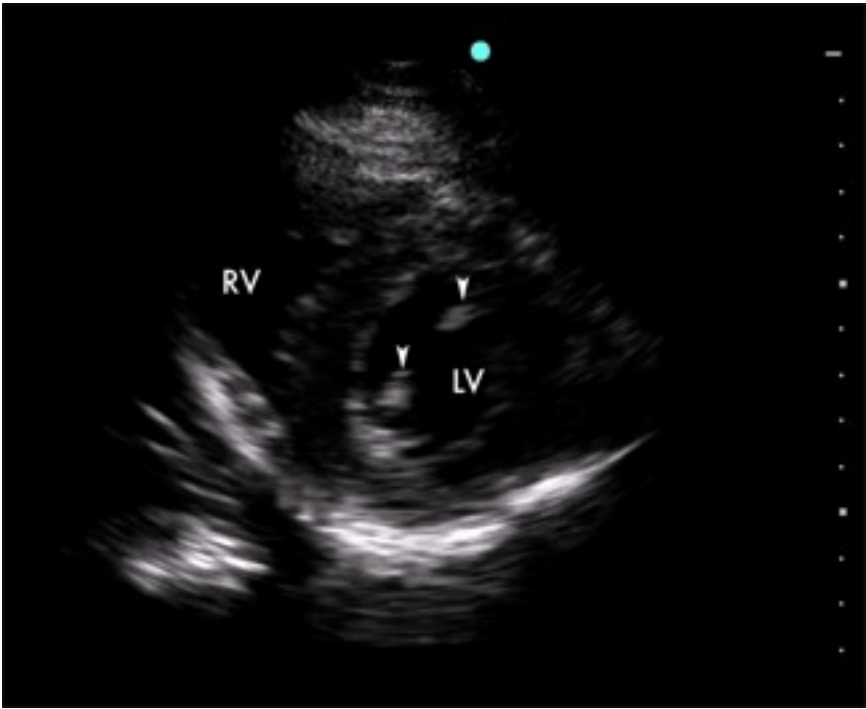


Figure 10. Parasternal short axis view showing the right ventricle (RV), left ventricle (LV) and papillary muscles (arrowheads)

If the ventricle is not round, try turning clockwise and counter-clockwise until the most round image can be obtained. The left ventricle is being evaluated in cross-section. Like cutting a loaf of bread, you can image from the base of the heart at the level of the mitral valve down to the apex of the heart. You can move the probe towards the apex of the heart or tilt the probe towards the apex of the heart to get images of the apex. Move away from the apex of the heart or tilt the probe away

from the apex of the heart, if you want to image the heart closer to the level of the mitral valve.

The parasternal short axis view is most useful for evaluating the systolic function of the heart measured as ejection fraction (EF).

Again, the ejection fraction is evaluated by the operator and is usually just estimated. Estimating the ejection fraction comes with practice, but after reviewing a few echocardiograms and performing a few echocardiograms, the operator should be able to identify patients with a normal EF and patients with a low EF.

Apical four chamber view

The apical four chamber view is the easiest to understand, as all four chambers of the heart are easily visualized. This view is also obtained while the patient is on his or her left side. The probe is placed at the apex of the heart as shown in Figure 11. The probe should be placed in the area of the anterior axillary line at about the 5th rib space. The probe marker should point toward the ground (3 o'clock in reference to the patient's side).

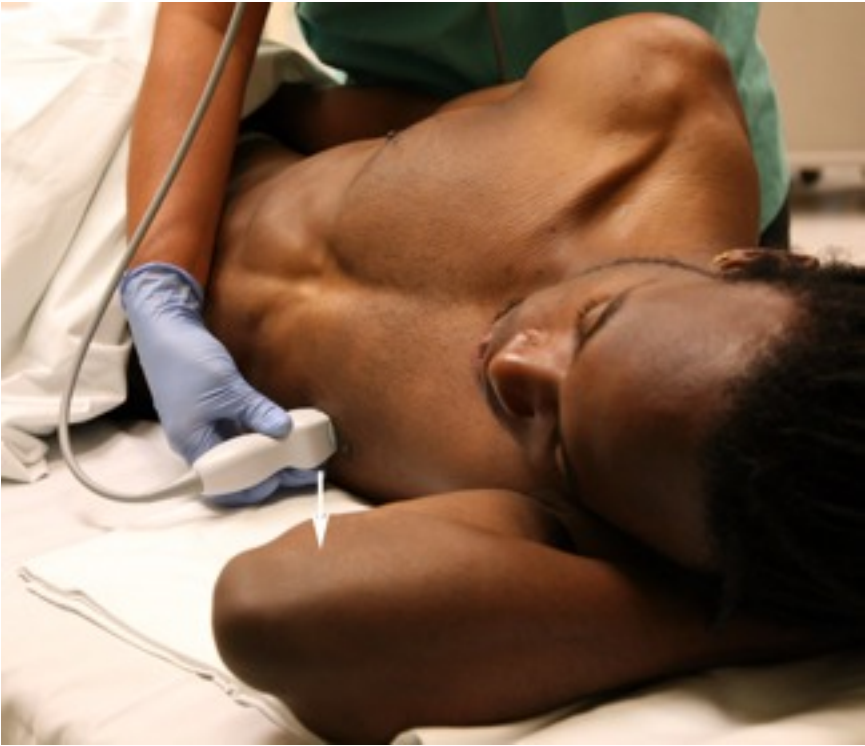

Figure 11. Probe position for apical four chamber view. The probe marker points toward the patient's left

Since patient's hearts are all slightly different, a better way to locate the spot for the probe is to find the patient's point of maximal impulse (PMI). The PMI is the point on the patient's chest where the heart beat can be felt the strongest. Use your hand to identify this spot, then place the probe over this area.

In this view, the left ventricle is located on the right side of the screen, and the right ventricle is on the left side of the screen, as seen in Figure 12.

Often, moving the probe more laterally and downward results in a more complete view of the heart. Remember to adjust the depth settings. Slightly rotating the transducer clockwise or counterclockwise can help clarify the opening of the mitral and tricuspid valves. Tilting the transducer either medially or laterally can help center the image on the screen.

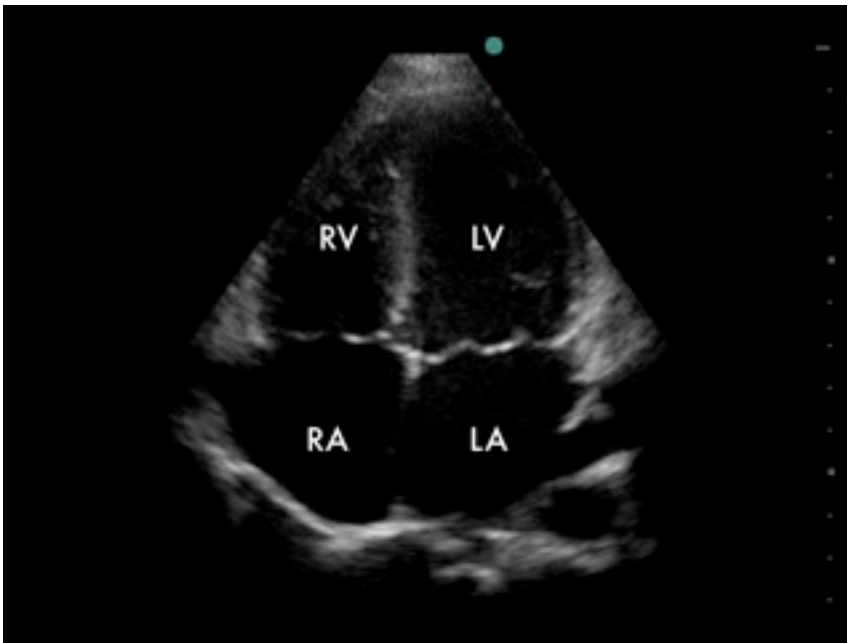


Figure 12. Apical four view showing the right (RV) and left (LV) ventricles, and the right (RA) and left (LA) atria

In a normal heart the left ventricle is at least twice the size of the right ventricle. In the case of severe right ventricular dilatation, the left ventricle will often appear small and compressed. Milder forms of right ventricular dilatation can be difficult to assess accurately in this view.

This view is not very useful for identifying pericardial effusion, although a pericardial effusion can be seen in this view. This view is not often used to estimate ejection fraction, because the walls of the left ventricle are parallel to the ultrasound beams making the walls more difficult to see.

The mitral valve is easily seen in this view. First, find the left ventricle, which is the chamber on the right side of the screen and closest to the probe. The left atrium is farther from the probe and appears closer to the bottom of the screen. The mitral valve is located between the left atrium and left ventricle. The valve can be assessed for thickness, calcification, and the ease with which it opens and closes. If the valve is very thick, calcified or does not open well, the patient might have mitral stenosis.

Color Doppler can also be used to evaluate the mitral valve. Press the Color button and place the box over the mitral valve and the entire left atrium. Blood going toward the probe (towards the top of the screen) will appear red, and blood going away from the probe will appear blue. In Figure 13, mitral regurgitation appears as a blue area starting at the mitral valve and going into the left atrium during ventricular systole.

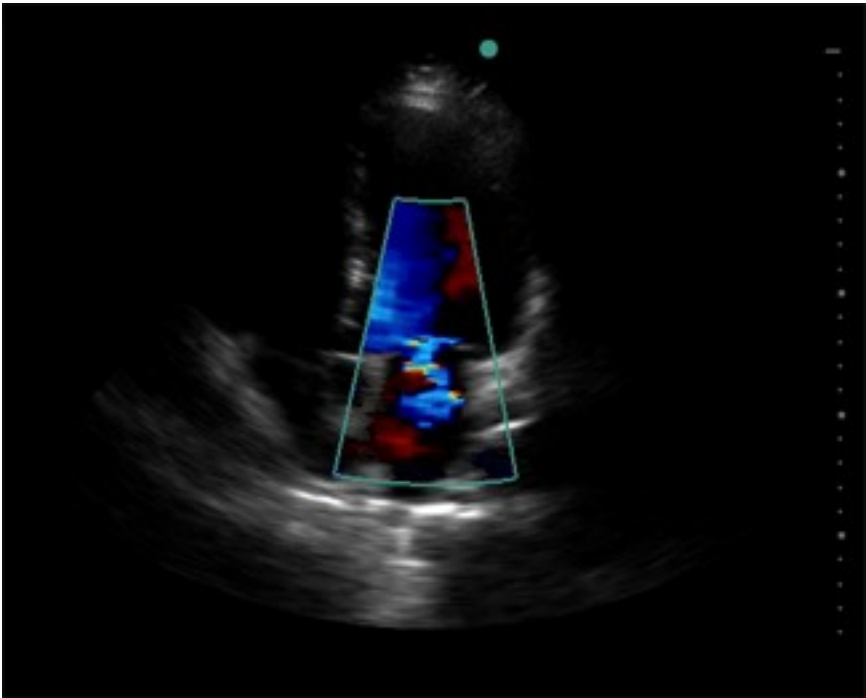


Figure 13. Apical four chamber view of a rheumatic mitral valve showing regurgitation by color flow Doppler

This means that during systole, when the left ventricle is contracting, there is blood leaking from the left ventricle through the mitral valve into the left atrium. This mitral regurgitation is abnormal.

Subxyphoid view

To obtain a subxyphoid (or subtotal) view, place the patient on their back and have them bend their knees to relax their abdominal muscles. Place the probe in the subxyphoid region with the probe marker facing the patient's left side, as shown in Figure 14.

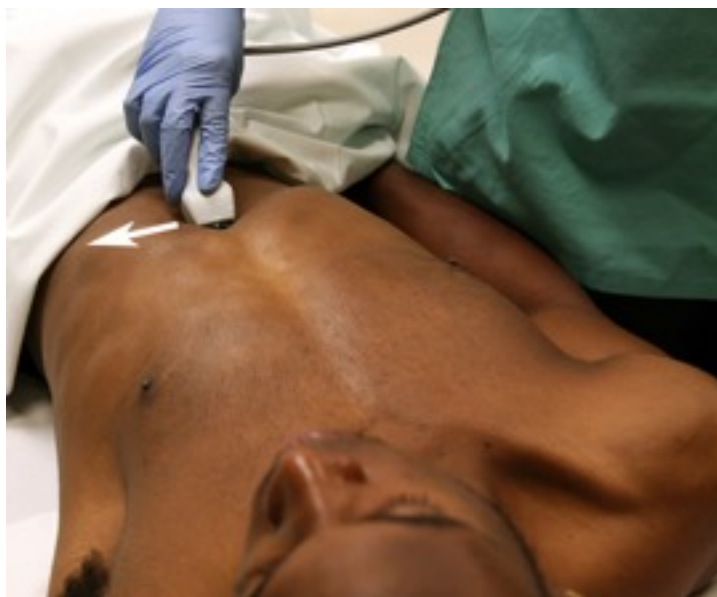

Figure 14. Probe position for subxyphoid view. The probe marker toward the patients left (arrow)

In this view, the ventricles are noted on the right of the screen and the atria on the left. Figure 15 shows an ultrasound image of the heart from a subxyphoid view.

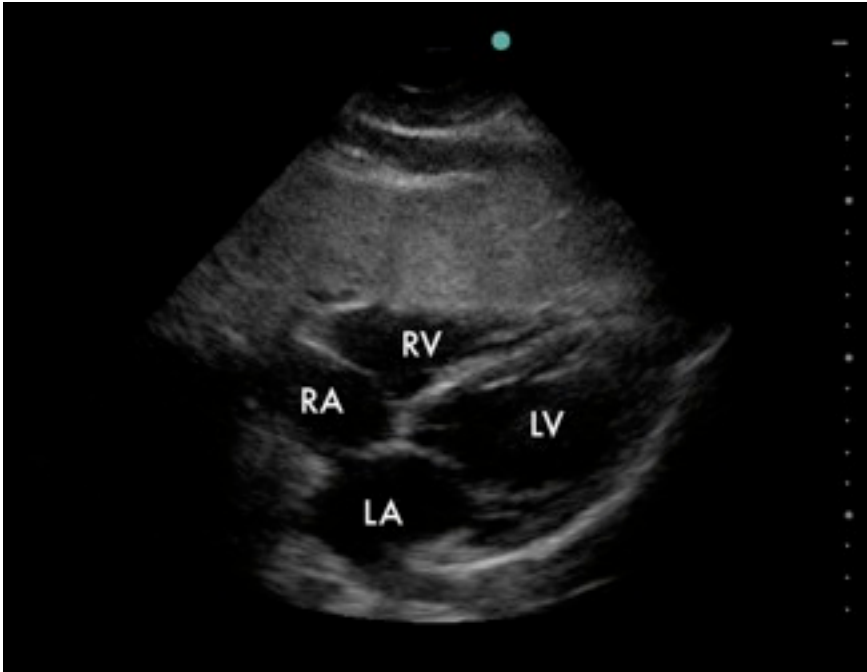


Figure 15. Subxyphoid view showing the liver as an acoustic window, the right ventricle (RV), left ventricle (LV) and atria (RA and LA)

This view is most useful for evaluating for pericardial effusion. If you have difficulty obtaining a good image, try having the patient take a breath and hold it for a few seconds. This will move the heart down towards the abdomen and closer to the ultrasound probe.

A pericardial effusion will appear as an echo-lucent (black) area between the heart and the thin white stripe of the pericardium, as shown in Figure 16.

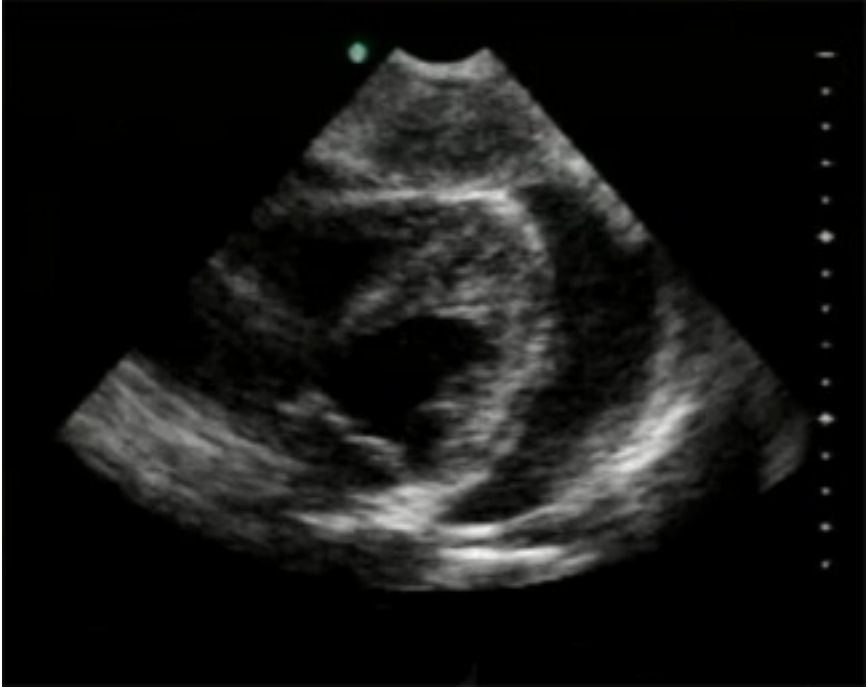

Figure 16. Subxyphoid view showing a pericardial effusion

As mentioned, if the pericardial effusion has more inflammatory debris, as in a pericardial effusion related to tuberculosis, the pericardial effusion may appear more gray or echo-dense.

The subxyphoid view is also useful to visualize the inferior vena cava (IVC). This is done by focusing on the

right atrium. The transducer is then turned slowly counterclockwise until a linear, vascular structure is seen emptying into the right atrium. This structure is the IVC. In an individual with normal right atrial pressures, the IVC should appear small (less than 1.8 cm in diameter in an adult). If the patient is asked to sniff, the IVC should collapse.

In patients with heart failure and elevated right atrial pressures, the IVC is dilated and fails to collapse with inspiration.

This finding is particularly helpful in patients with ascites, in whom constrictive pericarditis is suspected. Constrictive pericarditis can be difficult to diagnose by echocardiography or physical examination. Patients with tuberculosis can have both constrictive pericarditis and exudative ascites complicating the picture.

A normal appearing IVC, in the absence of a cardiomyopathy, mitral stenosis, a dilated right ventricle, or loud murmurs, makes a cardiac cause of ascites extremely unlikely.

Conclusion

With training, general health care providers can become proficient in echocardiography. The main indications for cardiac echocardiography in resource poor settings include evaluation for pericardial effusion and heart failure.

Basic echocardiography should focus on systemic evaluation for a limited set of easily recognizable findings.

These findings help place patients along appropriate clinical pathways and help prioritize potential surgical candidates for complete echocardiography.

Recommended reading

1. Cosby K, Kendall J. *Practical Guide to Emergency Ultrasound*. Philadelphia, PA: Lippincott Williams & Wilkins, 2006.
2. Feigenbaum H, Armstrong W, Ryan T. *Feigenbaum's Echocardiography*, 6th Edition. Philadelphia, PA: Lippincott Williams & Wilkins, 2005.
3. Oh J, Seward J, Tajik J. *The Echo Manual*. Philadelphia, PA: Lippincott Williams & Wilkins, 2006.

4. Otto C. *The Practice of Clinical Echocardiography*, 2nd Edition.
Philadelphia, PA: W.B. Saunders, 2002.
5. Solomon S. *Essential Echocardiography*. Totowa, NJ: Humana
Press, 2007.

Obstetrics:

1st trimester

DAN PRICE MD

Introduction

Ultrasound is an important tool to evaluate pregnant women. This chapter will discuss the use of ultrasound in evaluating women for ectopic pregnancy, how to identify a normal uterus, and how to estimate the age of the baby.

Ectopic pregnancy

An ectopic pregnancy occurs when baby is outside the uterus (womb). When a pregnancy is ectopic, it is usually located in one of the fallopian tubes. Ectopic pregnancies are a problem early in the pregnancy — in

the 1st trimester. When an ectopic pregnancy ruptures, the mother can die from internal bleeding, because the fetus cannot continue to grow inside the fallopian tube.

A pregnant mother is at risk for an ectopic pregnancy when she has lower abdominal pain and possibly a small amount of bleeding from her vagina. Her abdomen will usually be tender.

Ultrasound is the most helpful way to diagnose an ectopic pregnancy. It is rare to see the baby, or fetus, outside the uterus. So a possible ectopic pregnancy is diagnosed when:

1. No baby is seen in the uterus.
2. Blood is seen in the pelvis and possibly between the liver and kidney.

If a baby is seen in the uterus, there is probably not an ectopic pregnancy. Blood in the pelvis or abdomen means that the ectopic pregnancy has ruptured, and the mother will need immediate surgery to avoid complications. Bleeding from ectopic pregnancy can be life threatening.

Technique

Use an curved transducer (Figure 1).

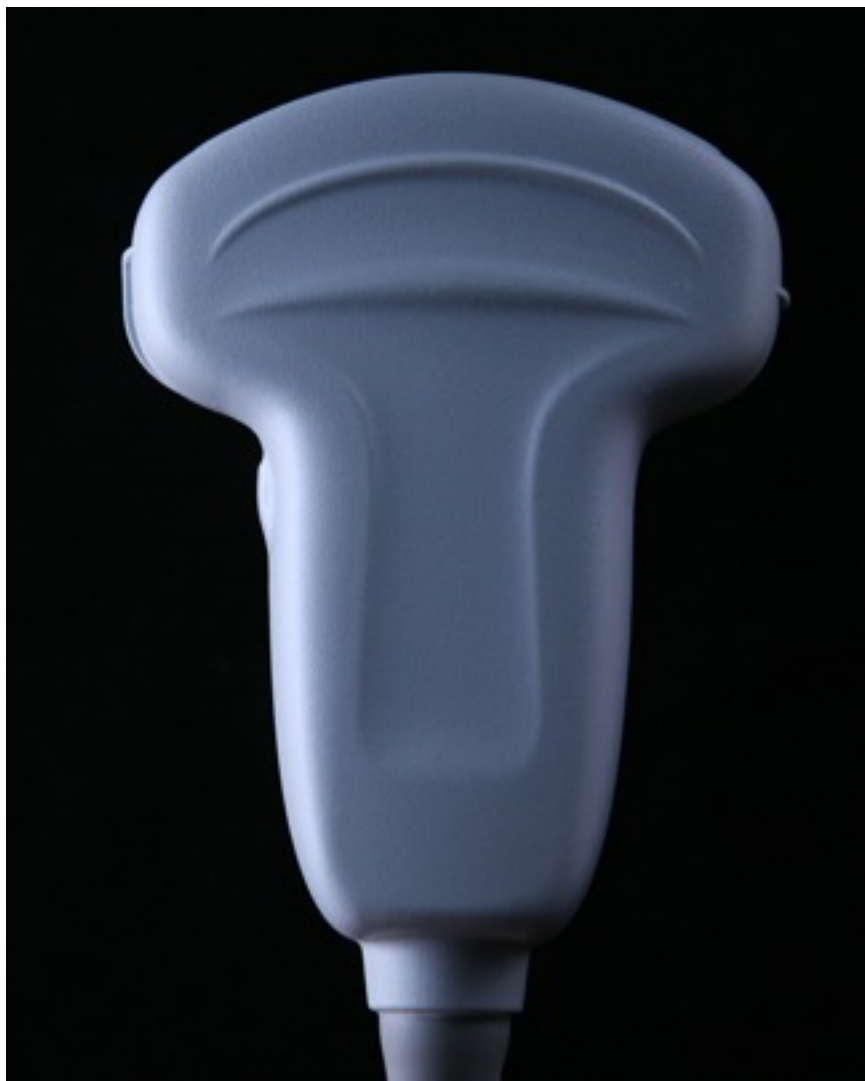

Figure 1. The curved transducer

The index marker (bump or line) should point to the mother's head for the long axis view of the uterus. The other end of the transducer without the marker should rest against the pubic bone (Figure 2).

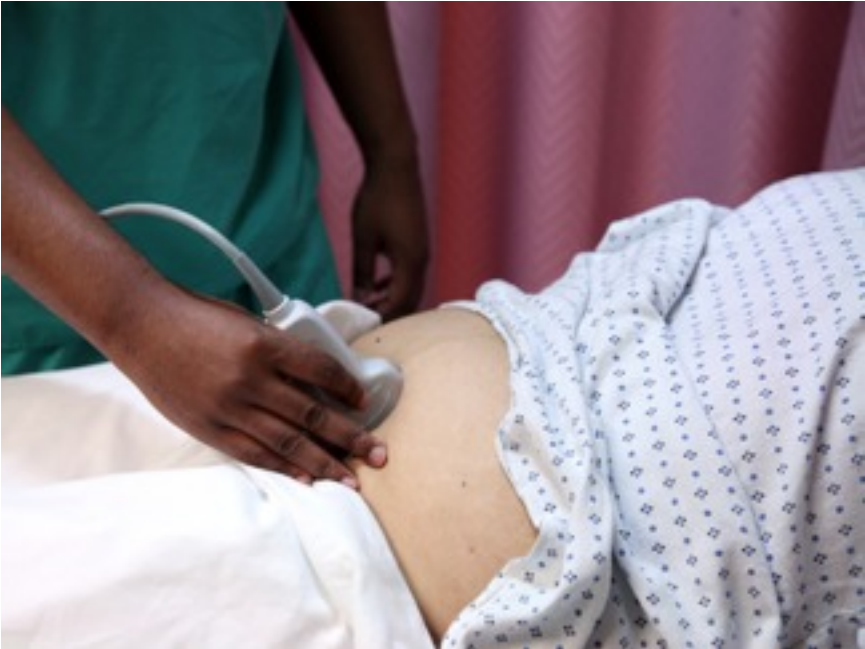

Figure 2. Probe position for first trimester scan

Findings: empty uterus

Fluid, such as blood or urine, looks black, or hypoechoic, on ultrasound. In a longitudinal view, urine in the bladder looks like a black, or hypoechoic, triangle on the right side of the screen next to the uterus (Figure

3). The uterus is shaped like a bean. On the screen, it appears gray, or moderately echogenic. The sonographer should “fan” or rotate the ultrasound transducer to view the entire uterus. The normal, non-pregnant uterus has a thin hyperechoic white line in the center that is the endometrium.

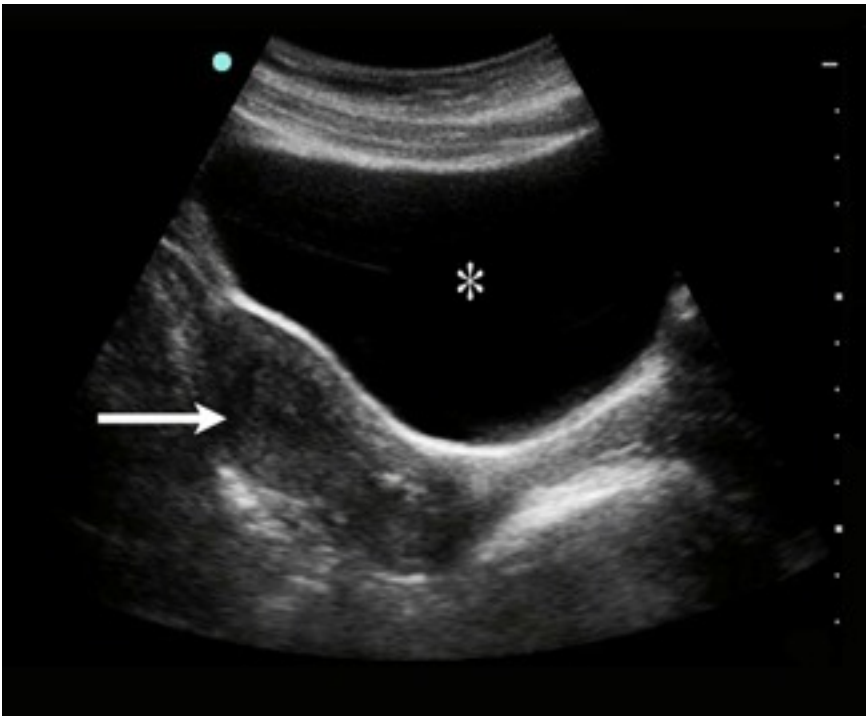


Figure 3. The bladder (*) and empty uterus (arrow)

An empty uterus may cause the clinician to worry about an ectopic pregnancy. A ruptured ectopic pregnancy blood may extend into the abdomen, so it is important

to look for blood within the abdomen as well as the pelvis. The sonographer can begin imaging the area between the liver and the kidney on the mother's right side. This is the same window that is used to look for blood in the trauma exam (Figure 4).

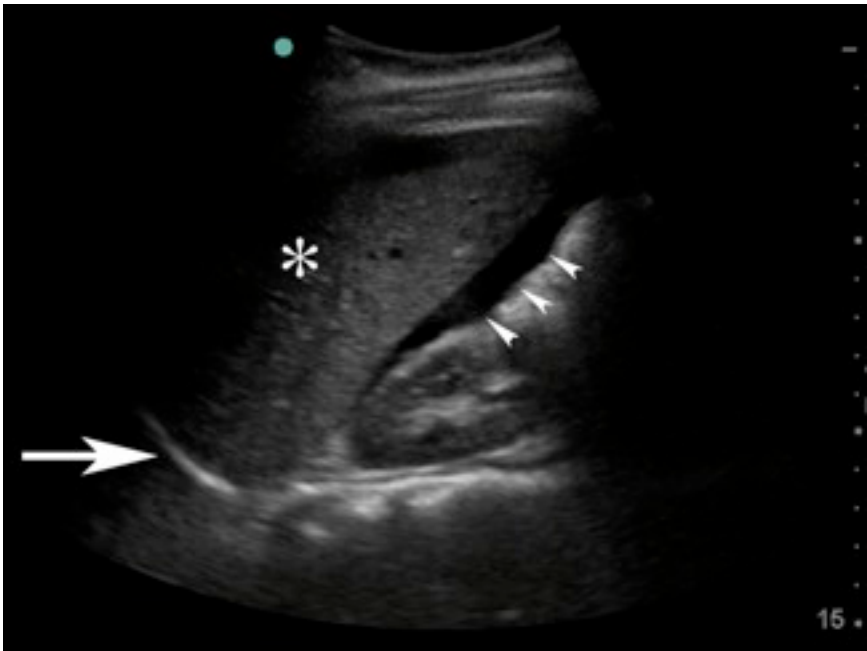


Figure 4. Blood (arrowheads) between the liver (*) and kidney. The diaphragm is marked with an arrow.

It is important to also look for blood in the pelvis, and left upper quadrant as is performed in the trauma exam described in the Trauma chapter. If ruptured ectopic pregnancy is suspected, and bleeding is found within the

abdomen, this finding is an indication for immediate surgery to control the bleeding.

Findings: Contents within uterus

Early in the pregnancy, a normal baby lives in a sack of fluid, the gestational sac, inside the uterus. The first sign that the sack contains a baby is a perfect circle that looks like a bright ring, called the yolk sac (Figures 5 and 6).

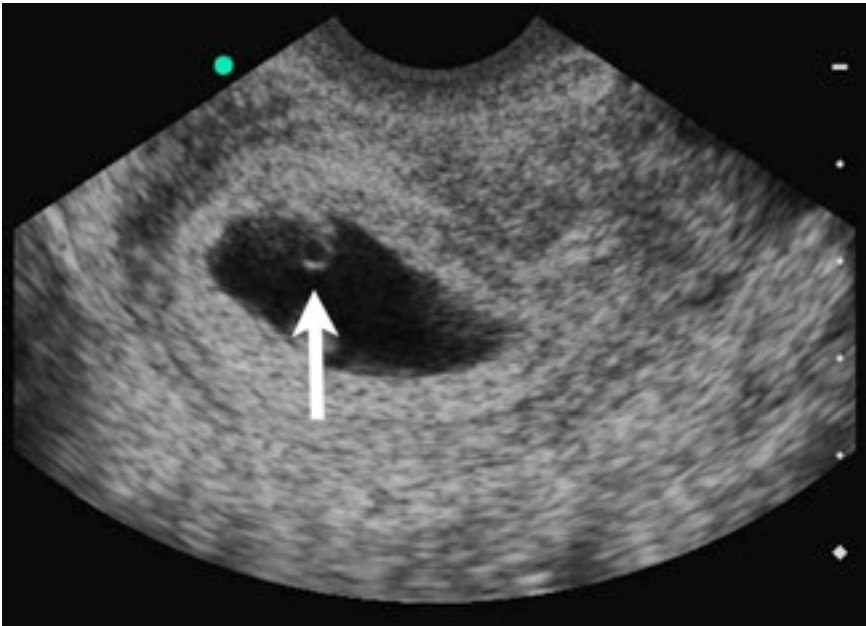


Figure 5. Uterus with a yolk sac (arrow)

The clinician must see the yolk sac to say that the pregnancy is inside the uterus, and that the mother probably does not have an ectopic pregnancy. The yolk sac becomes visible as early as the first week after a missed menstrual period. As the baby gets older, more gray tissue can be seen and is called a fetal pole (Figure 6).

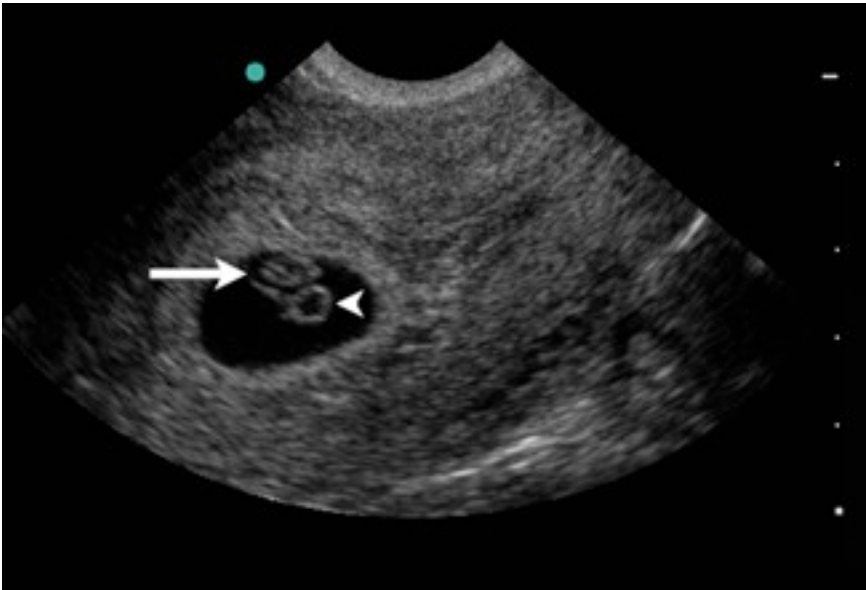


Figure 6. Uterus with a yolk sac (arrowhead) fetal pole (arrow)

It is possible to see a heart beat at about 7 weeks from the mother's last period.

If there is a fetus in the uterus, but the mother complained of bleeding or pain, there is a risk of

miscarriage. She must be examined to make sure there is no infection, and that she has not sustained trauma. If the mother has already miscarried and tissue has been passed from the vagina, she may have some retained products of conception or tissue inside the uterus that can be seen on ultrasound and can cause infection. An example of retained products of conception is seen in Figure 7.

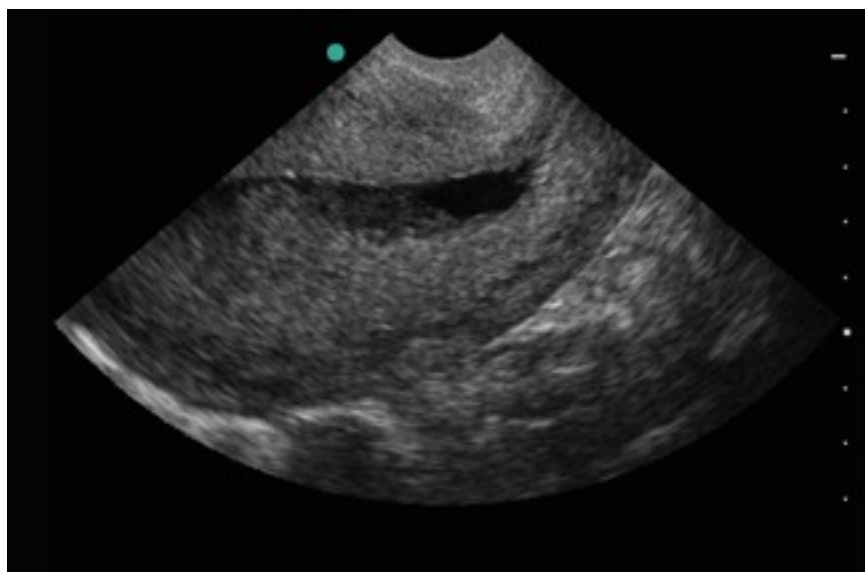


Figure 7. Retained products of conception within the uterus

If there is retained tissue after a miscarriage and any signs of infection, or very heavy bleeding, a dilation and curettage procedure should be performed.

Measuring gestational age

When viewing a baby ultrasound, the sonographer can measure how old it is using ultrasound. This is much more accurate than waiting to feel the uterus with your hand to estimate the baby's age. Knowing the baby's age helps a mother and her family plan for the baby's birth. An accurate age may be very important if the pregnancy is considered high risk and the mother needs to be near a hospital.

As soon as the fetal pole can be seen on ultrasound, the age can be measured. The Crown Rump Length (CRL) is very accurate, and should be used to measure the age when the baby is young (< 14 weeks from the last menstrual period; 1st trimester).

Technique

For the ultrasound exam, use an curved transducer (Figure 1). The index marker (bump or line) should point to the mother's head. The other end of the transducer without the marker should rest against the pubic bone.

While all machines are different, here is an example of step-by-step measurement technique using a Sonosite ultrasound machine. When you see the best images of the baby on ultrasound:

1. Push the Freeze button to stop the picture. The baby should be measured when it looks the longest and both the head and the baby's bottom can be seen in the same picture. (Figure 8)
2. Push the arrow buttons (\leftarrow or \rightarrow) to move through the pictures to find the best one.
3. Push the Calcs button.
4. Move the arrow on the screen until it is over CRL, then push the Select button.
5. Two + signs with a line between them will appear.
6. Move one + to the top of the head (crown).
7. Push Select.
8. Move the second + to the other end (rump).
9. The age of the baby appears at the bottom of the ultrasound screen (Figure 8).

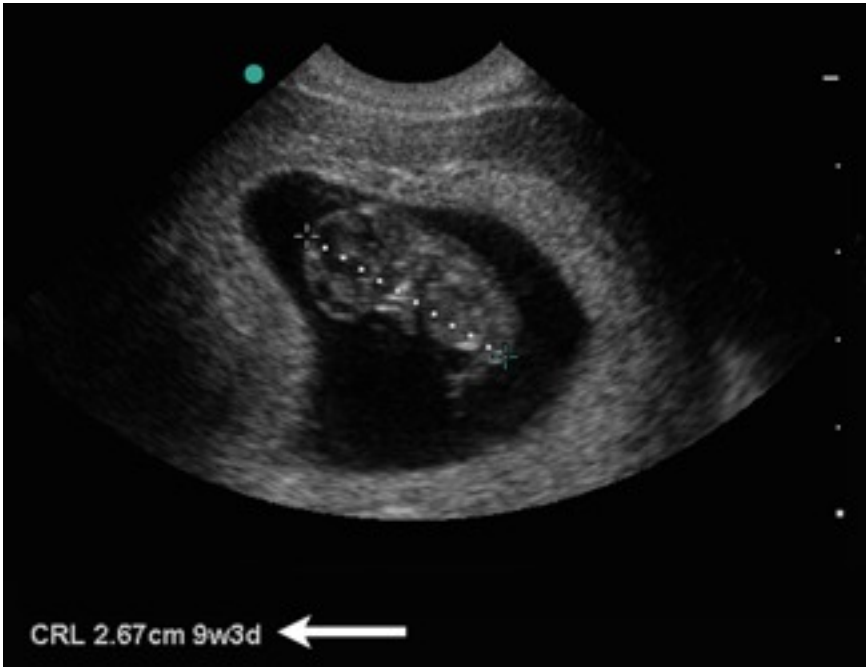


Figure 8. CRL measured with calipers. Gestational age calculation appears at the bottom of the screen (arrow).

Pushing Freeze again will return to active scanning.

Conclusions

Ultrasound is an important tool for the evaluation of pregnancy, to check the baby's gestational age, and to make sure the baby is inside the uterus and not ectopic. Any pregnant patient presenting with pain, bleeding, or in labor with uncertain pregnancy age should have an

ultrasound exam. The information from the first trimester ultrasound can help predict a likely due date, which mothers may need an operation and which mothers can be followed closely for ectopic pregnancy or miscarriage.

Recommended reading

1. First trimester ultrasound. In: Noble VE, Nelson B, Sutingco AN, eds. *Manual of emergency and critical care ultrasound*. Cambridge, England: Cambridge University Press, 2007:85-104.
2. Nordenholz K, Abbott J, Bailitz J. First trimester pregnancy. In: Cosby KS, Kendall JL. *Practical guide to emergency ultrasound*. Philadelphia, PA: Lippincott Williams & Wilkins, 2006:123-160.
3. Reardon RF, Martel ML. First trimester pregnancy. In: Ma OJ, Mateer JR, Blaivas M. *Emergency ultrasound*. New York, NY: McGraw-Hill, 2007:279-318.

Obstetrics:

2nd & 3rd trimesters

SACHITA SHAH MD

JACKLIN SAINT-FLEUR MD

Introduction

Ultrasound is the best imaging modality to evaluate a growing fetus in the 2nd and 3rd trimester, and should be used if any abnormalities are suspected based on history and physical exam of the mother. Ultrasound is generally considered safe in pregnancy. Most patients will tolerate the ultrasound exam well, especially if care is taken to allow the patient to lie on their left side during the ultrasound exam as needed to prevent compression of the vena cava in the supine pregnant patient. Ultrasound in the 2nd and 3rd trimester can be used to determine the age of the pregnancy if last

menstrual period information is not known, evaluate the placenta for previa, evaluate the cervix for premature shortening or opening, assess causes for enlarged fundal size, such as multiple gestation or excess amniotic fluid, and finally to evaluate fetal heart rate. Further ultrasound exams can be done to evaluate for fetal anomalies and birth defects, but will not be discussed in this chapter.

Estimated gestational age

An accurate estimation of the gestational age of the pregnancy is a very important piece of information and can help guide treatment and plans for the pregnant patient. Classically, a pregnancy is dated beginning at the first day of the patient's last menstrual period, to determine the menstrual age or gestational age of the pregnancy. The most accurate time to determine the gestational age of the pregnancy using ultrasound is in the first trimester (before 13 weeks gestational age) using the Crown-Rump Length measurement discussed in the First Trimester Obstetrics chapter. Ultrasound measurements of gestational age in the second or third trimester (weeks 14-42) are thought to be accurate to

within 2 weeks in the second trimester) and to within 3 weeks in the third trimester due to variability in normally growing fetuses.

By week 14 of gestation, development of the fetus has progressed such that it is possible to measure fetal parts to determine the age of the pregnancy. With training and practice, these measurements can be made accurately and easily using ultrasound. In general, use the “OB” mode on the ultrasound machine, and the

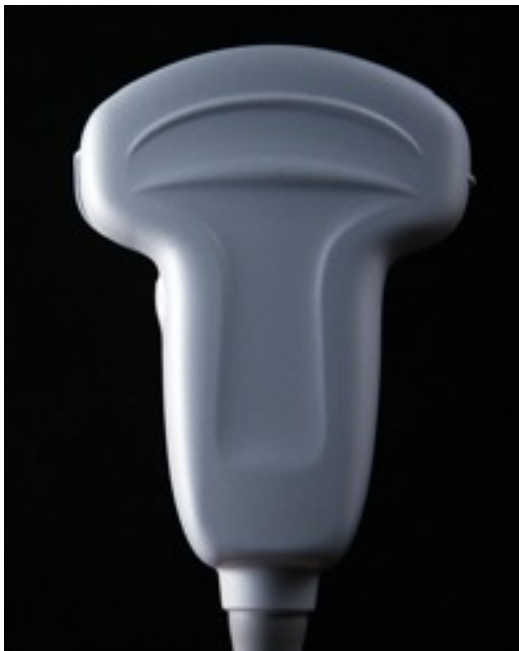

Figure 1. Curved transducer

curved probe (Figure 1) for this exam.

The patient should be on her back or her left side for comfort, and the sonographer should apply very gentle pressure while scanning. Begin by identifying the orientation of the fetus within the uterus, to get an idea of where the

fetal head, heart, abdomen and lower extremities are located within the uterus. Plan to make several measurements and to allow the machine to average the measurements for higher accuracy.

Biparietal diameter

For biparietal diameter (BPD), scan and freeze the image of the fetal head in the axial plane (transverse) to identify these landmarks: the third ventricle, the thalamus, and a smooth, symmetric calvarium (skull bone). Caliper measurements should be made perpendicular to the falx cerebri, from the outer edge of one parietal bone to the inner edge of the opposite parietal bone, as shown in Figure 2.

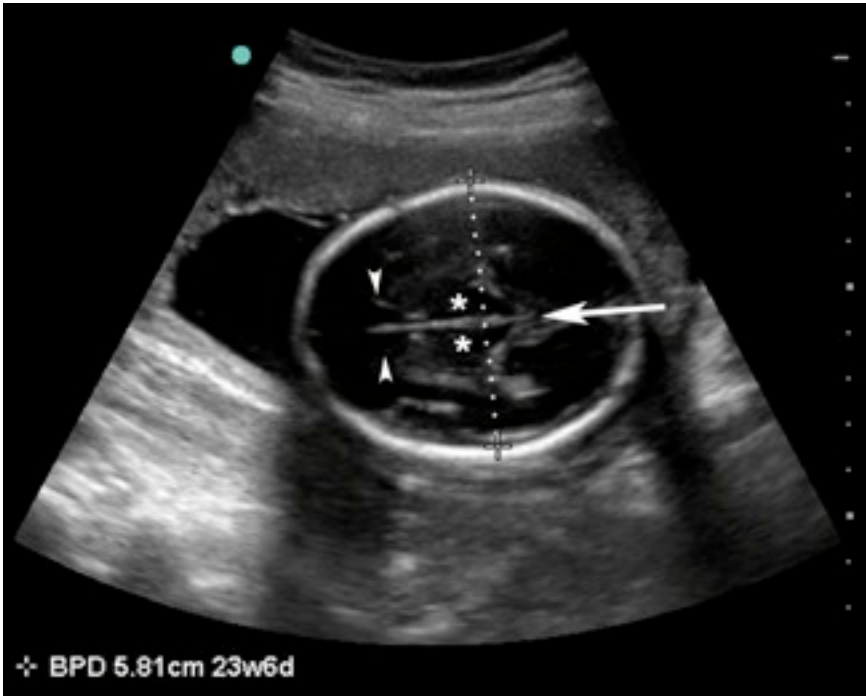


Figure 2. Biparietal diameter measurement. Note the cavum septi pellucidi (arrowheads), falx cerebri (arrow) and thalami (*)

Remember to press the Save button after each measurement to allow the machine to enter the data into the grand calculation for gestational age.

Head circumference

For Head Circumference (HC), the same frozen image may be used, showing the fetal head with calvarium, through the thalamus and third ventricle, and ideally the

cavum septi pellucidi in the frontal portion of the brain. The calipers are placed around the outer edge of the bony calvarium (not the skin edge) in the best-fit position, as shown in Figure 3.

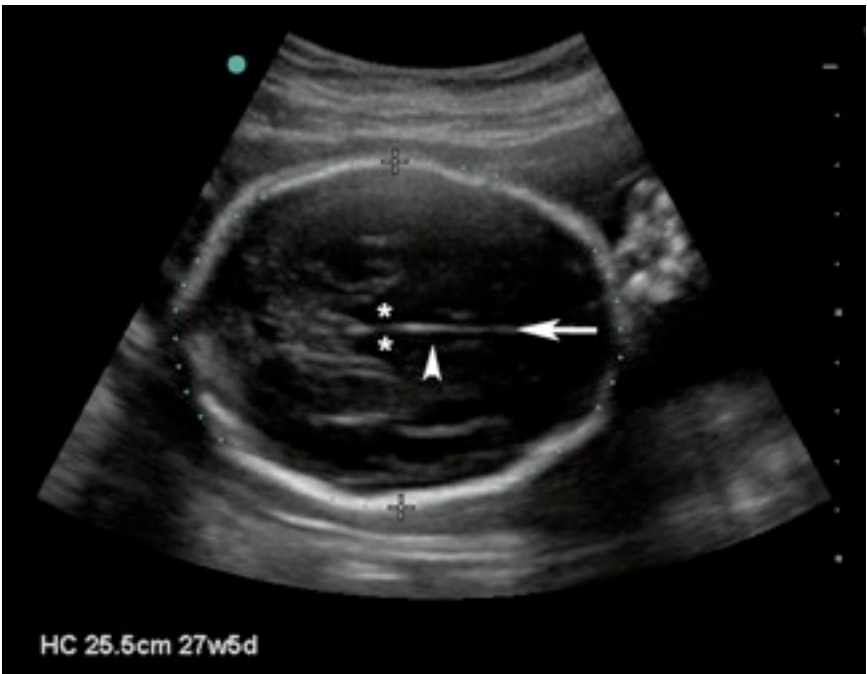


Figure 3. Head circumference measurement with thalamus (*), third ventricle (arrowhead), falx cerebri (arrow) and calipers measuring outer edge of the skull bone

Abdominal circumference

For the Abdominal Circumference (AC), ensure that the measurement of the fetal abdomen is in an axial plane,

and that the following landmarks can be identified: transverse spine, the right and left portal veins, and the stomach. The calipers are placed around the outer skin edge of the abdomen, as demonstrated in Figure 4.

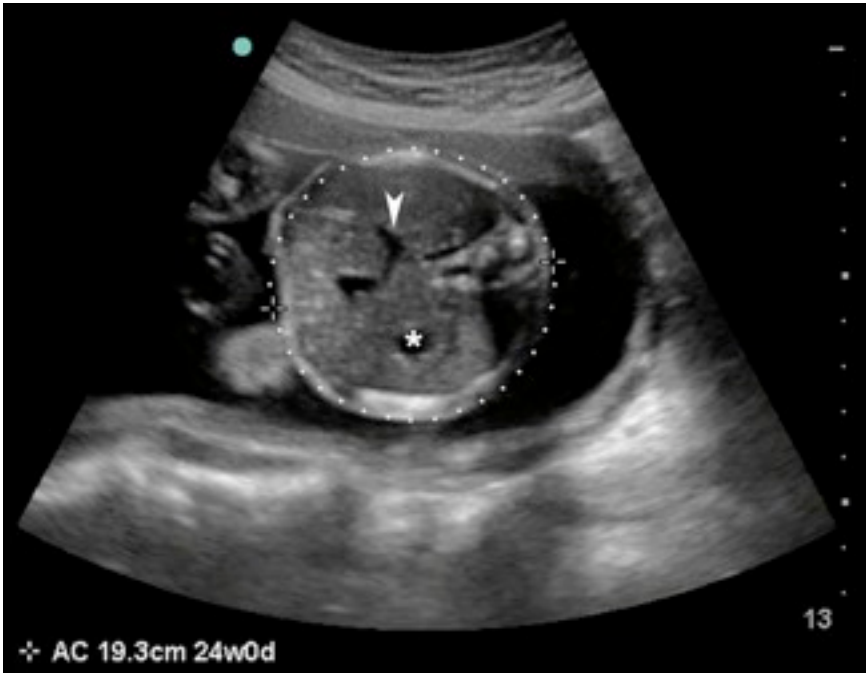

Figure 4. Abdominal circumference measurement. Note the landmarks of the stomach (*) and portal veins (arrowhead)

Femur length

For the Femur length (FL), identify the femur and beware not to measure another long bone that can appear similar, such as the humerus. The best plane of

measurement occurs when the fetal femur is perpendicular to the plane of the ultrasound beam. This avoids artificial foreshortening of the limb on the screen which can cause inaccurate measurements. The fetal femur should be measured along the long axis of the femur, and only the bony portions of the diaphysis and metaphysis should be included. The cartilaginous femoral head, greater trochanter, and free-floating distal femoral epiphyseal ossification center (seen as a floating round hyperechoic dot at the distal end of the femur) are not included in the measurement. An example of correct measurement is shown in Figure 5.

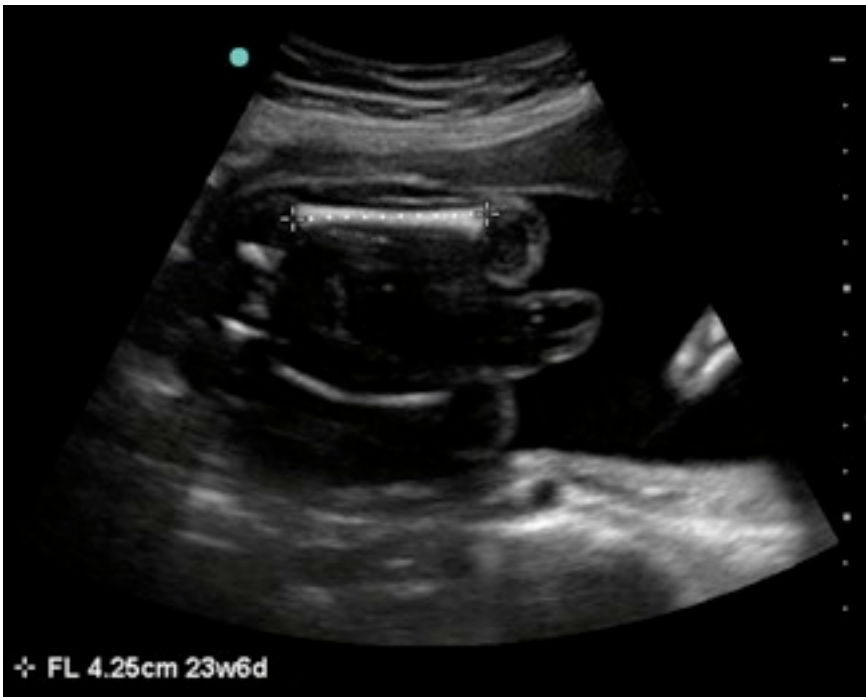

Figure 5. Femur length measurement

Once all measurements have been made, and the Save button pressed after each frozen image is measured, the sonographer may press the Report button to obtain an average of all measurements taken (BPD, HC, AC, and FL) to give a single estimation of gestational age and a single estimated due date (EDD).

Placenta

The growing placenta is often seen on ultrasound by about 10-12 weeks gestational age. It appears as a moderately hyperechoic (gray) structure between the amniotic sac wall and adherent to the uterine wall. The placental location is of prime importance. For the general physician, the most important indication for bedside ultrasound exam of the placenta is to evaluate for placenta previa in patients with unexplained vaginal bleeding. It is important to note the position of the placenta, and whether the inferior portion approaches or crosses over the internal os of the cervix, as shown in Figure 6.

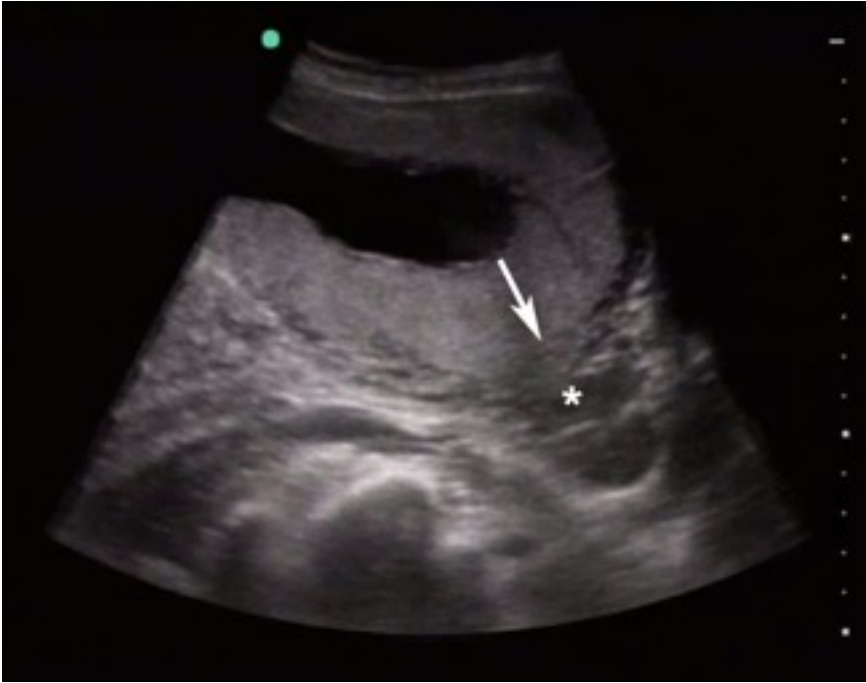


Figure 6. In placenta previa, the placental edge (arrow) crosses over the internal os of the cervix (*)

Calcifications appear as small (1-3 mm) bright hyperechoic spots in the placenta and occur with aging of the pregnancy as well as many other causes such as maternal hypertension, tobacco use, intrauterine growth restriction, and preeclampsia. Grading of the placenta based on calcifications is no longer used, is inaccurate, and does not predict fetal lung maturity.

Cervix

It is important to measure the length of the cervix in the pregnant 2nd and 3rd trimester patient. By identifying a patient with a shortened or prematurely dilating cervix early, before fetal loss, premature rupture of membranes or premature labor, it is possible to prevent poor outcome for the mother and fetus. Cervical insufficiency (premature opening of the cervix) often occurs between weeks 16 and 28 in single gestation pregnancies.

Unfortunately, physical exam of the cervix only identifies patients with cervical change involving the external os and distal cervix. Ultrasound can help to identify early changes involving the internal os which happen well before changes that can be found by digital exam of the cervix. The normal length of the cervix from internal os to external os is more than 2.5 cm and is often 3-4 cm. If cervical length (CL) is less than 2.5 cm or there is “funneling” (Figure 7), cervical insufficiency can be suspected. Consultation with an obstetrician for potential emergency cervical cerclage (suture), bed rest, and pelvic rest (no internal exams or intercourse) is indicated.

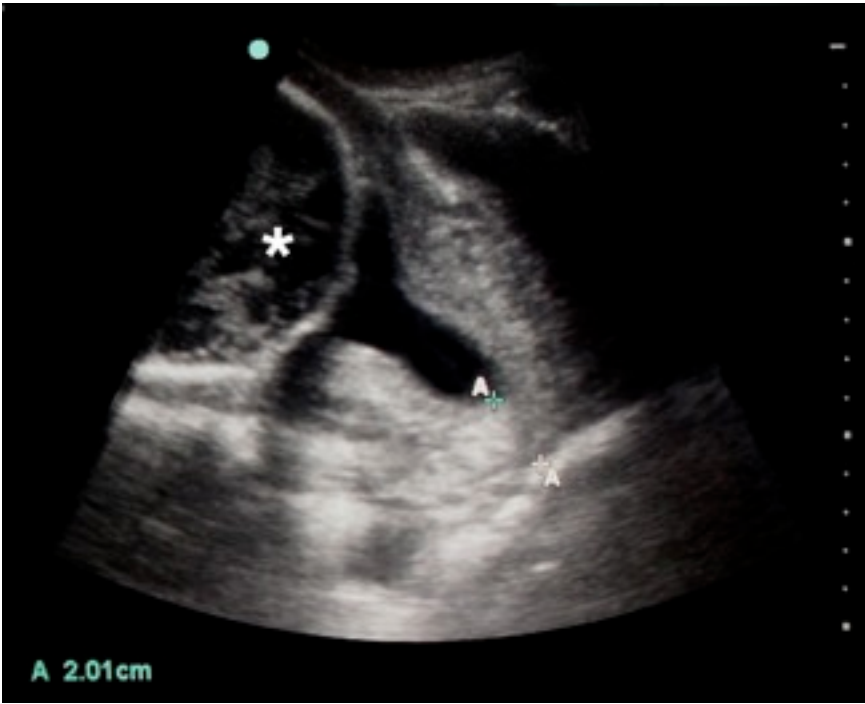


Figure 7. Shortened cervical length with funneling of membranes. The * indicates the fetal head.

To measure the cervix, it is important to note that transvaginal (TV) ultrasound is the most accurate and appropriate method of ultrasound to measure cervical length. If unavailable, transabdominal (TA) scanning may be used, but is less accurate and requires the patient to have a full bladder. For TA scanning, place the ultrasound probe low on the patient’s abdomen, just above the pubic bone, in a sagittal position. Identify the

bladder, vaginal stripe, and curved part of the lower segment of the uterus and cervix, as seen in Figure 8.

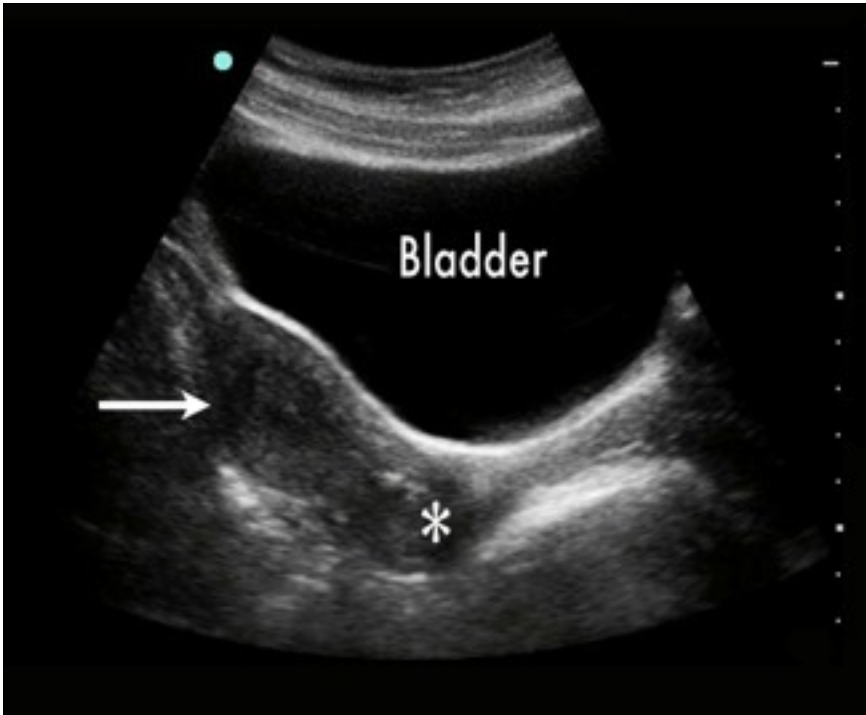


Figure 8. Normal anatomy in sagittal view. Note the bladder, uterus (arrow) and cervix (*)

Measure from the internal os to external os of the cervix using the Caliper and Select buttons.

For TV scanning, be sure to cover the probe with a clean condom or probe cover. Place ultrasound gel on the inside of the condom and sterile lubricant on the outside. The patient's bladder should be emptied for

comfort and for increased accuracy of the ultrasound exam. Gently insert the probe tip about 5 cm into the vagina. Visualize the entire length of cervix and measure from internal to external os for CL.

In general, the TV ultrasound exam for cervical length should take only a few minutes. When performed by a trained sonographer with at least 50 practice exams, CL measurements can be highly accurate.

Large for gestational age

In assessing a patient whose uterine fundus measures large for their expected gestational age by physical exam (external palpation of the uterus through the mother's abdomen), it is important to evaluate for excess fluid and multiple fetuses that may increase the size of the uterus.

Multiple fetuses

For every ultrasound exam performed, always scan through the entire uterus to ensure there is only one fetus. Early identification of multiple gestation pregnancies can allow you to direct the patient to

appropriate close care and follow up to prevent preterm births (Figure 9) or complications. If there is suspicion for more than one fetus, look for easily identifiable structures such as the heart or head to confirm the number of fetuses. Also note if it is early enough, whether the fetuses are diamniotic and have separate sacs, or are sharing the same sac. Note the presence and number and position of any placental tissues.

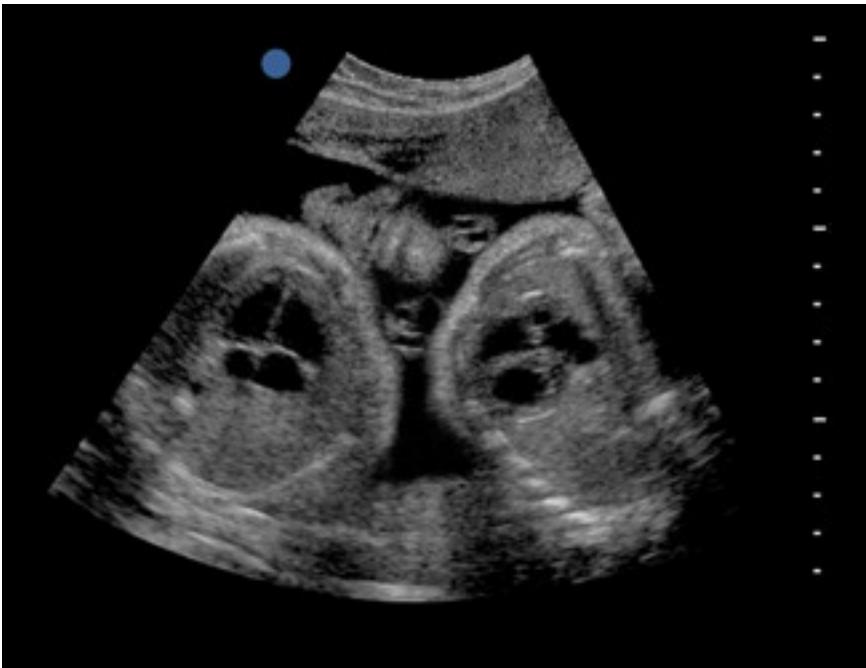

Figure 9. Twin pregnancy showing 2 hearts

Amniotic fluid

Assessing whether there is an appropriate amount of amniotic fluid around a fetus is important in the second and third trimester. Fetuses with less fluid than normal, or oligohydramnios, may be at risk for preterm birth, renal agenesis (absence of the kidneys), intrauterine fetal demise, and infection. Typically, low fluid is caused when the membranes rupture and leak slowly. Excess amniotic fluid, or polyhydramnios, is also a problem that should be addressed. Amniotic fluid volume may be estimated using a gestalt, or visual estimation of fluid, to see if it looks normal or low based on the sonographer's opinion. Amniotic fluid volume may be measured using ultrasound.

One technique for measuring the amniotic fluid is AFI or amniotic fluid index. For this measurement, visually divide the gravid uterus into four quadrants using the mother's umbilicus and linea nigra as landmarks for the center line, as shown in Figure 10.

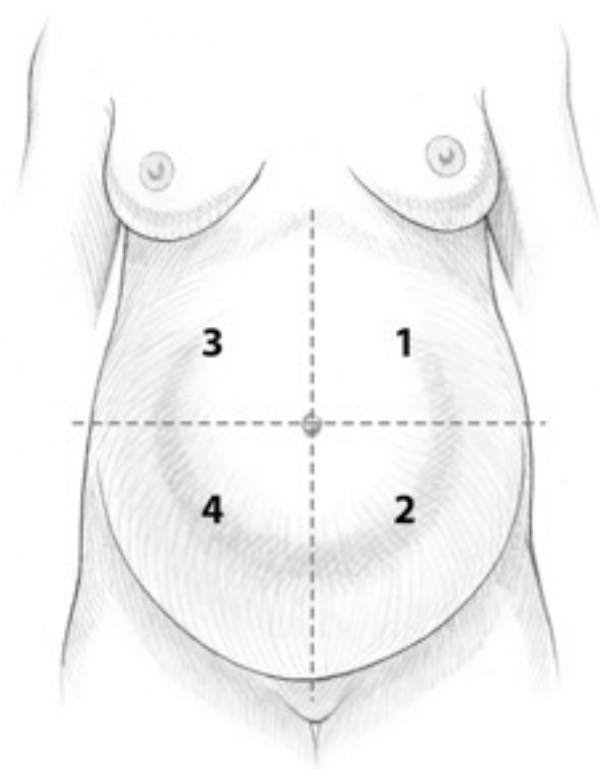


Figure 10. The gravid uterus is divided into four quadrants. The mother's upper left quadrant is number 1, lower left is number 2, right upper quadrant is number 3 and right lower quadrant is number 4.

Amniotic fluid pockets in each quadrant are measured from the superficial edge of the pocket to the deepest fetal structure (Figure 11). The measurements added together to produce the AFI. Oligohydramnios can be defined as an AFI less than 7-8 cm, while values greater

than 20 cm suggest polyhydramnios. In general, an AFI of 7-20 cm is considered normal.

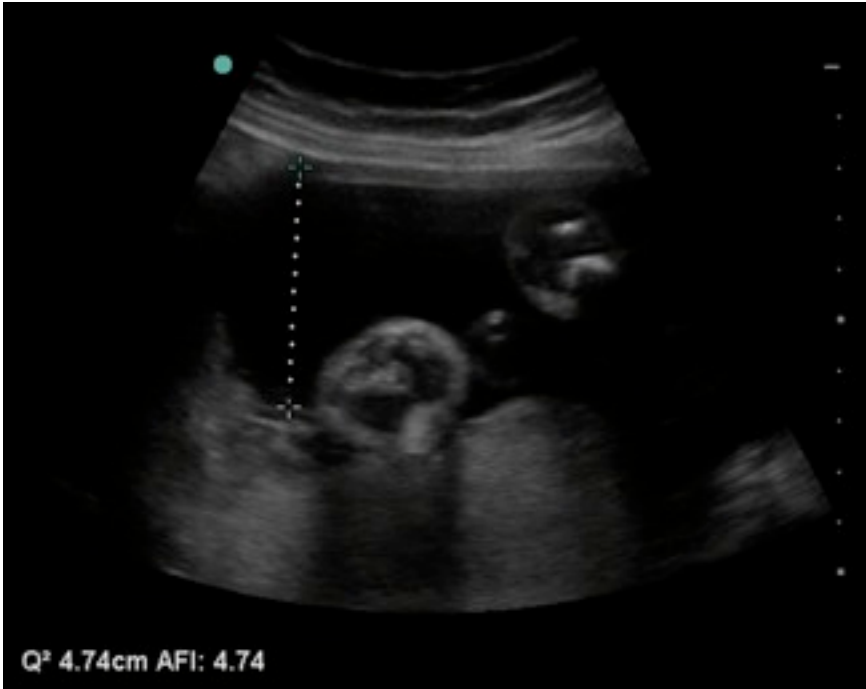

Figure 11. Amniotic fluid pockets in each quadrant are measured from the superficial edge of the pocket to the deepest fetal structure.

Fetal heart rate

A normal fetal heart rate (FHR) is between 120 and 180 beats per minute. Usually the FHR can be heard with a fetoscope or Doppler machine, however for every 2nd and 3rd trimester ultrasound scan, it is important to

confirm the fetal heart rate as the first part of the ultrasound. To calculate the FHR, either watch the beating fetal heart and count manually, or use the ultrasound machine in M-mode to do the calculation, as shown in Figure 12.

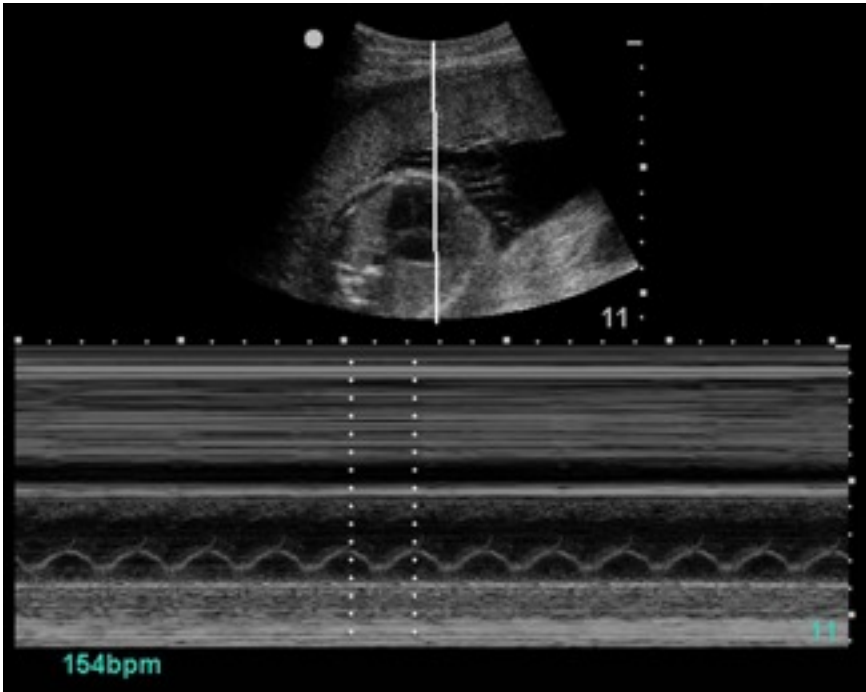


Figure 12. Fetal heart rate measurement using M-mode

1. For this technique, use OB mode under scan type in the Patient section.
2. Find the fetal heart.

3. Maximize the size of the heart on the screen by changing the depth and possibly using the Zoom button.
4. Press the M mode button and move the reference line over the beating heart. Then press M Mode again.
5. When the fetal heart tracing has continued for several heartbeats, press the Freeze button.
6. Press the Calc button and select FHR.
7. Move the dotted line over one peak of one heart beat and press Select. A second dotted line will appear and should be moved to the next peak.
8. The calculated FHR will appear in the lower right corner of the screen (Figure 12).

Never use Doppler mode on the fetal heart. M mode is safe and applies less energy to the growing heart, but Doppler concentrates high energy and heat on the delicate growing heart of the fetus and should not be used.

Conclusion

Ultrasound is a useful tool for evaluation of second and third trimester pregnancies. An example documentation of an obstetric ultrasound would be: “live, singleton intrauterine pregnancy with fetal heart rate 150 bpm by M mode. Estimated gestational age using BPD, and FL is 32 weeks 4 days. Placenta anterior — no previa. Cervix 4 cm and closed. AFI 12”. For abbreviated exams, it is acceptable to simply state there is a live single fetus.

Recommended Reading

1. Barnett SB. Recommendation on the safe use of ultrasound. Paper presented at Proceedings of the Symposium of Safety on Ultrasound in Medicine, WFUMB (World Federation for Ultrasound in Medicine and Biology), 1998.
2. Benson CB, Doubilet RM. Fetal measurements: Normal and abnormal fetal growth. In: Rumack CM, Wilson SR, Charboneau JW, eds: *Obstetric and Fetal Sonography*. 2nd ed. St Louis, MO: Mosby-Year Book, 1998.
3. Bergella V, Bega G, Tolosa J, et al. Ultrasound assessment of the cervix. *Clin Obstet Gynecol* 2003;46:947.

4. Callen P. *Ultrasonography in Obstetrics and Gynecology*: 5th Ed. Philadelphia, PA: Saunders Elsevier, 2008.
5. Fox H. The development and structure of the placenta. In: Fox H, ed. *Pathology of the placenta*. 2nd ed. London, England: WB Saunders, 1997: 1-41.
6. Hadlock FP. Sonographic estimation of fetal age and weight. *Radiol Clin North Am* 1990;28:39.
7. Zhu J, Lin J, Zhu Z, et al. Effects of diagnostic levels of color Doppler ultrasound energy on the cell cycle of newborn rats. *J Ultrasound Med* 1999;18:257.

Liver

SUPRIYA GUPTA MD

SUNG HAN KIM MD

GARRY CHOY MD, MSC

Introduction

The liver is largest abdominal internal organ that can be well evaluated using ultrasound imaging. This chapter will focus on basic anatomy and common pathology of the liver. Clinical indications for ultrasound of the liver include patients presenting with abdominal or right flank pain or tenderness, jaundice, hepatomegaly, or with concerns for metastatic malignancies.

Technique

The liver is typically imaged using a curved transducer using a subcostal or intercostal approach in the right

upper quadrant. The liver is usually imaged simultaneously with other organs such as gallbladder, spleen, pancreas, and/or kidneys. Higher frequency transducers can also be used to assess fine detail of the hepatic anatomy. The subcostal window involves placing the ultrasound probe obliquely along the inferior margin of the anterior rib-cage generally at full inspiration. Instructing the patient to breath hold can improve imaging quality. The subcostal approach allows for visualization of both lobes of the liver. Bowel gas can sometimes limit visualization of the liver via the subcostal approach. A subcostal approach also allows visualization of the liver parenchyma and right kidney to obtain sagittal views of hepatic echotexture using the kidney as comparison. An intercostal approach can be used to visualize most of the right lobe of the liver in patients who have a significant amount of bowel gas.

Anatomy

The liver is divided into two lobes and subsegments depending on its vascular supply. The anterior and posterior aspects of the liver are smooth and convex. Colon, stomach, right kidney, duodenum, and gallbladder are adjacent to the posterior and inferior

aspect of the liver. The porta hepatis is the site at which the common bile duct and major vasculature structures (portal vein and hepatic artery) are located (Figure 1).

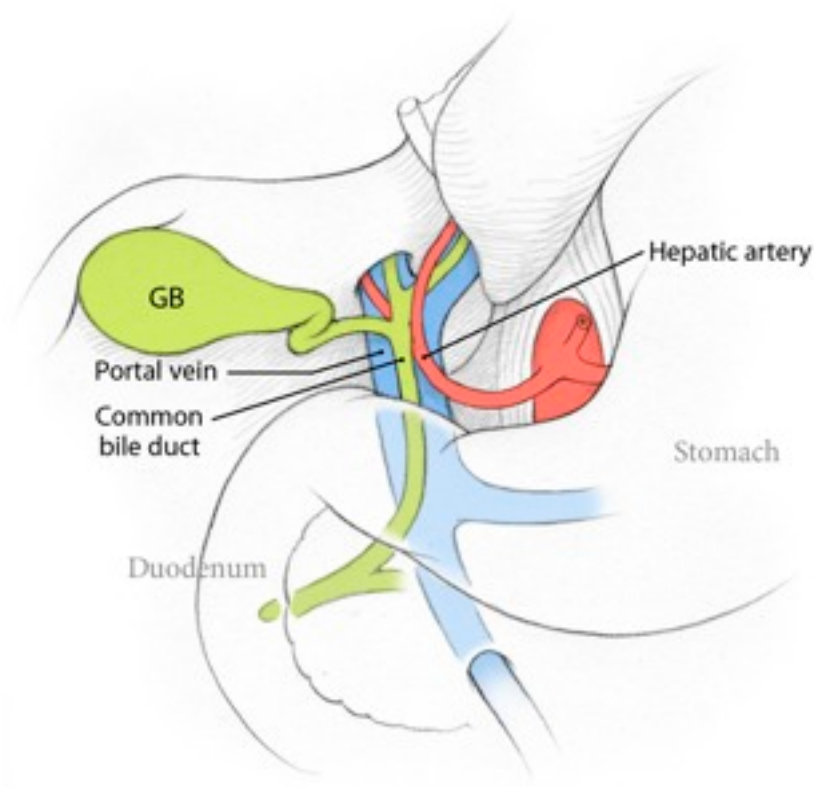


Figure 1. Anatomy of the porta hepatis

The left lobe of the liver is separated by the falciform ligament. The caudate lobe derives its vascular supply from both the right and the left hepatic arteries and is therefore considered to be part of both right and left

lobes. Of note, the caudate lobe may be hypertrophic in cirrhotic patients. The liver has a dual blood supply from the hepatic artery and portal vein. The portal vein and hepatic artery both direct blood towards the liver. The hepatic veins drain blood away from the liver and usually consist of three branches that drain into the inferior vena cava (IVC). Normal echotexture of the liver is fine and homogeneous, and should be approximately equal to or minimally increased in gray color relative to that of the kidney (Figure 2).

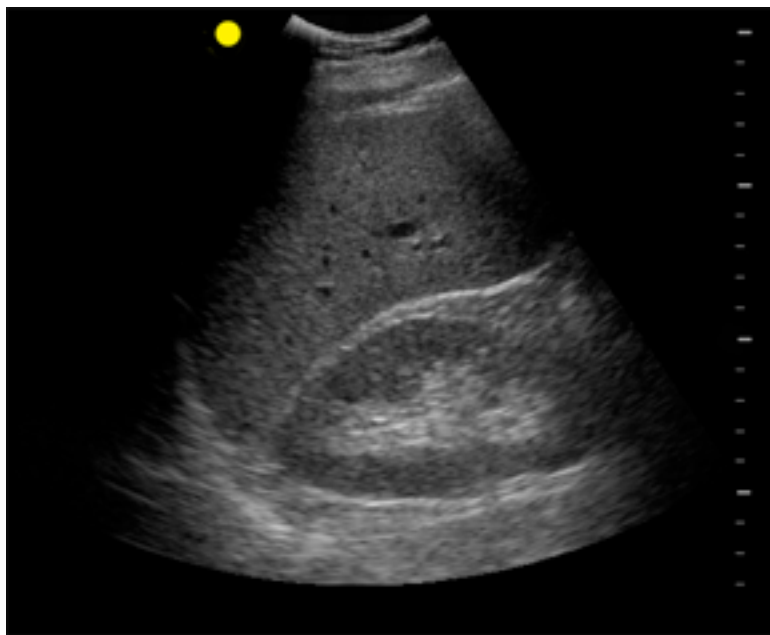


Fig 2. A subcostal view of the liver shows the normal echotexture of the liver is slightly higher, or brighter gray, than the neighboring kidney parenchyma.

Size

The non-uniform shape of the liver, anatomical differences, a variety of measurement techniques and patient positioning all influence the diagnosis of hepatomegaly. The best window to see the liver is at the right mid-clavicular line using the subcostal approach (Figure 2). Multiple prior studies suggest that the normal liver size is less than 13 to 14 cm. If the liver is greater than 16 cm, then hepatomegaly is suggested.

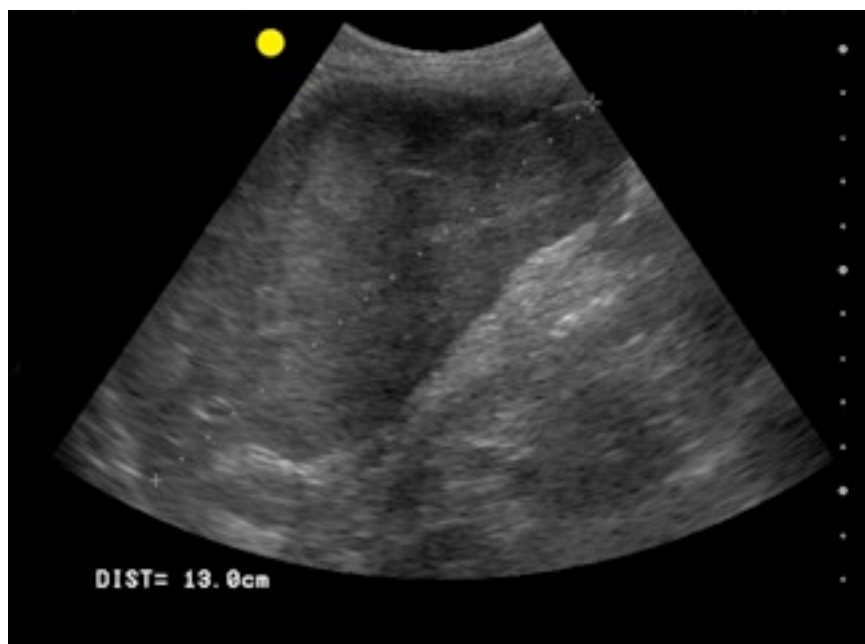


Figure 3. Normal liver measurement. The subcostal approach also enables visualization of both lobes of the liver and facilitates measurement. Normal liver size should measure less than 13 to 14 cm.

Doppler

Doppler techniques can be applied in evaluating patients with portal hypertension or surgical planning. Color Doppler has been successful in documenting patency of the portal vein and pulsatility within the major hepatic artery and larger hepatic veins. Doppler also allows evaluation of the velocity and direction of portal blood flow — useful for evaluating portal hypertension. Filling defects, indicating thrombosis or mass lesions within vessels, can also be better seen using Doppler techniques. Occasionally, direct visualization of the blood supply to hepatic lesions may assist in distinguishing benign from malignant tumors. For example, hepatocellular carcinomas may occasionally demonstrate high vascularity and possibly even a central feeding artery.

Beyond ultrasound

CT and MRI afford further evaluation of the liver but carry the burden of decreased availability in most of the developing world. CT and MRI with contrast can help characterize indeterminate liver lesions. These more advanced imaging tools can offer more specific evaluations of both benign and malignant lesions,

ranging from complex hepatic cysts to hemangiomas or neoplasms.

Pathology

Liver cysts

Cystic liver disease is common in the general population, with increased risk in the elderly and those in areas endemic for echinococcal disease. A simple cyst appears as a well-defined, anechoic (dark) mass and can be multiple in number, usually associated with posterior acoustic enhancement (Figure 4). Low level echoes may be encountered in cysts that contain hemorrhage.

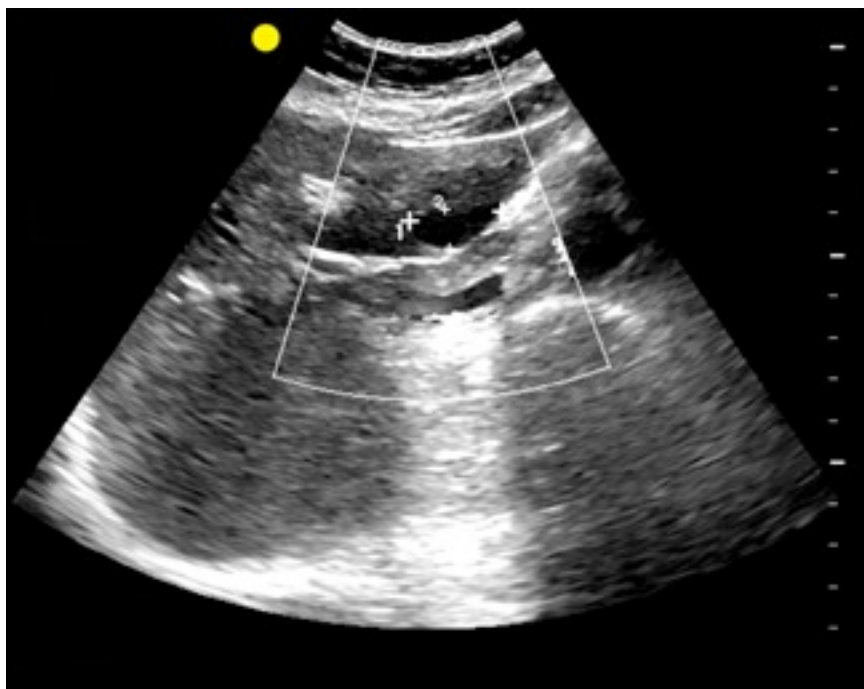


Figure 4. Hepatic cyst (marked by calipers). Simple cysts are well-defined, anechoic foci and can be multiple in number, usually associated with posterior acoustic enhancement.

Metastasis

Metastatic disease is the most common malignant mass lesion in the liver and is much more common than primary liver tumors in most of the world. The liver is the second most common site for metastatic disease, after regional lymph nodes, in setting of neoplasm. The ultrasound appearance of hepatic malignancy lacks specificity in defining the organ of origin, and ultrasound

imaging of liver metastases needs to be taken in clinical context of the patient's presenting complaints and physical exam. Such factors as homogeneity, vascularity, mucin content or desmoplastic response may be more important in accounting for the types of echogenic patterns produced than in determining the actual cell type of the tumor. For example, gastrointestinal tumor metastases that contain large amounts of mucin tend to be echogenic. Similarly, vascular lesions can be echogenic due to numerous interfaces arising from vessels. Fewer echogenic metastases are encountered in processes that are highly cellular but lack internal interfaces.

Large metastases that outgrow their blood supply can be heterogeneous with areas of necrosis and cystic change, making them difficult to distinguish from abscesses. A common type of liver metastases is the "bull's eye" or "target" lesion, and these are commonly associated with adenocarcinomas of breast or gastrointestinal origin. The central area of echogenicity probably arises from mucin, and the anechoic halo may reflect compression and edema of surrounding liver tissue. The response of hepatic metastasis to chemotherapy may also be

monitored by ultrasound. The various appearances of liver metastases are summarized in Table 1.

Ultrasound appearance	Primary Cancer
Hyperechoic (25%)	<ul style="list-style-type: none">• Colon cancer• Hepatocellular carcinoma• Treated breast cancer
Mixed Echogenicity (30-40%)	<ul style="list-style-type: none">• Breast cancer• Rectal cancer• Lung cancer• Stomach cancer• Anaplastic cancer• Cervical cancer• Carcinoid

Ultrasound appearance	Primary Cancer
Hypoechoic (30-40%)	<ul style="list-style-type: none"> • Lymphoma • Pancreatic cancer • Cervical cancer • Lung cancer (adenocarcinoma) • Nasopharyngeal cancer

Ultrasound appearance	Primary Cancer
Calcified liver metastases	<ul style="list-style-type: none"> • Mucinous cancer of GI tract (colon, rectum, stomach) • Endocrine pancreatic cancer • Leiomyosarcoma • Osteosarcoma • Malignant melanoma • Papillary serous ovarian cystadenocarcinoma • Lymphoma • Pleural mesothelioma • Neuroblastoma • Breast cancer • Medullary thyroid cancer • Renal cell cancer • Lung cancer • Testicular cancer

Ultrasound appearance	Primary Cancer
Hypervascular liver metastases	<ul style="list-style-type: none"> • Renal cell cancer • Carcinoid tumor • Colonic cancer • Choriocarcinoma • Breast cancer • Melanoma • Pancreatic islet cell tumor • Ovarian cystadenocarcinoma • Sarcomas • Pheochromocytoma

Ultrasound appearance	Primary Cancer
Mixed solid/Cystic liver metastases	<ul style="list-style-type: none">• Mucinous ovarian cancer• Colonic cancer• Sarcoma• Melanoma• Lung cancer• Carcinoid tumor

Table 1. Ultrasound appearance of metastatic diseases.

Figures 5a, b and c show examples of pancreatic cancer metastases that are hypodense on CT and hypoechoic on ultrasound. Carcinoid metastases in the liver vary in appearance and can demonstrate either hyperechoic or hypoechoic echotexture. Figure 6 shows a focal hypoechoic carcinoid metastasis. Colorectal cancer may demonstrate hyperechoic metastases (Figure 7).

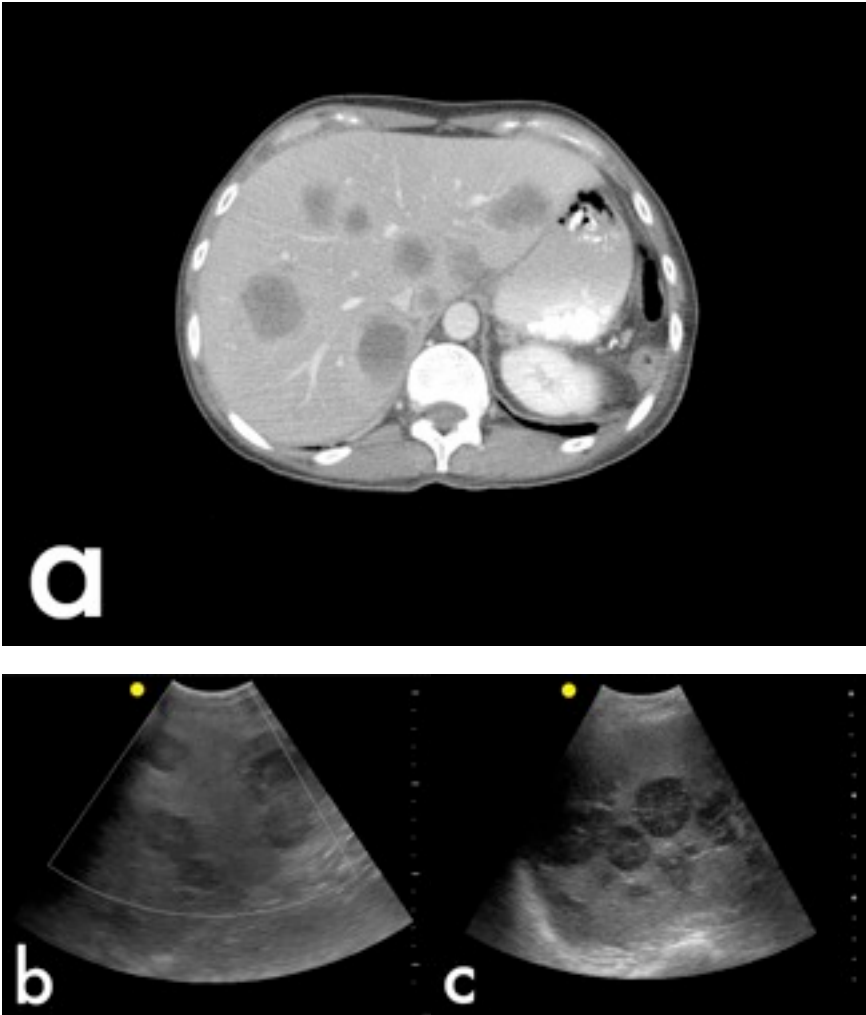


Figure 5. Pancreatic cancer with multiple liver metastases. CT (a) demonstrates multiple low density lesions consistent with metastatic disease. Multiple hypoechoic lesions are seen on ultrasound (b and c).

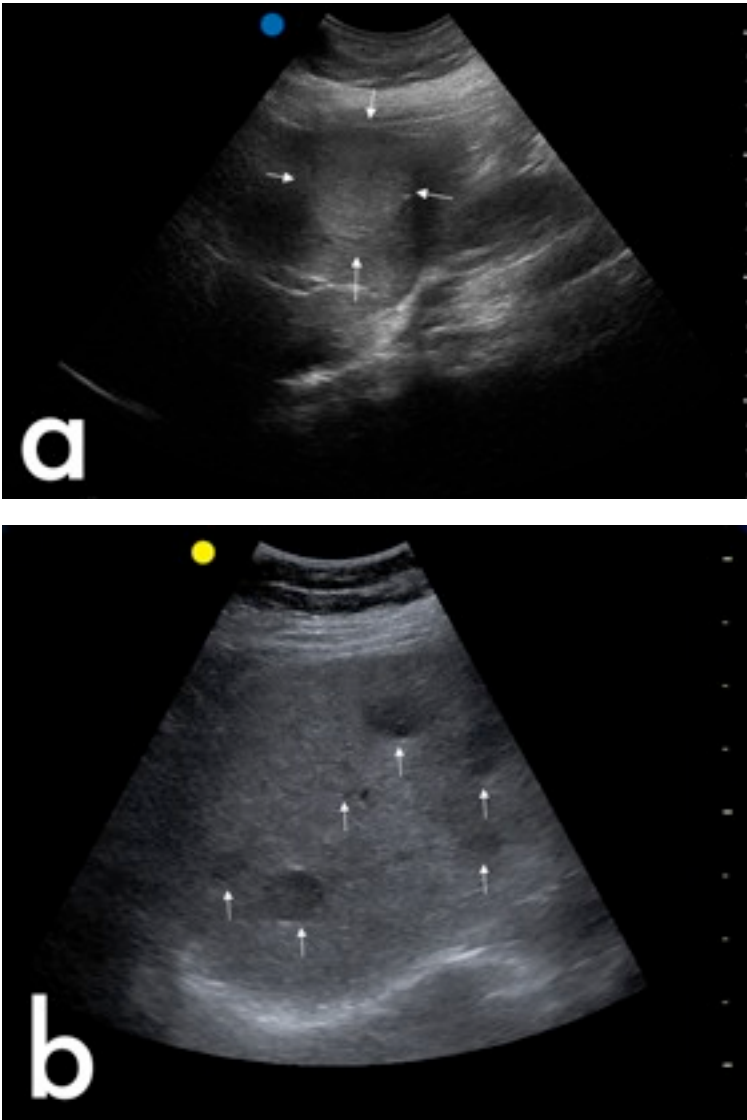


Figure 6. Carcinoid metastasis in liver. The ultrasound image (a) demonstrates a focal hyperechoic carcinoid metastasis (arrow). Carcinoid metastases can vary and may also be hypoechoic (b).

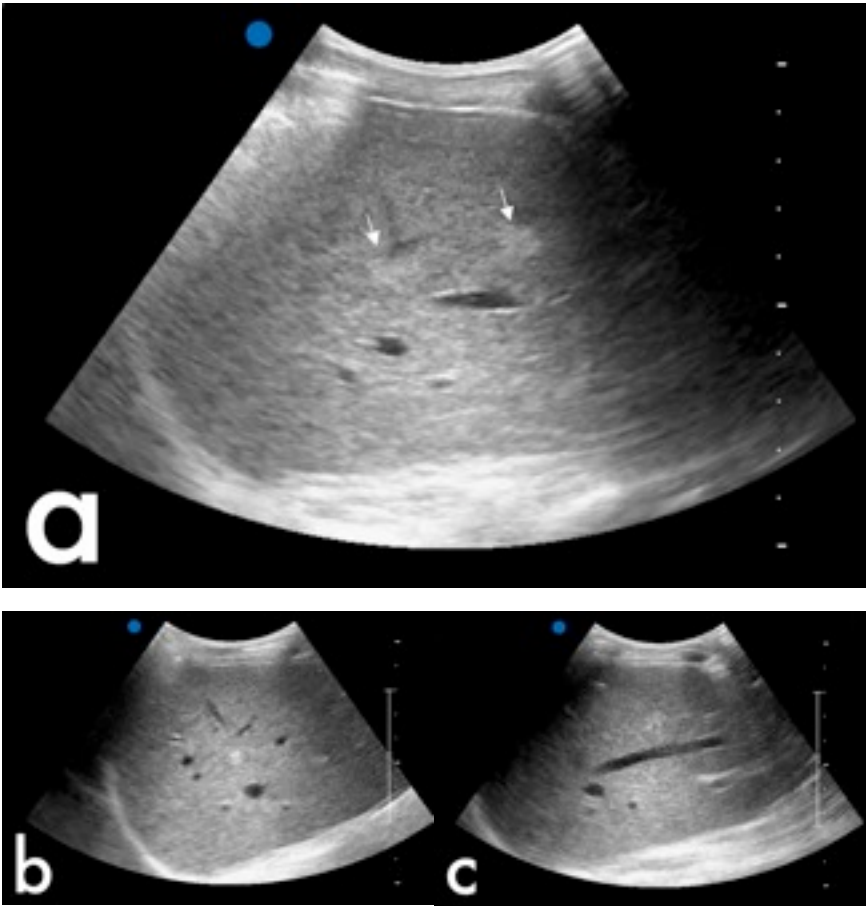


Figure 7. Colorectal cancer metastases in the liver. (a) Well defined hyperechoic foci are seen in the liver (arrows), consistent with metastatic lesions in a patient with primary colon cancer. Additional images illustrate metastases (b and c).

Primary tumors

Hepatocellular carcinoma (HCC) is the most common primary tumor arising from the liver. HCC typically is hypoechoic (indicating solid tissue) and may be surrounded by a thin hypoechoic halo, possibly representing a capsule. However, some HCC lesions, especially larger lesions, can demonstrate mixed echogenicity or a hyperechoic appearance (Figure 8, 9 and 10). Calcification, seen as bright, hyperechoic speckling within a tumor, is rare unless there is prior treatment. HCC has been associated with invasion of the hepatic veins and inferior vena cava. Hence, vascular structures should be examined closely with real-time sonography for evidence of extension or invasion by tumor. It is helpful to determine the margins of HCC lesions, since infiltrative tumors are usually not amenable to simple surgical resection. If ultrasound is not adequate for seeing the margins, angiography, CT, or MR may be helpful for pre-surgical planning. When hepatic tumors are seen in the setting of cirrhosis, it is often difficult to differentiate HCC lesions from surrounding abnormal parenchyma.

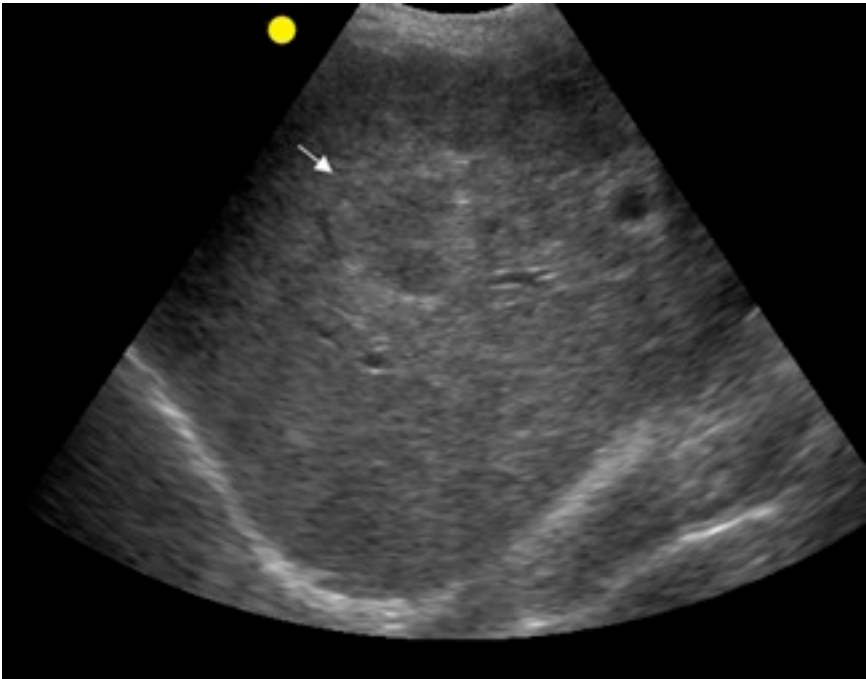


Figure 8. Hepatocellular carcinoma. This poorly defined, irregular, heterogeneous mass lesion in the liver is consistent with HCC. HCC typically is hypoechoic (indicating solid tissue) and may be surrounded by a thin hypoechoic halo possibly representing a capsule.

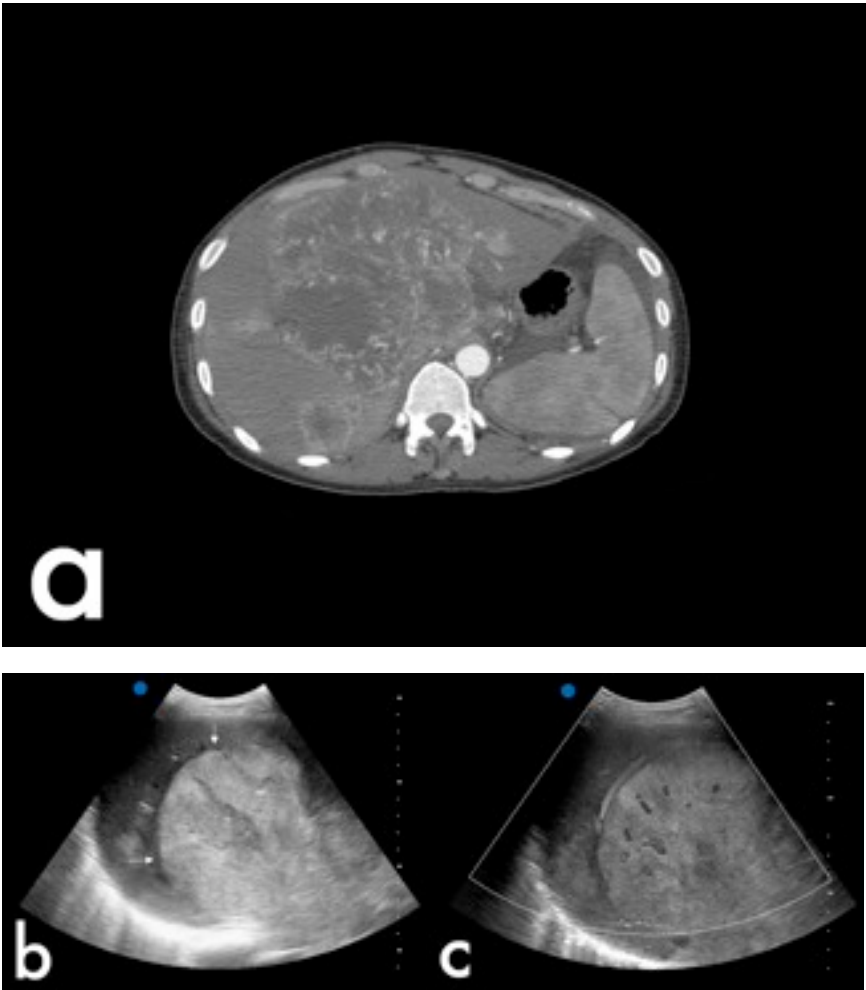


Figure 9. Large hepatocellular carcinoma. CT with contrast (a) demonstrates large heterogeneously enhancing mass in the kidney with adjacent smaller lesions – evidence of infiltration. (b) Hyperechoic lesion (arrows) with surrounding vessel and hypervascularity on Doppler (c). Larger HCC lesions can demonstrate mixed echogenicity or a hyperechoic appearance.

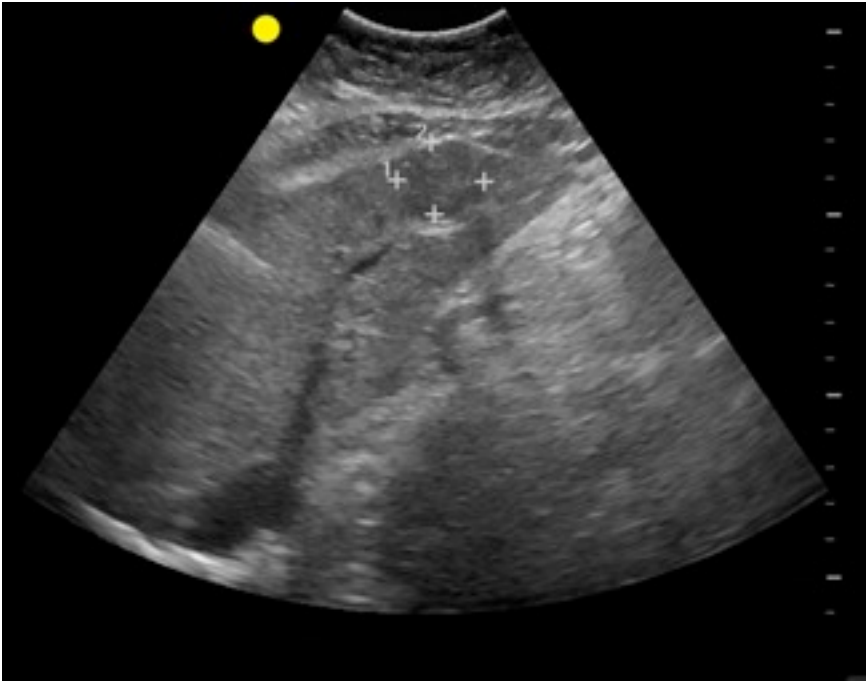


Figure 10. Hepatocellular carcinoma. Ultrasound image illustrates hypoechoic appearance of a solitary HCC outlined by the calipers.

Benign tumors

Benign tumors include hemangiomas, focal nodular hyperplasia, or hepatic adenomas. Hemangiomas are the most common benign tumor. The typical appearance is echogenic and lacks posterior acoustic shadowing (Figure 11). Usually hemangiomas are solitary but can be multiple. There is no lobar predilection.

Hemangiomas typically measure less than 5 cm, though

one can see giant hemangiomas that can measure up to 4 to 5 cm.

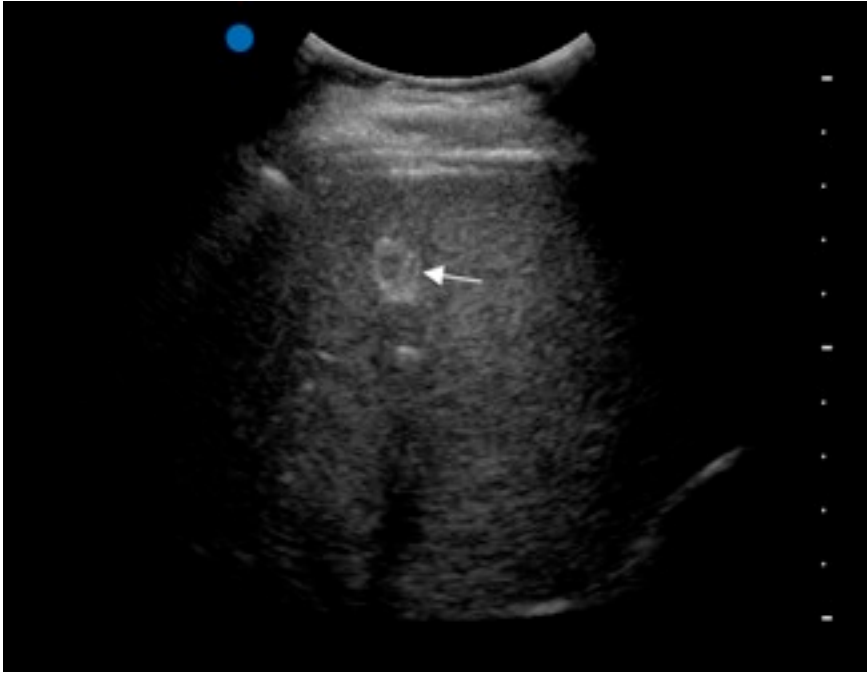


Figure 11. Hepatic Hemangiomas. Hemangiomas are the most common benign tumor. Typical appearance is echogenic, lacking posterior acoustic shadowing as demonstrated in this image.

Adenomas are another benign lesion that can be associated with use of estrogen containing oral contraceptives and are typically non-specific appearing solid lesions on ultrasound.

Focal nodular hyperplasia (FNH) is a benign lesion that is thought to occur as the result of microthrombosis of

vessels supplying the liver parenchyma and its appearance can demonstrate hyperplastic hepatic tissue along fibrous strands. Sonographically, FNH can mimic normal tissue and without mass effect, cannot be seen. FNH is usually isoechoic and homogeneous but can also be hypoechoic or hyperechoic. In the evaluation of possible FNH, mass effect is a good clue on ultrasound (Figure 12). A central scar can sometimes be seen as a typically hypoechoic focus but can be hyperechoic in a minority of patients. Calcification resulting in acoustic shadowing can also be seen within the central scar. On color Doppler, a large central feeding artery and vessels may be seen radiating peripherally giving a characteristic “spoke-wheel” pattern.

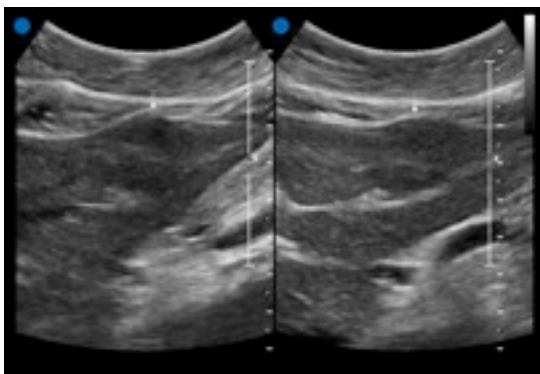


Figure 12. Focal Nodular Hyperplasia (FNH). FNH is usually isoechoic and homogeneous. Sonographically, FNH can blend in and mimic normal tissue. Key findings to observe are mass effect, such as prominence of the contour.

Hematoma & trauma

Ultrasound is useful in evaluating the liver for signs of traumatic injury. For further details regarding trauma ultrasound, please see the chapter on the FAST exam. For example, hematomas appear as irregularly shaped lesions that are initially echogenic and with time, becomes less echogenic. They are often associated with lacerations, perihepatic collections, and/or hemoperitoneum. Lacerations appear as irregularly shaped hematomas that could extend to the capsular surface (Figure 12). Due to mechanism of injury in abdominal trauma, other adjacent organs may also have related findings. Evaluation by ultrasound to exclude renal and splenic injury can also be helpful. In addition to parenchymal hematomas, subcapsular hematomas appear as curvilinear fluid collections. Parenchymal injury should suspected when one does not clearly see the normal hepatic vasculature.

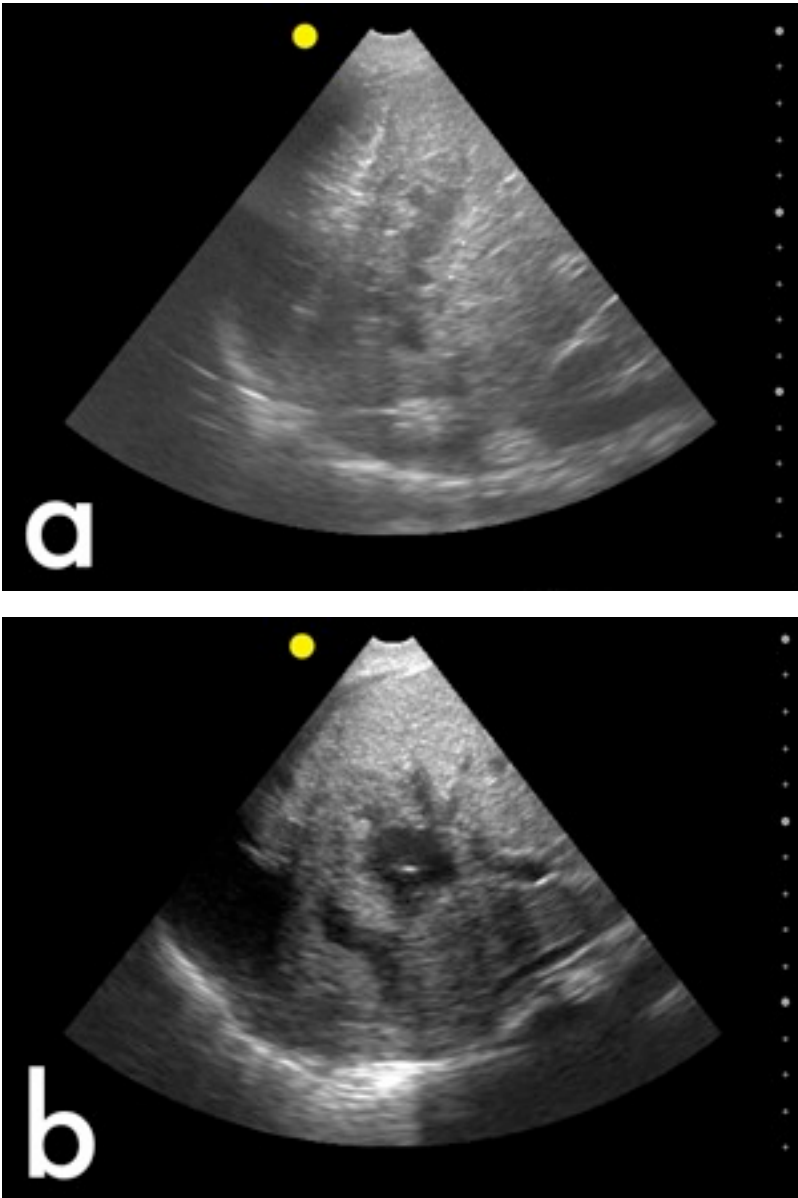


Figure 13. Hematoma with laceration due to trauma (a and b). Linear and poorly defined, irregularly shaped hypoechoic regions consistent with tissue injury, hematoma formation, and edema are seen.

Abscess

Intrahepatic abscess can be caused by bacterial, fungal, or amebic infections. Liver abscesses are highly variable in shape and echogenicity (Figure 14 and Figure 15). Abscesses may be seen as multiple clusters with or without coalescence into a larger cystic cavity. The margins may be well defined or irregular with possible thickening of the cavity wall. Additional findings that may help in identifying abscesses include fluid levels, internal debris, septa, and posterior acoustic enhancement. If gas is present within abscess cavity, echogenic foci with reverberation artifact will be seen (Figure 16). In the region of abscess lesions, surrounding hypoechoic parenchyma may be present indicating edema. Importantly, ultrasound is also useful for image guided-aspiration for treatment of liver abscess (Figure 15).

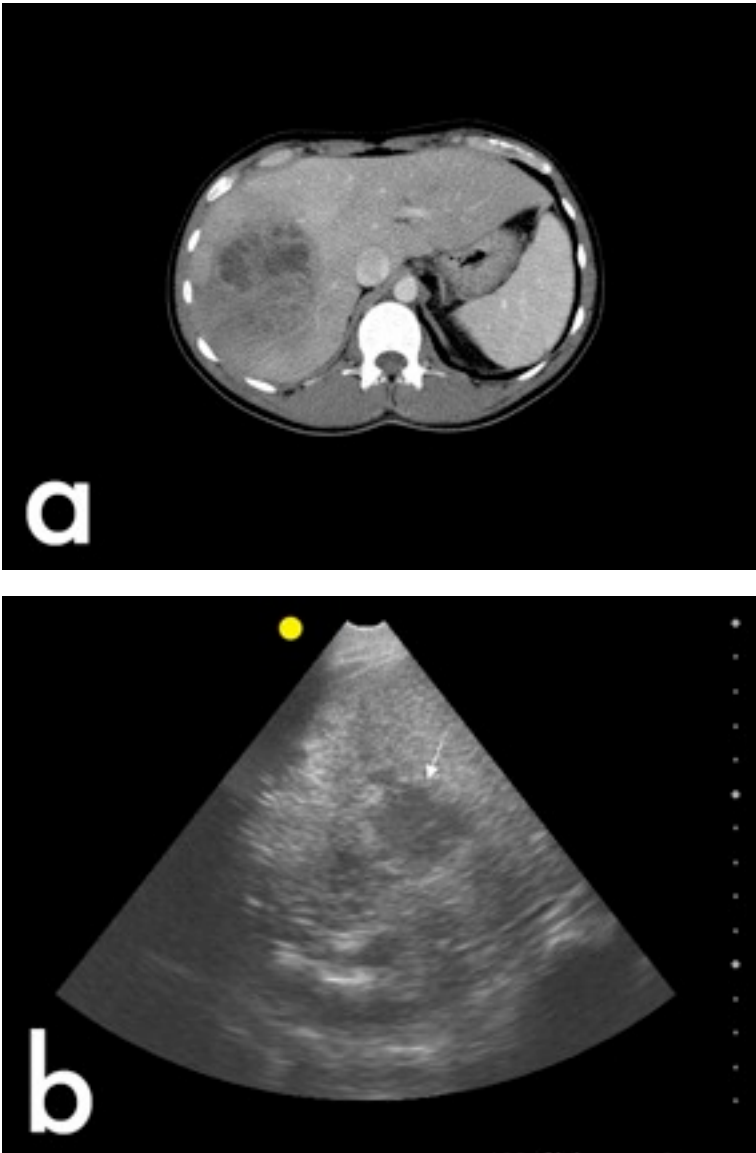


Figure 14. Pyogenic abscess. CT scan (a) demonstrates a heterogeneous low attenuation fluid collection in the liver consistent with abscess. Ultrasound (b) shows poorly marginated hypoechoic and heterogeneously appearing collection consistent with abscess.

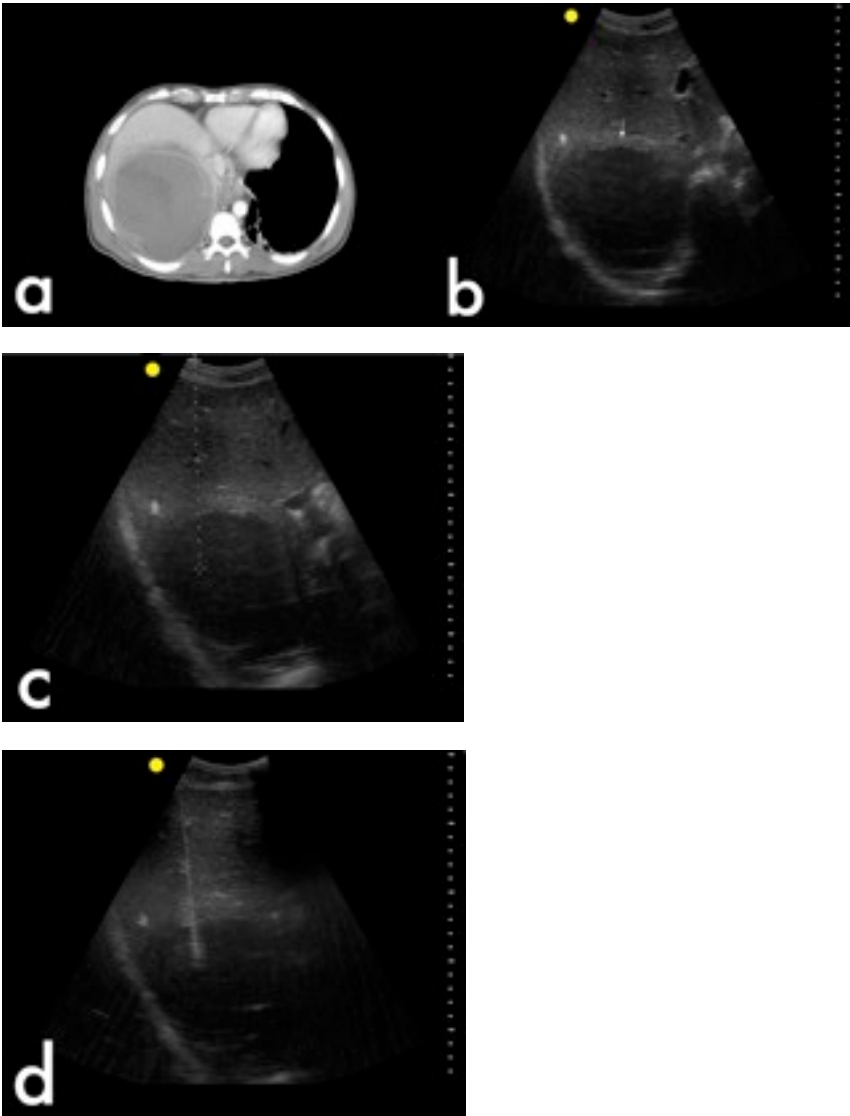


Figure 15. Amebic liver abscess. CT scan (a) illustrates large rim enhancing abscess collection with surrounding infiltration and edema. Cystic hypoechoic appearance on ultrasound (b). Pre-needle aspiration planning (c). Depth and size of lesions can be assessed for treatment. Needle entering abscess collection for percutaneous drainage (d).

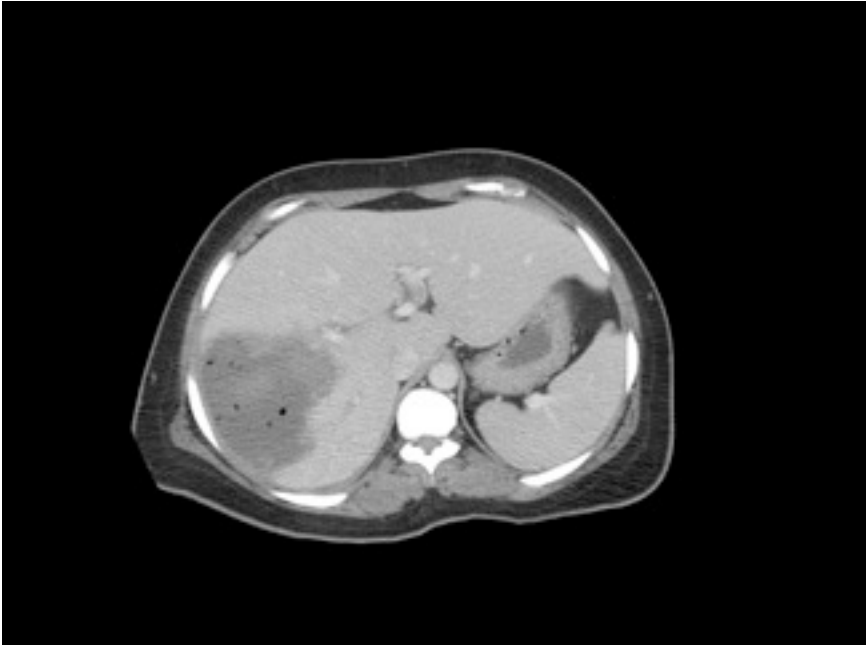


Figure 16. Abscess from gas-producing organisms. CT scan (a) illustrates a large low attenuation abscess with numerous foci of air consistent with gas-producing organisms. Ultrasound (b) demonstrates internal debris and numerous echogenic foci with reverberation artifact consistent with foci of gas seen on CT.

Hydatid Cyst

Hydatid or Echinococcal disease can also be evaluated by ultrasound. Large, well defined cystic masses with multiple peripheral daughter cysts is a hallmark appearance of this entity. Hydatid cysts tend to occur more frequently within the right lobe than the left lobe of the liver. Calcifications can also be seen lining the

cyst walls. The cysts are typically anechoic with the occasional appearance of hydatid “sand.” If the hydatid cysts result in significant mass effect, intrahepatic biliary dilatation may occur. Ultrasound can be useful in monitoring treatment with anti-hydatid therapy. Examples of positive treatment response include increasing calcification of cyst walls, reduction in lesion size, and progressive increase in echogenicity.

Granuloma

Granulomatous disease of the liver may include infection by tuberculosis or fungal organisms. In tuberculosis, the most common manifestation, the miliary form, is not visible by ultrasound. However, the most common imaging finding for TB infection is a tuberculoma that presents as either 1) a solitary hypoechoic mass that can mimic a tumor without a defined wall, or 2) an irregular hypoechoic mass with an echogenic wall in the case of tuberculous abscess. Foci of calcifications can also be present due to prior infection (Figure 17). Fungal infections can demonstrate a similar sonographic appearance. Non-infectious granulomatous disease includes sarcoidosis. In sarcoidosis, the liver may be enlarged with a

heterogeneous appearance or may demonstrate numerous scattered hypoechoic nodules.

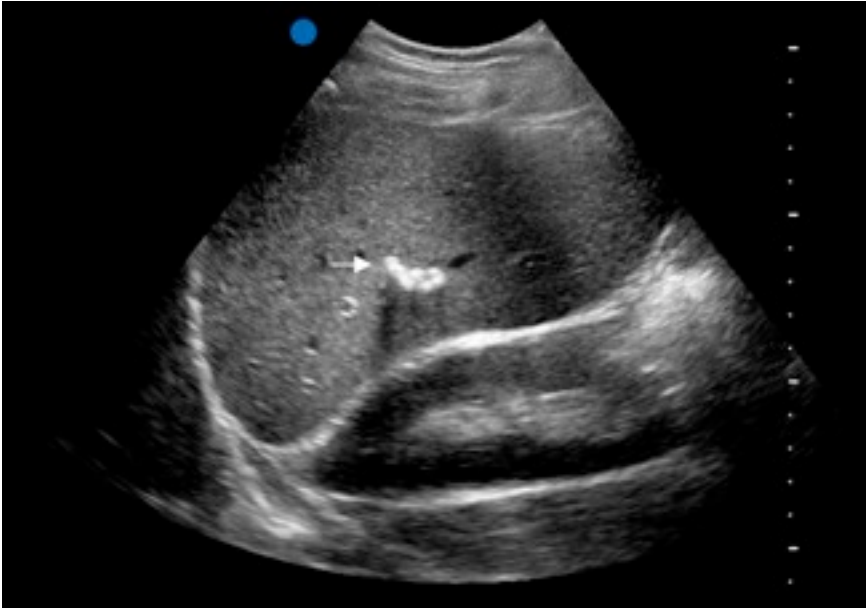


Figure 17. Calcified granuloma from prior tuberculosis infection.

Hepatitis

When hepatitis is suspected, ultrasound may demonstrate hepatomegaly and diffuse heterogeneously echogenic liver parenchyma (Figure 18). A “starry sky” appearance from increased echogenicity of the portal triad walls superimposed over a diffusely edematous liver can be seen. In chronic infectious cases, increased echogenicity of the liver and “silhouetting” of the portal

vein walls is seen. Associated findings such as gallbladder wall thickening, portal edema, and lymphadenopathy can also be seen.

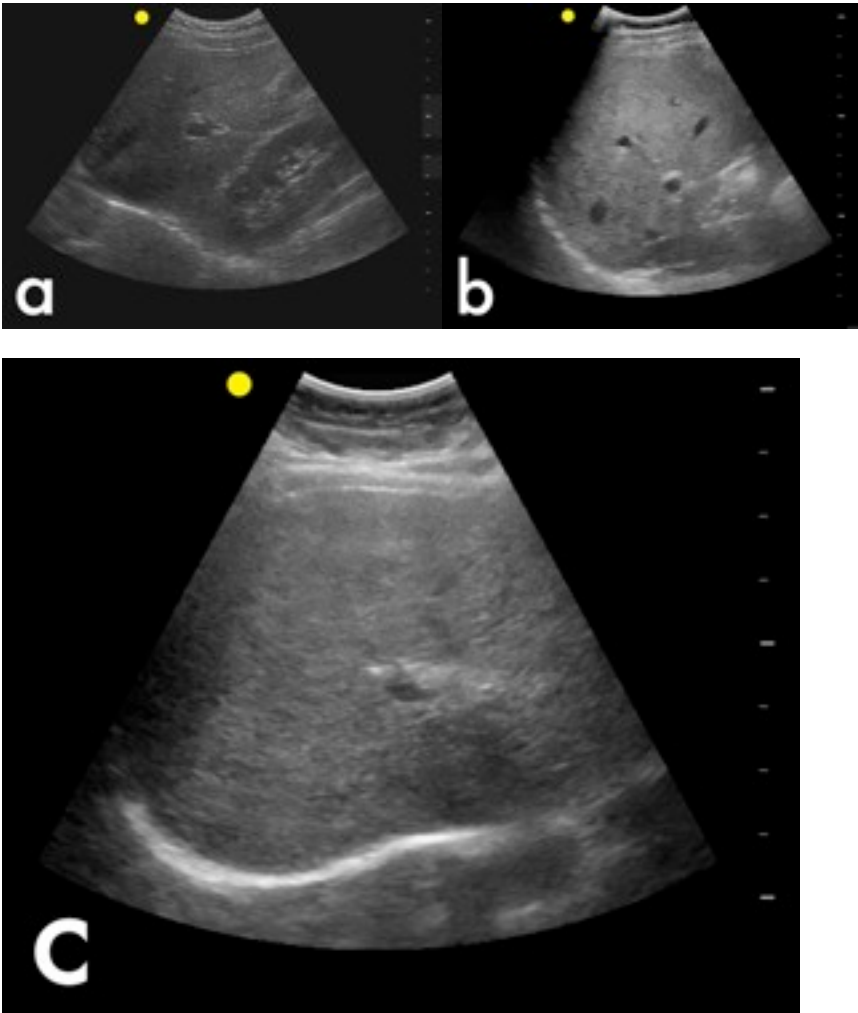


Figure 18. Acute hepatitis (a, b and c). Diffusely increased heterogeneity and echogenicity of hepatic echotexture consistent with diffuse inflammatory process from hepatitis.

Cirrhosis & portal hypertension

In cirrhosis, the liver will demonstrate both parenchymal and vascular findings. For example, cirrhotic livers demonstrate smaller than normal size, nodular contour, and relatively enlarged caudate lobes. Atrophy of the right lobe and medial segment of the left lobe can also be present. Regenerating nodules lead to diffuse heterogeneous echogenicity, as best illustrated by positioning the ultrasound transducer such that the liver and right kidney are in the same imaging plane (Figure 19).

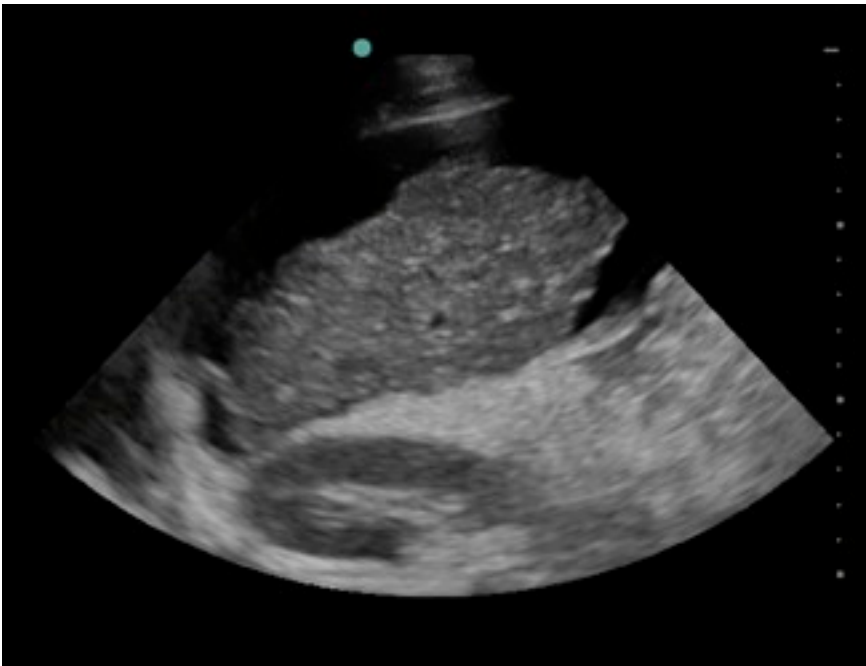


Figure 19. Cirrhosis with a small, nodular liver and ascites.

If portal hypertension is present, there may be loss of the normal triphasic Doppler waveform with increased pulsatility. Features of portal hypertension include dilatation of the hepatic, portal (> 13 mm), and splenic veins (> 11 mm). Associated findings include ascites, splenomegaly, and varices. Maneuvers that may increase sensitivity for the evaluation of portal hypertension include instructing patients to breath from quiet respiration to deep inspiration during imaging. Portal hypertension may then be suspected, if there is less than a 20-30% increase in diameter of the splenic vein or superior mesenteric vein. One the key features of advanced portal hypertension is reversal of blood flow in the portal vein, splenic vein, and superior mesenteric vein. In addition, multiple collateral vessels (from the portal to the systemic circulation) are seen.

This is a potentially reversible condition, unlike cirrhosis, which is an end stage parenchymal disease. In a cirrhotic liver, the intrahepatic vessels are difficult to trace and do not course in an orderly and straight fashion. As correlated with CT scans of liver, fatty change within the liver can be focal and irregular. Islands of unaffected “normal” parenchyma may appear as hypoechoic in comparison to surrounding affected

liver. Also, enlarged portal vein, splenic vein and superior mesenteric vein can be seen in cases with portal hypertension secondary to cirrhosis. In cirrhosis, Doppler waveforms demonstrate reduced variations and are helpful in detecting direction of flow, which is typically altered (hepatofugal) in portal hypertension.

Fatty liver

Fatty liver is a potentially reversible condition that can be seen in a variety of toxic, ischemic, and infectious insults to the liver including alcoholism. Normally, the liver is slightly more echogenic than renal parenchyma but in fatty metamorphosis, the liver texture becomes markedly more echogenic than the kidney (Figure 19). When normal major intrahepatic vessels, such as left, middle and right hepatic veins, can be identified in an echogenic liver without abnormal displacement, this is an indication of fatty metamorphosis. Hepatic steatosis can be focal with a triangular morphology or segmental distribution. The most common locations of fatty infiltration include the right lobe, caudate lobe, pericholecystic, and periportal regions.

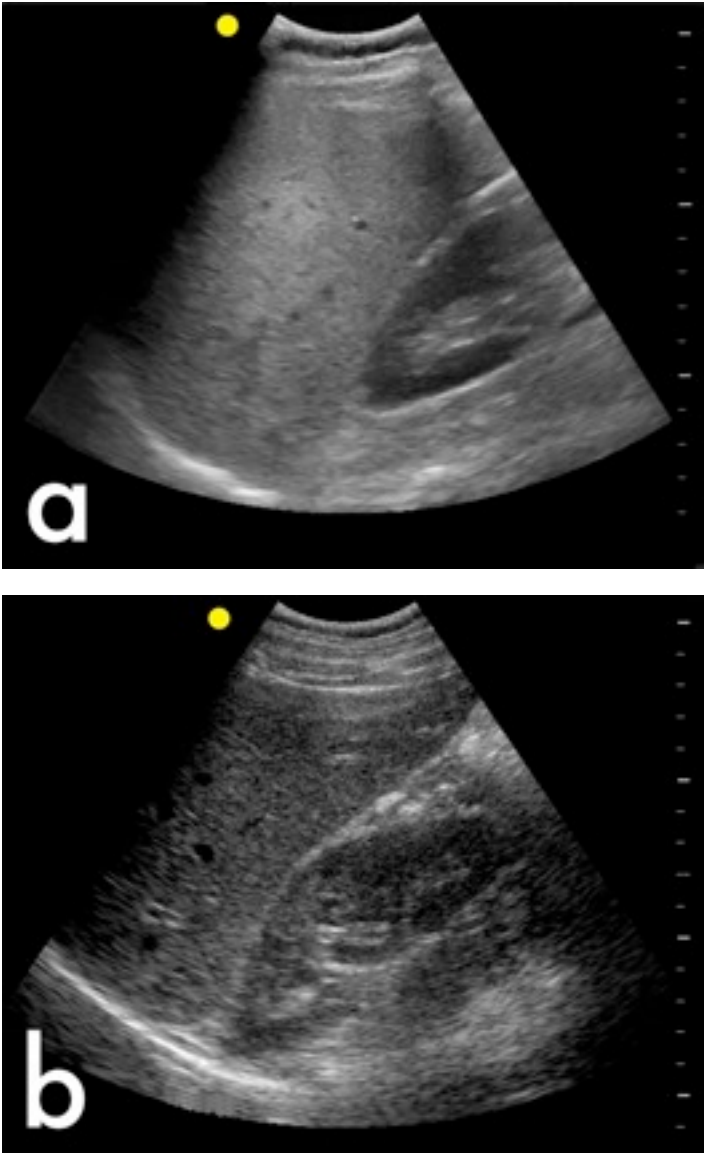


Figure 20. Diffuse fatty infiltration (a). Compared to renal parenchyma, there is a significant diffuse increase in echogenicity of the liver parenchyma consistent with fatty infiltration. Normal liver (b) as comparison.

Budd-Chiari Syndrome

Budd-Chiari syndrome is a clinical entity characterized by obstruction of hepatic vein outflow. In the acute setting, hepatic veins will appear distended (Figure 21) with absent flow, reduced velocity, reversed flow, or even intraluminal echogenic material (thrombus).

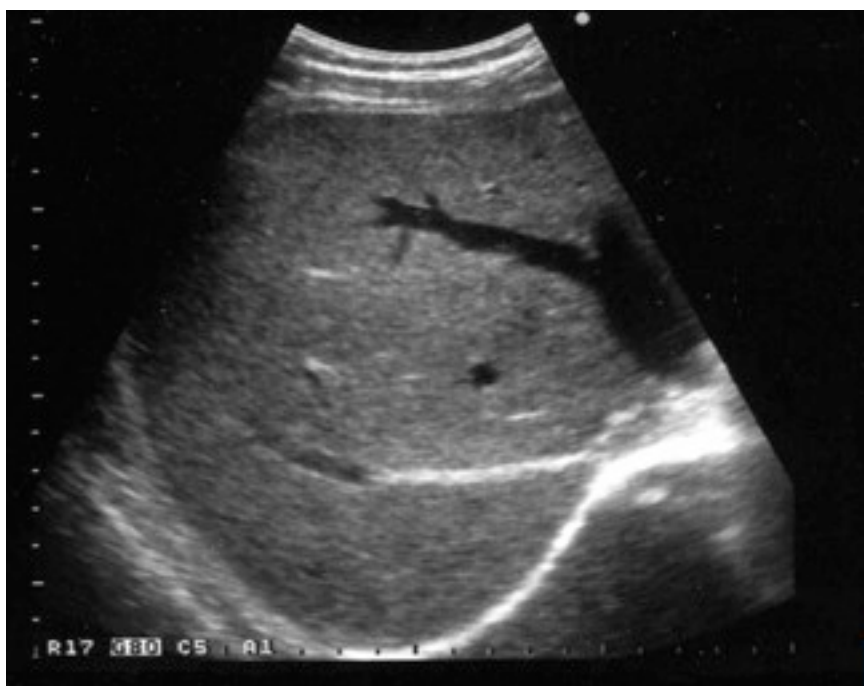

Figure 21. Distended hepatic veins in a case of Budd-Chiari Syndrome

Associated edema in the liver (patchy heterogeneous hepatic echotexture) can also be seen acutely. Over time, chronic changes that may be seen on ultrasound

include stenosis and occlusion of the hepatic veins, inferior vena cava and collateral vasculature.

Technique

Use a curved or phased array probe to visualize the maximal extent of the liver, although it is often common to not see the entire liver on a single image. As with standard convention, the probe marker should always point to the patient's head or the patient's right side.

Visualizing the liver

The echo pattern of the liver should be homogeneous and slightly brighter (more echogenic) than the spleen. It should also be equal in echogenicity to the adjacent kidney. The diaphragm appears on ultrasound as a bright (echogenic) line outlining the superior margin of the spleen and liver. The liver is best visualized with the patient supine or in the left lateral decubitus position. The probe should be positioned in the subcostal oblique position (Figure 22), with instruction to the patient to take a breath in order to inferiorly displace the liver for a better scan window.

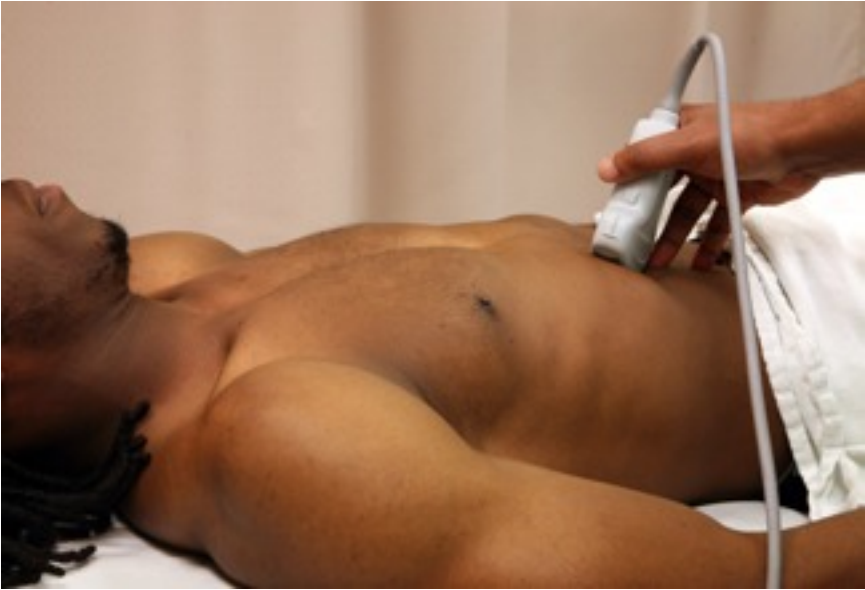

Figure 22. Subcostal view to best visualize the maximal extent of liver.

Additionally, another view in the left lateral decubitus view can be obtained for a coronal image (Figure 23). Views should be obtained both between and below the lower ribs in order to best assess hepatic parenchyma, intrahepatic biliary ducts, gallbladder, hepatic veins, and portal veins. Rotate the probe as necessary to allow both longitudinal and oblique subcostal and intercostal views.

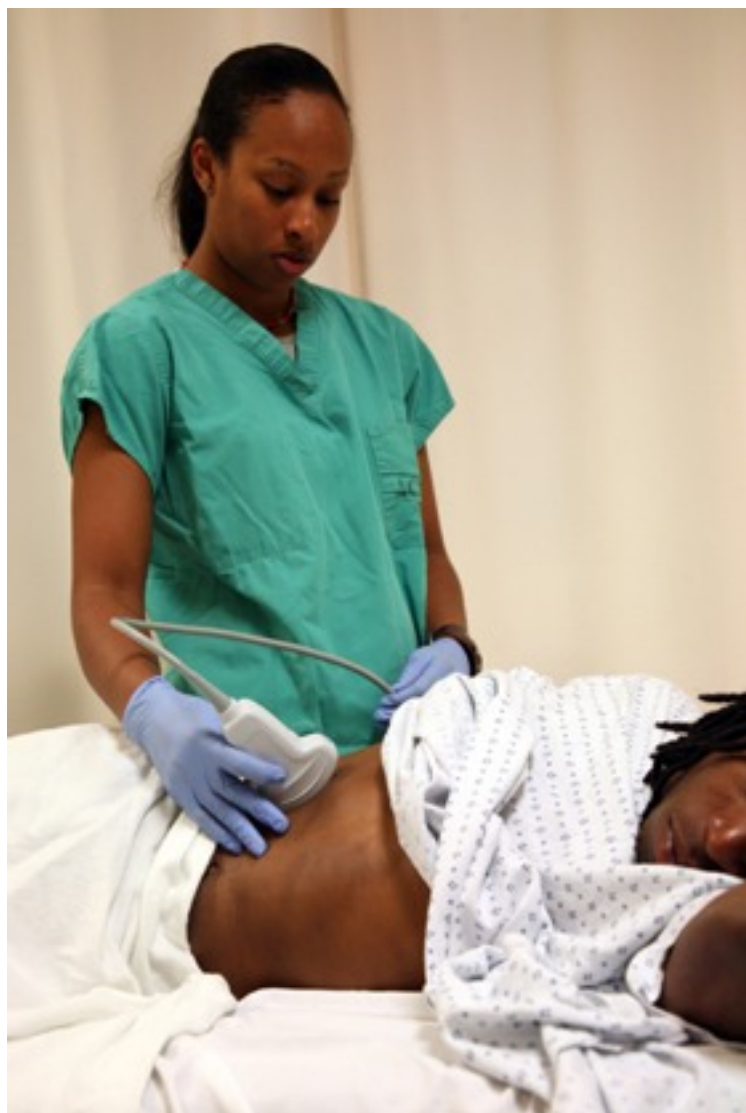

Figure 23. Coronal view with patient in the left lateral decubitus position.

Hepatic and portal veins, hepatic arteries, and intrahepatic biliary ducts

The hepatic veins run in an oblique plane with confluence superiorly at the IVC. The portal veins run in a horizontal plane along with the hepatic arteries. Imaging with Color Doppler can best be used to assess for patency to exclude portal vein thrombosis or tumor invasion. Color Doppler may be used to differentiate the hepatic arteries, hepatic veins, and intrahepatic biliary ducts. In fact, in the case of suspected obstruction of the intrahepatic biliary system, or an enlarged common bile duct, Color Doppler must be used to exclude normal vascular structures.

Conclusion

Liver ultrasound can provide valuable information regarding several commonly encountered conditions in patients suffering from infection, malignancy and trauma.

Recommended reading

1. Halpert RD. *Gastrointestinal Radiology*. St. Louis: Mosby Publishing, 1999.
2. Gore RM and Levin MS. *Textbook of Gastrointestinal Radiology*, 3rd edition. Amsterdam: Elsevier Publishing, 2008.

Gallbladder

ARUN NAGDEV MD

Introduction

Health care providers worldwide have to evaluate patients with undifferentiated abdominal pain. The decision to discharge patients with clear return precautions or proceed to further radiographic imaging can be difficult, even for experienced physicians.

Bedside ultrasound, used as an extension of the physical exam, can be a powerful tool to determine the presence of biliary pathologies, and direct the clinician to further imaging and/or consultation. Ultrasound of the gallbladder should be considered in patients presenting with complaints of epigastric, right sided abdominal or flank pain, fever without a source, or jaundice.

Cholelithiasis

Ultrasound is a sensitive test for detecting gallstones. Bedside sonography performed by non-radiologists with moderate training has been shown to be highly accurate as compared to “comprehensive” ultrasound studies. Almost all cholecystitis is caused by gallstones, and beginning sonographers should spend most of their effort in becoming comfortable detecting or excluding cholelithiasis. Acalculous cholecystitis occurs in less than 5-10% of cases of gallbladder disease, and is extremely rare in the out-of-hospital setting. Acalculous cholecystitis most often occurs in post-operative patients with multi-organ failure or on intravenous nutrition.

Determining the location of gallstones in the gallbladder can be useful in determining the probability of cholecystitis and progression to further disease. After visualizing the gallbladder in a longitudinal view, the porta hepatis should be identified when possible, as illustrated in Figure 1. The porta hepatis includes the portal vein, the hepatic artery and the common bile duct.

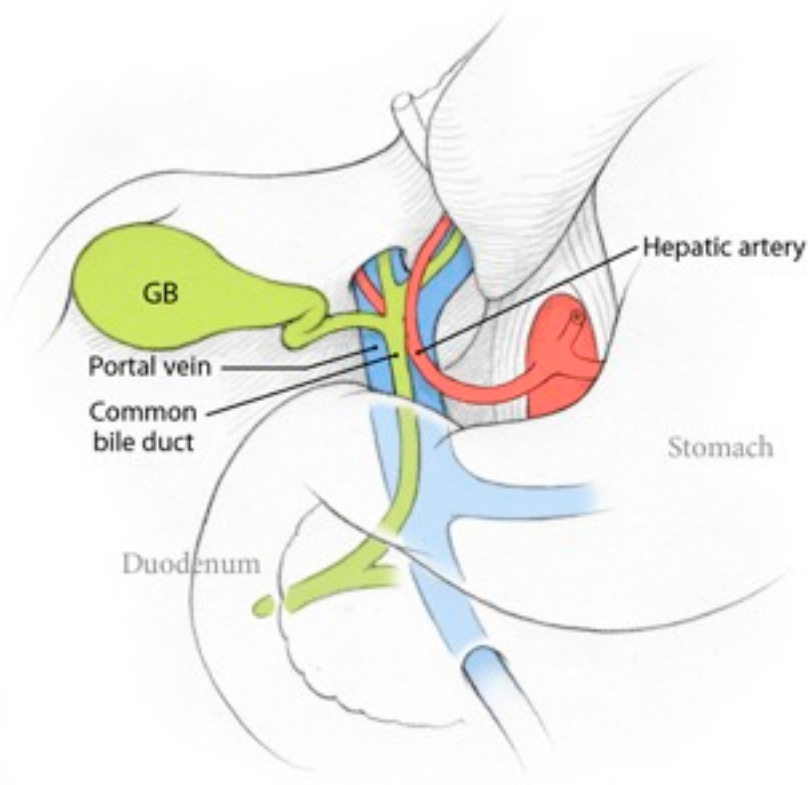


Figure 1. The porta hepatis includes the portal vein, hepatic artery and the common bile duct.

Ideally, a longitudinal view of the gallbladder should include the neck distinct from the portal circulation. Stones that are impacted in the neck of the gallbladder can cause unremitting biliary colic and indicate patients at increased risk of progressing to cholecystitis.

If the gallbladder is not clearly visualized, the clinician should not make decisions based on their findings.

Ultrasound findings

- Gallbladder with stones in fundus (Figure 2) —
Commonly seen when scanning the right upper quadrant, gallstones produce anechoic or hypoechoic shadows and are mobile when the patient changes position.

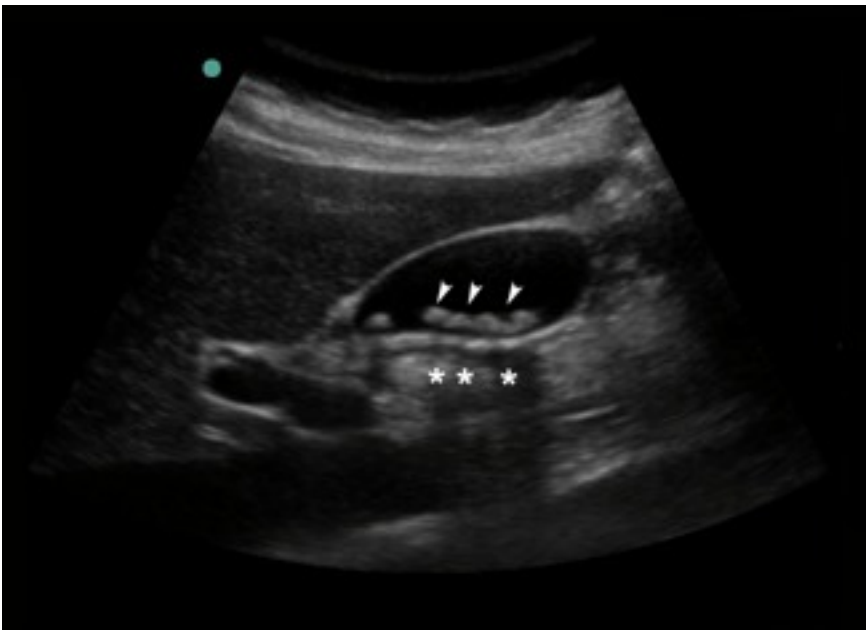

Figure 2. Stones (arrowheads) casting shadows (*) in the fundus of the gallbladder

- Gall stones in the neck (Figure 3) — A more subtle finding that can indicate a more severe process, stones in the neck of the gallbladder are indicated by an anechoic or hypoechoic shadow in the region of the gallbladder adjacent to the porta hepatis.

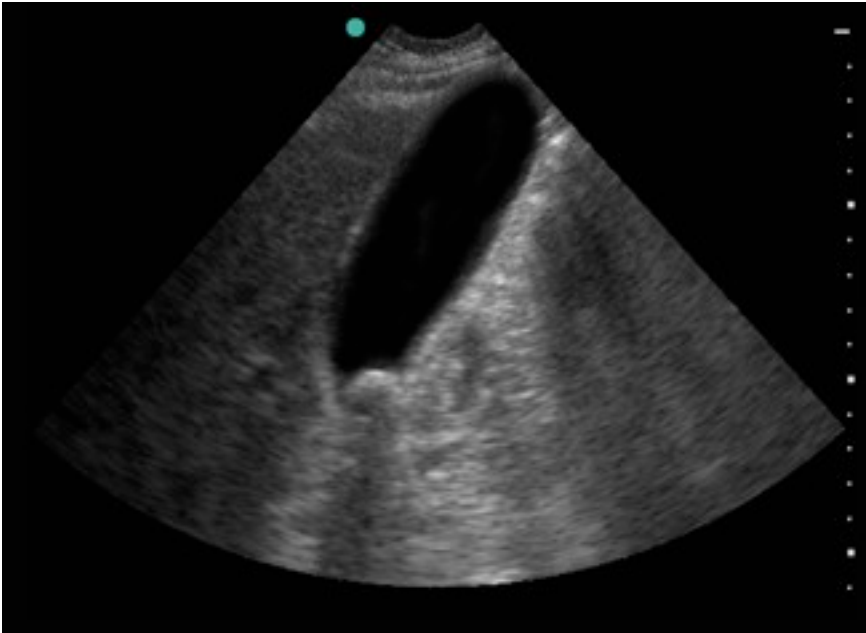


Figure 3. Gallstones in the neck of the gallbladder

- False positive polyps (Figure 4) — A false positive finding that can be confusing for the beginning sonographer, polyps are characteristically hyperechoic or isoechoic lesions that do not shadow or move with the patient.

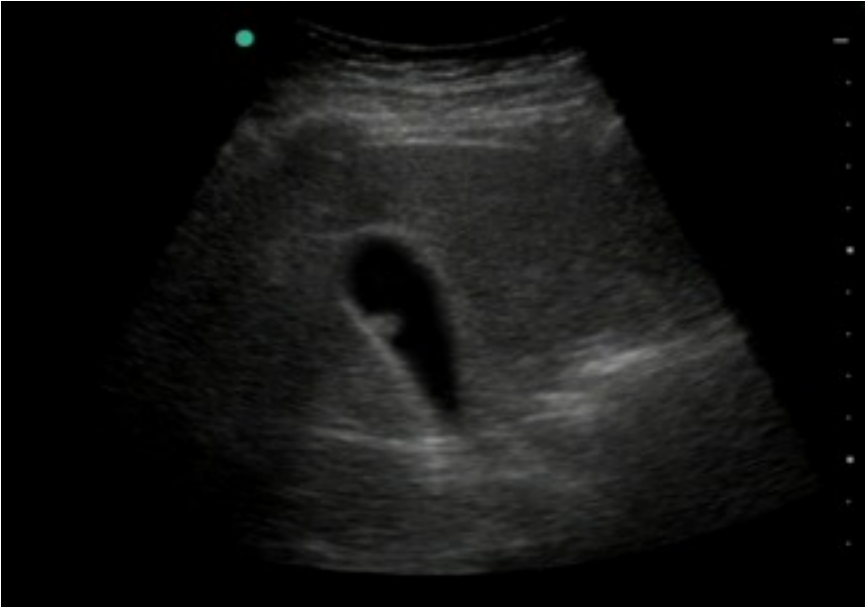

Figure 4. False positive gallbladder polyp

- False positive bowel gas shadow (Figure 5) — A common false positive finding produced by bowel laying next to the gallbladder, shadowing caused by gas is more commonly seen when the gallbladder is scanned with the patient in supine position. This finding can confuse experienced sonographers. Looking for movement (peristalsis) of the shadow, or the loss of shadow when placing the patient in the left lateral decubitus position, can help differentiate true from false gallstone shadows. Unlike an anechoic shadow from a gallstone, shadows produced by bowel

gas are mixed (isoechoic and anechoic) and have increased scatter.

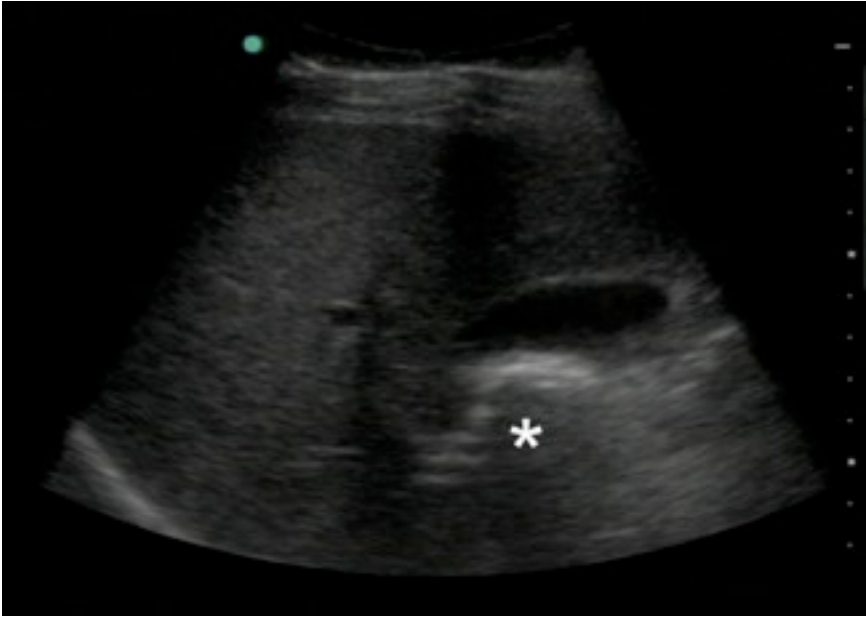

Figure 5. Bowel wall shadow (*) can be a false positive.

- Wall Echo Shadow sign (Figure 6) — In the Wall Echo Shadow Sign, the gallbladder is filled with stones which appear as a large shadow. It is commonly mistaken for either bowel gas or a rib shadow. Differentiation can be difficult, but unlike bowel gas, there is no peristalsis, and no scatter artifact that is common when ultrasound waves hit air.

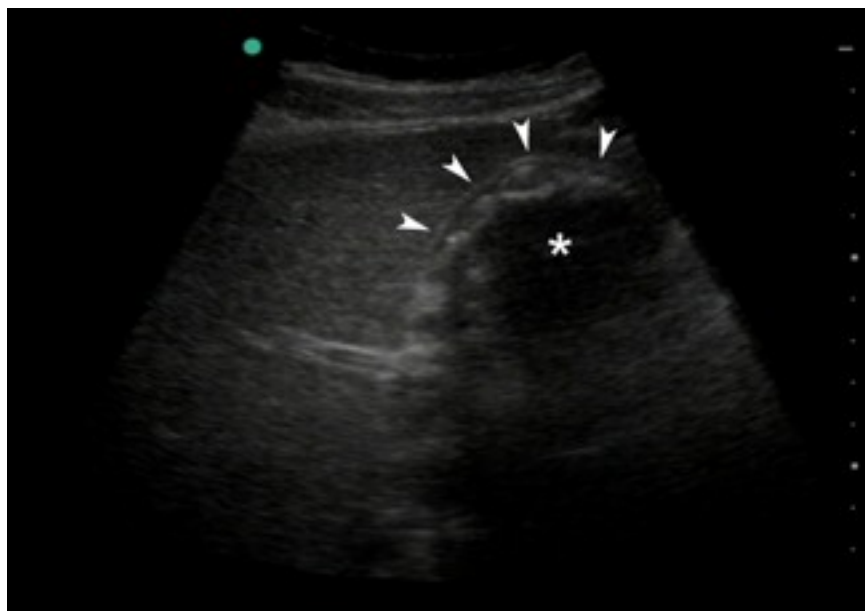

Figure 6. Wall Echo Shadow sign with arrowheads indicating the gall bladder wall and the * indicating the shadow of the stones

Cholecystitis

Abdominal pain secondary to gallbladder disease is a common ailment worldwide. The classic presentation of colicky right upper quadrant pain after a fatty meal is not always present. Patients often have insidious presentations that can easily be confused with other abdominal, cardiac and even pulmonary pathologies. Bedside ultrasound, in conjunction with clinical and laboratory data, can increase diagnostic certainty. Once

gallstones are detected, the presence of secondary signs, such as a sonographic Murphy sign, thickened gallbladder wall and pericholecystic fluid, should be determined.

Ultrasound findings

- Thickened gallbladder wall (Figure 7) — Measurement of the gallbladder wall should be in the plane of the ultrasound beam. The upper limit of gallbladder wall thickness is 3-4 mm. Inflammation of the gallbladder causing thickening of the wall can be seen in other common conditions, such as hepatitis, ascites, congestive heart failure, and protein losing nephropathies.

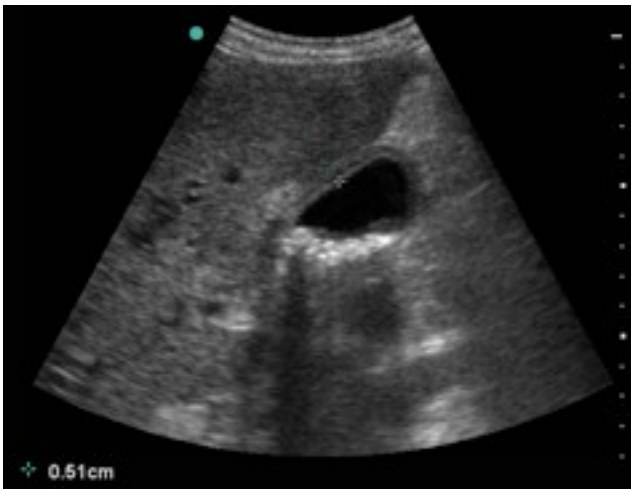


Figure 7. Gallbladder wall thickening measured with calipers

- Pericholecystic fluid (Figure 8) — Anechoic or hypoechoic fluid secondary to gallbladder inflammation is another sign of cholecystitis.

Pericholecystic fluid may also be seen in patients with third spacing of fluid secondary to increased hydrostatic pressure (e.g. congestive heart failure) or decreased oncotic pressure, (cirrhosis, protein losing nephropathy, etc.). In the right clinical setting, the presence of pericholecystic fluid is a suggestive sign for cholecystitis.

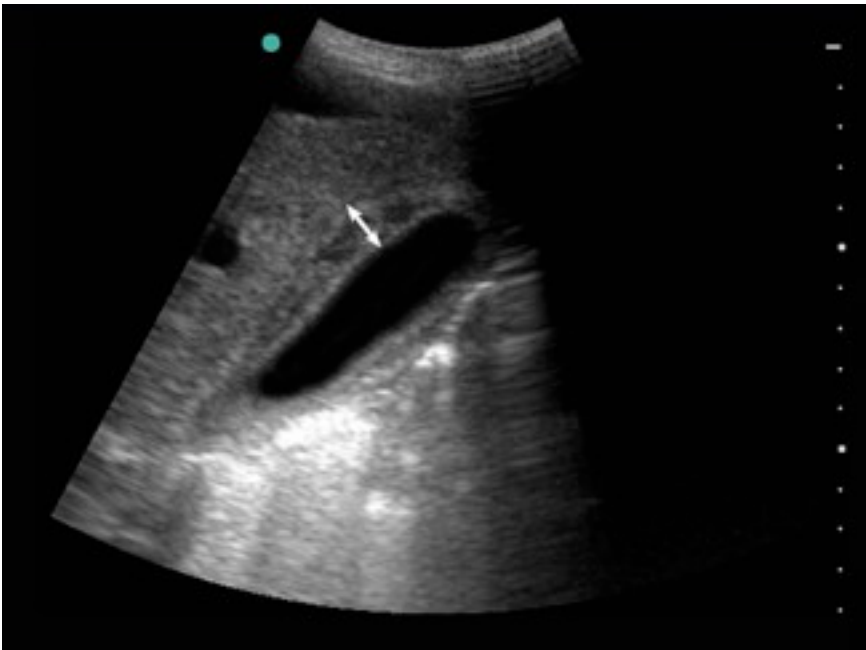


Figure 8. Pericholecystic fluid appears as a hypoechoic stripe or patch outside the gallbladder wall (arrow).

- Sonographic Murphy sign — Maximal tenderness caused by gentle pressure with the ultrasound probe over the gallbladder in the Sonographic Murphy Sign. This test has shown moderate sensitivity (up to 86%) and has been shown to be predictive of cholecystitis in emergency ultrasound studies.

Biliary obstruction

Determination and localization and of biliary obstruction is the most challenging aspect of right upper quadrant ultrasound examination. Because of the difficulty in finding and measuring the common bile duct, this exam requires more training than recommended for general detection of gallbladder pathology.

The sonographer should identify the porta hepatis with the gallbladder in a longitudinal section, as shown in Figure 9. The portal vein is generally larger and sits below both the common bile duct and hepatic artery.

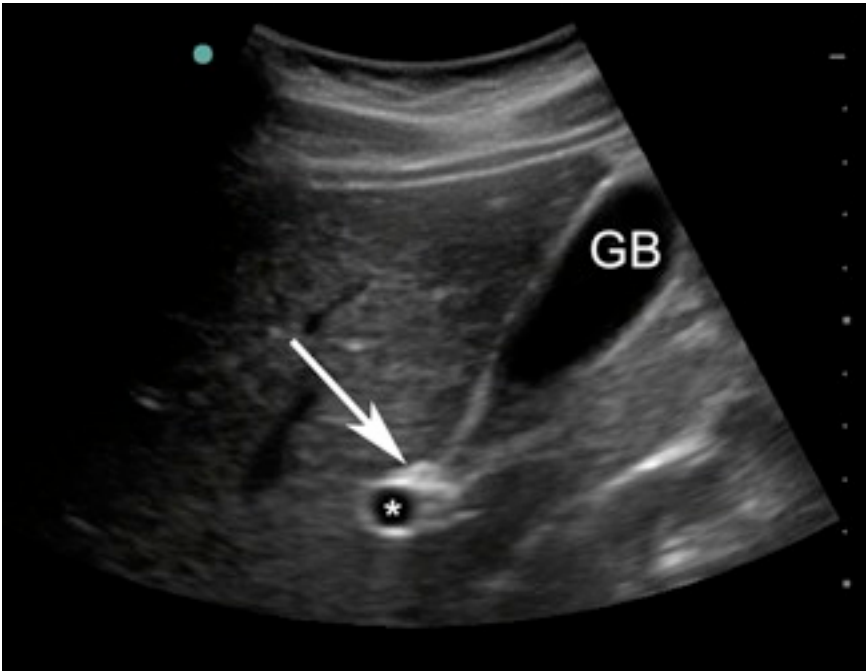


Figure 9. The porta hepatis composed of the gallbladder (GB), the portal vein (*), and the common bile duct (arrow)

It may help to perform the exam with the patient in left lateral decubitus position, as shown in Figure 10.

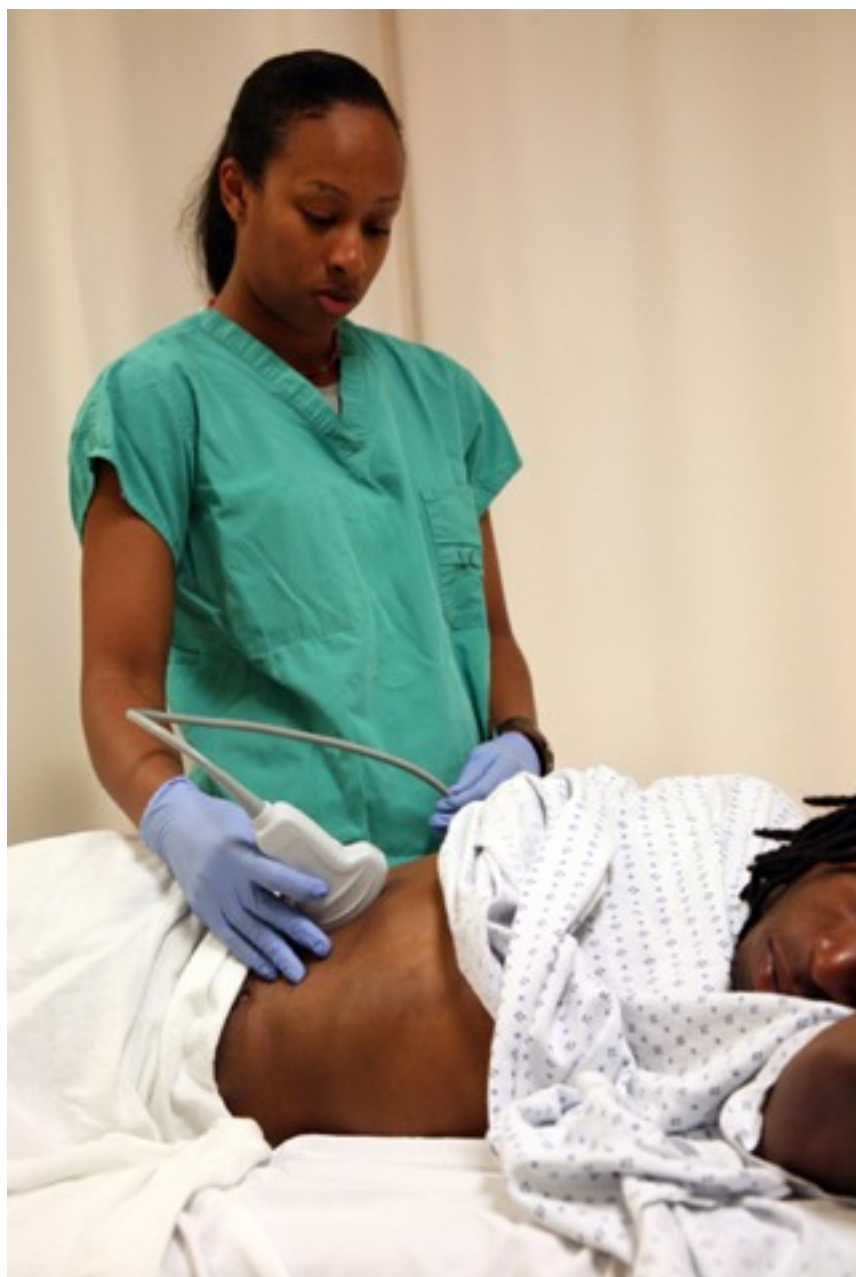

Figure 10. Left lateral decubitus position for gallbladder scan

After the porta hepatis is identified, rotate the probe 90 degrees to identify the porta hepatis in a longitudinal orientation. Normally, the portal vein is the largest vessel in the porta hepatis, with the common bile duct and hepatic artery sitting just above. Color Doppler can aid in differentiating the portal vein, the hepatic artery and common bile duct (Figure 11). The common bile duct will show no flow and be the under 8mm in diameter.

The common bile duct is often difficult to locate and measure rapidly. Evaluate the porta hepatis, and specifically look for the portal vein and common bile duct. If two large tubular vessels are noted, the common bile duct can be further evaluated and measured, again correlating with clinical and laboratory findings (liver function tests). Obstructive pathology of the biliary circulation is common and, with practice, can be detected with bedside ultrasound.

Ultrasound findings

Dilated common bile duct (Figure 11) — Evaluation of the common bile duct is often-difficult for novice sonographers. It is a large vessel running above the portal vein, noticed when evaluating the porta hepatis.

The upper limit of normal is 6-8 mm. The sonographer can use the color flow Doppler to differentiate between the common bile duct, which shows no flow, and the portal vein and hepatic artery, which demonstrate high flow (Figure 11). Laboratory and clinical correlation are necessary.

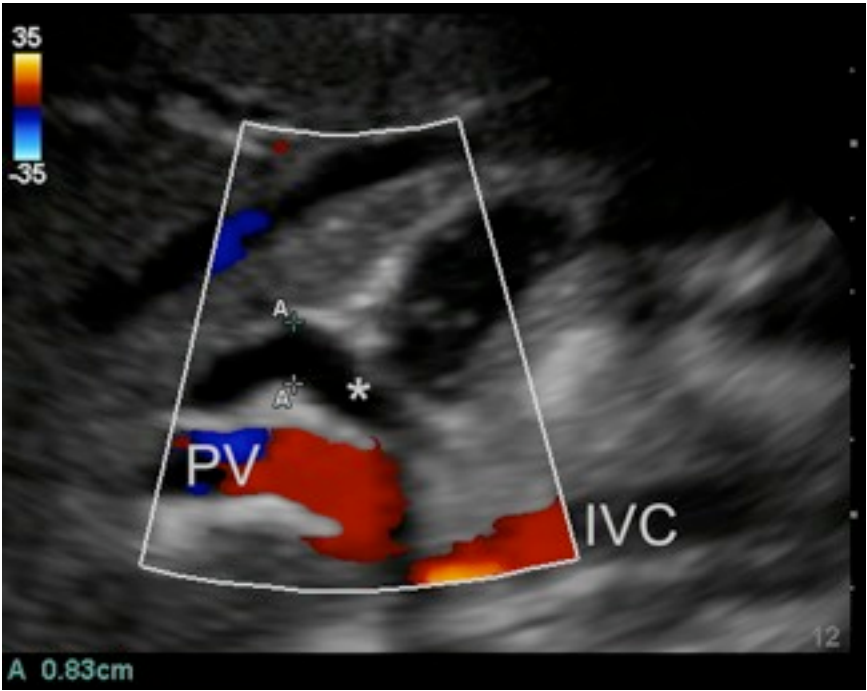


Figure 11. A dilated common bile duct (*) is measured with calipers. Doppler shows flow in the portal vein (PV) and inferior vena cava (IVC).

Technique

Use the curved transducer (Figure 12) to evaluation the gallbladder.

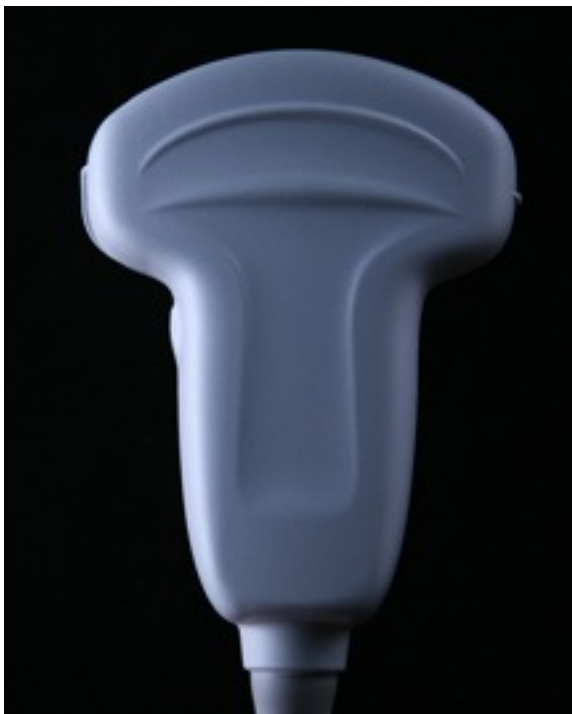

Figure 12. Curved transducer

The gallbladder should always be scanned in two perpendicular planes. This can be challenging, since the gallbladder does not lay in a classic longitudinal or transverse orientation. The location of the gallbladder is generally under the right costal margin. Bowel can make

this exam difficult for novice sonographers, using the liver as an acoustic window may help. Either place the probe with the marker facing the patient's right shoulder at the costal margin, or start in the same manner as the Morison's pouch view in the trauma FAST exam and move in a medially (above the costal margin) until an anechoic, fluid filled structure is found (Figure 13).

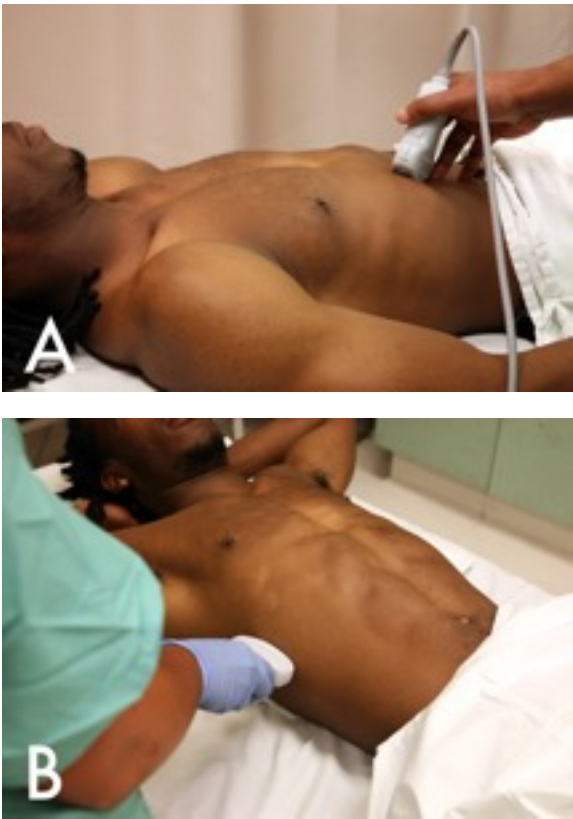

Figure 13. Probe position for the costal margin view starting at Morison's pouch (A) and moving medially to the epigastrium (B)

If the structure is not found with this technique, place the patient in the left lateral decubitus position and rescan the supracostal margin from lateral to medial.

There are several particular instances in which the gallbladder can be difficult to locate. When the gallbladder is completely filled with gallstones, the classic anechoic fluid-filled gallbladder is replaced with shadow that appears to originate from within the liver, but is actually a shadow produced by gallstones tightly packed inside the gallbladder. This is known as the Wall Echo Shadow Sign (Figure 6). This can be difficult for novice sonographers and can be confused with rib or bowel shadow. The clinician must note the origin of the shadow — from within the liver or more superficial.

Bowel gas can be differentiated by keeping the probe over the affected area and attempting to visualize peristalsis. The patient should be scanned in both the supine and left lateral decubitus positions to ensure that a similar image is obtained.

When the gallbladder is completely contracted after a meal, ultrasound can be difficult. For comprehensive outpatient studies, patients are asked to fast before the exam to allow for gallbladder distention and adequate

visualization. Fortunately, patients who have acute cholecystitis are usually unable to eat large meals before presenting for evaluation due to pain. The contracted gallbladder is usually difficult to localize and the wall will appear thickened. A contracted gallbladder is unlikely to be the cause of the patient's pain. Placing the patient in the left lateral decubitus position can allow for better visualization by moving bowel gas out of the way.

Step by step approach

1. Place the curved transducer above the costal margin at the anterior axillary line on the right chest with the probe marker pointed to the patient's right shoulder.
2. Slide the ultrasound probe from the lateral to medial aspect of the costal margin and identify the liver and its vasculature.
3. If the gallbladder cannot be found, place the patient in the left lateral decubitus position. This position is optimal for gallbladder imaging, but it may not be feasible in all patients.
4. Look for a large fluid-filled sac in the liver parenchyma. It appears as a hypoechoic structure surrounded by a hyperechoic wall. Be careful not to

mistake the inferior vena cava or other vascular structure for the gallbladder.

5. Once the gallbladder is identified, obtain a longitudinal view by rotating the probe in a clockwise manner until a clear view of the entire gallbladder is obtained. Fan the probe along the longitudinal axis of the gallbladder to image the entire gallbladder in a longitudinal plane.
6. Rotate the probe 90 degrees until a transverse view of the gallbladder is obtained. Fan through the gallbladder to examine the entire organ. Gallstones will appear hyperechoic with an anechoic or hypoechoic shadows, as seen in Figure 14.

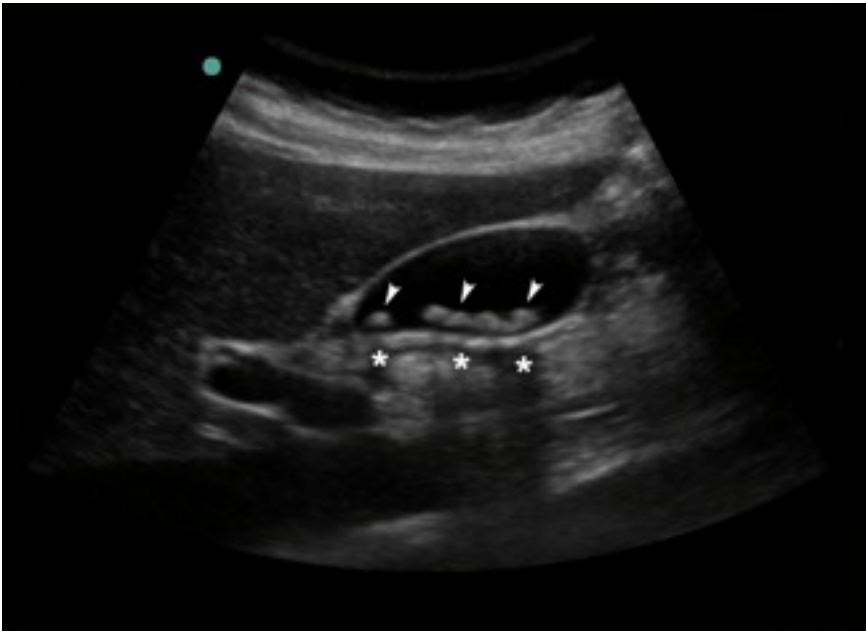

Figure 14. Gallstones (arrowheads) appear hyperechoic with anechoic shadows (*)

7. Once the gallbladder is completely evaluated for stones, search for secondary signs of biliary disease.
8. With the gallbladder in a transverse plane, measure the wall closest to the probe. Use the depth and zoom functions of the ultrasound machine to obtain the best image and reduce error. The gallbladder wall should be less than 3-4 mm.
9. To measure the common bile duct, place the patient in the left lateral decubitus position (Figure 10).

Obtain a longitudinal view of the gallbladder showing the porta hepatis (portal vein, hepatic artery and common bile duct). The portal vein is usually the largest structure and lays at the bottom of the gallbladder neck. The common bile duct and the hepatic artery lie on top of the portal vein. Rotate the probe 90 degrees, so the porta hepatis is in a longitudinal orientation. Using color Doppler, the common bile duct will show no flow, indicated by the lack of color. The portal vein will be the large tubular structure. If another large tubular structure is seen, it is most likely the common bile duct. The duct should be measured by placing the calipers on inside margin of the anterior wall (nearer the top of the screen) and the inside margin of the posterior wall. The zoom function helps identify the location of the common bile duct wall edges, which can be difficult.

Conclusions

Assessment of abdominal pain can be challenging for even the most seasoned clinician. Incorporating ultrasound into patient evaluation can aide the clinician in determining the presence of biliary colic, cholecystitis and biliary obstruction. Unfortunately, the gallbladder

may lay in various locations, making the evaluation difficult for the novice sonographer. A standard stepwise approach, relying on anatomic landmarks, can allow the clinician to combine ultrasound findings with physical exam and laboratory results to determine if the cause of the pain is biliary in origin.

Recommended reading

1. Rosen CL, Brown DF, Chang Y, et al. Ultrasonography by emergency physicians in patients with suspected cholecystitis. *American J Emerg Med* 2001;19:32-6.
2. Ralls PW, Halls J, Lapin SA, et al. Prospective evaluation of the sonographic Murphy sign in suspected acute cholecystitis. *J Clin Ultrasound* 1982;10:113-5.
3. Miller AH, Pepe PE, Brockman CR, et al. ED ultrasound in hepatobiliary disease. *J Emerg Med* 2006;30:69-74.
4. Kendall JL, Shimp RJ. Performance and interpretation of focused right upper quadrant ultrasound by emergency physicians. *J Emerg Med* 2001;21:7-13.

Spleen

TERI REYNOLDS MD

Introduction

Abnormalities of the spleen are associated with many diseases endemic to tropical areas. Ultrasound can help diagnose both an enlarged spleen (splenomegaly) and specific splenic abnormalities (focal lesions), such as abscesses, cysts, or other masses. Ultrasound also allows measurement of the splenic vein, which can provide information about portal hypertension in liver disease.

Indications for ultrasound of the spleen include:

- Splenomegaly on physical exam
- Inflammatory conditions
- Suspected protozoal infection (especially malaria and leishmaniasis)

- Chronic liver disease and suspicion for portal hypertension

Splenomegaly

Splenomegaly can be a sign of infection or inflammation from many diseases, and may also be caused by hematologic disease or the portal hypertension associated with liver disease.

Inflammatory splenomegaly

Splenomegaly is a non-specific marker of inflammation and can be associated with many different conditions. It may be seen in acute or chronic infections and is very common in fungal and protozoa diseases. Since the actual appearance of the spleen is the same in many different disorders, splenomegaly may not help diagnose a specific disease, but can support the diagnosis of a systemic infectious disease. Hepatosplenomegaly with increased skin pigmentation (kala-azar), however, usually indicates visceral leishmaniasis caused by *Leishmania donovani*. Specific lesions associated with tuberculosis and fungal infections are discussed below in

the “Focal lesions” section. Infectious conditions causing splenomegaly include:

- Tuberculosis
- Trypanosomiasis (Chagas disease)
- Leishmaniasis (kala-azar)
- Malaria
- Schistosomiasis
- Hydatid disease
- Clonorchiasis
- Toxoplasmosis
- Acute cytomegalovirus
- Fungi, especially histoplasmosis

Tropical splenomegaly

An important condition very common in regions where falciparum malaria is endemic, tropical splenomegaly may be a result of chronic exposure to malaria and may not reflect acute disease. In areas where tropical splenomegaly is common, the implications of splenic

enlargement may be unclear, though an acute increase in spleen size may be more useful. A more specific condition called “idiopathic tropical splenomegaly” is a defined by a combination of:

- splenomegaly
- elevated IgM levels
- secondary coagulopathy
- absence of another cause

The number of cases of splenomegaly per 100 persons studied is sometimes called the splenic index and is said to correlate with the prevalence of malaria in an area. A splenic index of 11–50 correlates with a hypo-endemic area, while an index above 75 suggests a hyper-endemic area. In tropical splenomegaly due to malarial disease, the splenic tissue is usually homogenous with a smooth but enlarged appearance (Figure 1).

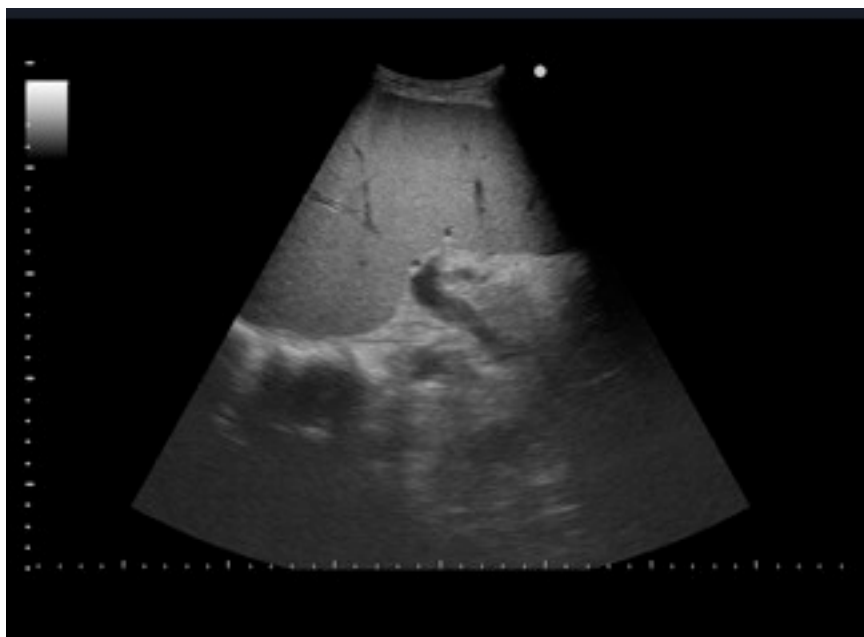


Figure 1. Splenomegaly with homogenous appearance of the spleen

Neoplastic or hyperplastic splenomegaly

Splenomegaly caused by hematologic diseases, such as lymphomas and hemoglobinopathies, is also non-specific, and the appearance of the spleen does not usually indicate a specific disease. Splenomegaly associated with malignant lymphoma may have a more irregular appearance and may be associated with focal lesions, which can help distinguish this cause of splenomegaly from others.

Congestive splenomegaly

Splenomegaly can also be caused by the increase in portal venous pressure that results from liver disease. This is a mechanical, rather than inflammatory effect, and may be distinguished based on the presence of collateral blood vessels or other signs and symptoms of portal hypertension. Ultrasound measurement of the splenic vein, as shown in Figure 2, may be used to monitor patients with chronic liver disease to help identify whether or not they have developed portal hypertension.

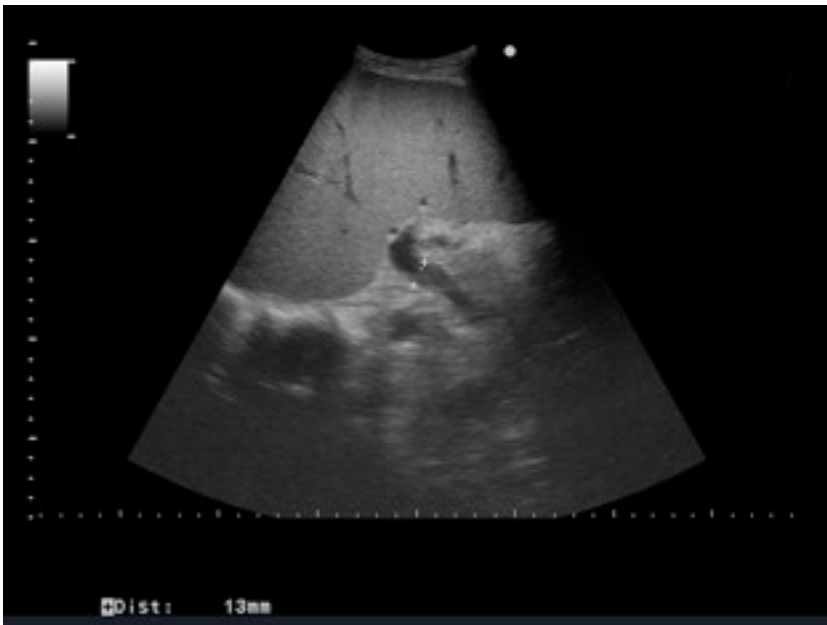


Figure 2. Splenic vein enlargement measuring 13 mm

Focal lesions

Fluid-filled masses

Ultrasound may also help diagnose focal lesions in the spleen, including abscesses and other masses. Primary cysts, such as epithelial cysts, are most common in children and young adults. They are usually solitary lesions surrounded by thin epithelium. A pure cyst will appear spherical, darkly anechoic, and have well-defined margins without a visible wall on ultrasound. When large, even simple cysts may require splenectomy.

Secondary cysts may be caused by trauma and tend to have thicker rims that may be calcified. They may also contain irregular heterogeneous debris. Echinococcal (hydatid) cysts may also be seen on ultrasound (Figure 3, though the spleen is an uncommon location for these cysts.

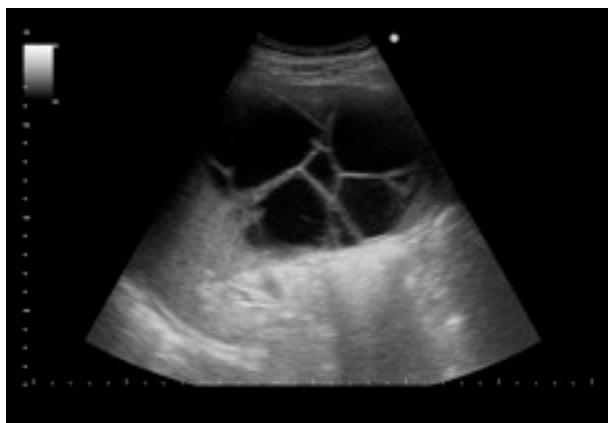

Figure 3. Splenic cyst mimicking an echinococcal cyst

Calcification within the wall of a round cystic mass suggests either hydatid or traumatic etiology (Figure 4).

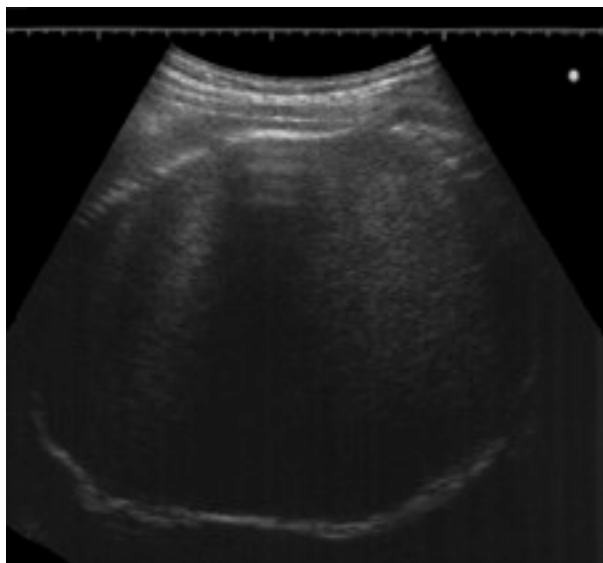


Figure 4. Splenic hematoma mimicking a hydatid cyst with calcification of the wall

Findings concerning for abscess include gas within a fluid-filled mass — gas on ultrasound is brightly echogenic, with poorly defined areas with irregular shadowing. Gas may also cause “comet tail” artifact, or mobile bright streaks radiating behind it in the far field. A thick or irregular wall and echogenic internal debris are characteristic of an abscess, as shown in Figure 5, but may also be seen in hematoma or necrotic tumor. Splenic abscesses are most frequently caused by fungi (*Pneumocystis*, *Cryptococcus*, *Aspergillus*, and *Candida*), and less often by mycobacteria, bacteria (*Bartonella*, *Rhodococcus*, *Nocardia*, *Staphylococcus*), and protozoans. (See also “Solid masses”.) Avoid misdiagnosis of the normal stomach as an abscess, since this organ is seen as a fluid filled structure that neighbors the spleen.

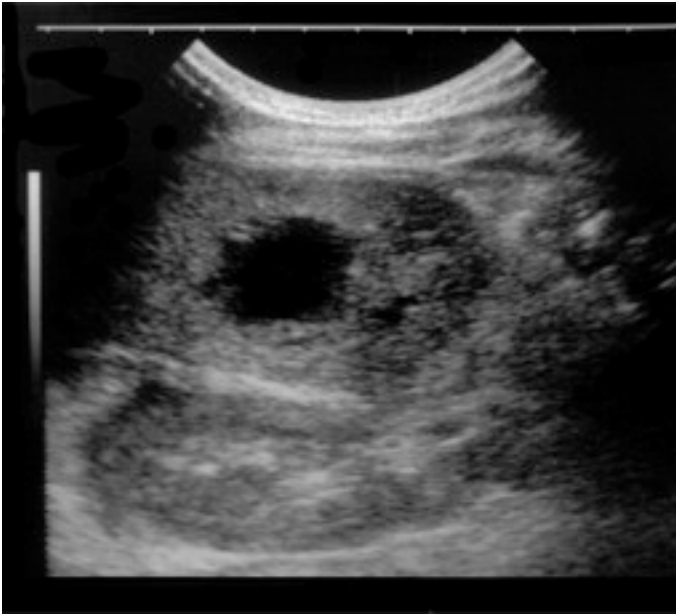


Figure 5. Splenic abscess

Using color flow may also help identify vascular abnormalities that appear as fluid filled masses, such as pseudoaneurysms. Vascular flow within a cystic-appearing mass may also indicate a necrotic vascularized tumor.

Solid lesions

Solid splenic lesions are much less common than fluid-filled masses, and may be caused by many different conditions.

Past granulomatous disease, such as tuberculosis, may cause solid calcified splenic lesions that will be bright on ultrasound, as demonstrated in Figure 6.

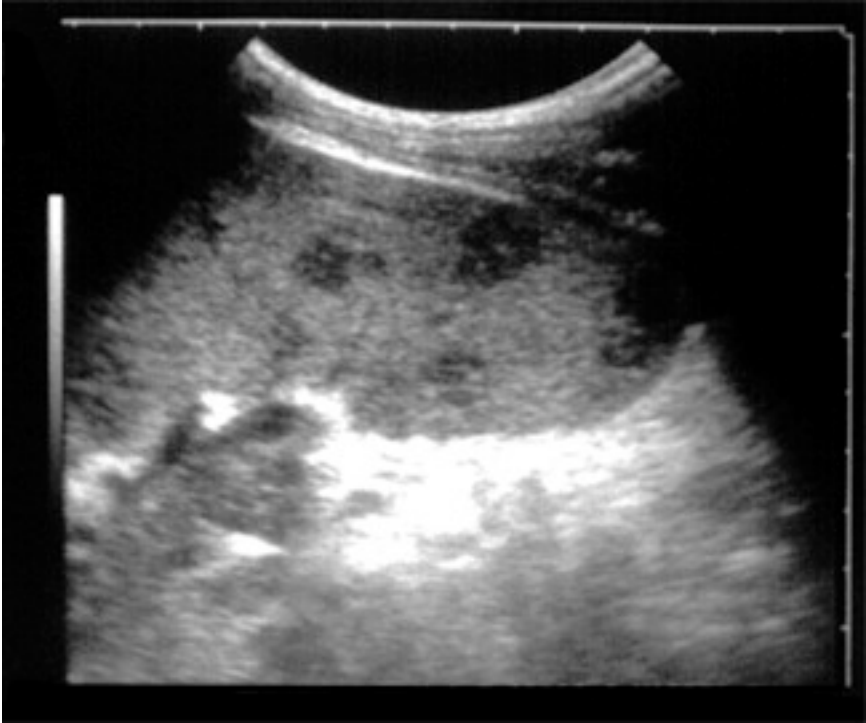


Figure 6. Solid splenic lesion from TB

Many conditions that can be associated with HIV, such as miliary tuberculosis, mycobacteria, and *Pneumocystis jiroveci* can also result in multiple focal lesions or micro-abscesses that may appear solid. In HIV-positive patients, Kaposi's sarcoma or lymphoma must always be

considered as a cause of multiple splenic lesions. Candidiasis and other fungal infections (Figure 7) may appear as small lesions with echogenic centers and hypoechoic rims, sometimes called “wheels within wheels” or “bull’s-eye” appearances.

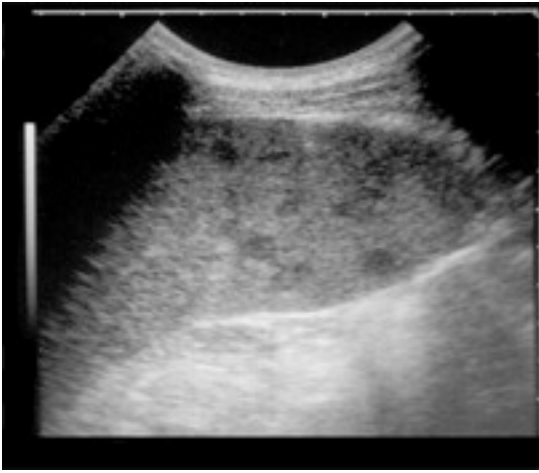

Figure 7. Multiple fungal abscesses in the spleen

Hemangiomas are usually small (< 2 cm) and benign and are the most common primary splenic tumor. Again, the use of color flow may help distinguish these. Lymphoma may also be associated with solid focal lesions, though malignancies of the spleen are rare.

Splenic infarction may appear as a wedge-shaped hypoechoic area with no color flow, as demonstrated in Figure 8. Infarction may be caused by endocarditis or

other embolic phenomena, or may affect the whole spleen as the result of splenic vein thrombosis. An infarcted spleen will initially be enlarged and will then become small and echogenic as scarring occurs.

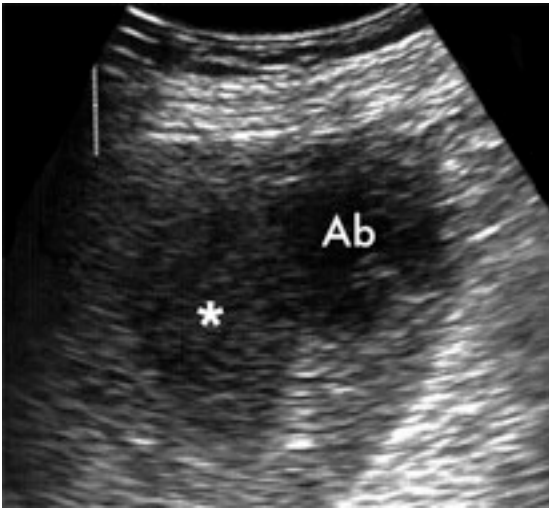

Figure 8. Abscess (Ab) developing from a wedge-shaped infarct (*)

Splenic vein

Ultrasound evaluation of the spleen may include measurement of the diameter of the splenic vein. A normal splenic vein diameter is < 10 mm. Enlargement may indicate portal hypertension or thrombosis.

Normal variations

A common normal variation is to see small accessory spleens, or “splenules.” These are usually found close to the splenic hilus and have the same echo pattern as the spleen itself. A small accessory spleen should not be misinterpreted as an enlarged lymph node.

Technique

Use an curved probe with a footprint large enough to visualize the full length of the spleen in a single image. The probe marker should point to the patient’s head or the patient’s right side.

Visualizing the spleen

The echo pattern of the spleen is smooth and homogenous and slightly darker than liver. The diaphragm appears on ultrasound as an echogenic line outlining the superior margin of the spleen. The spleen is best visualized with the patient supine or in the right lateral decubitus position. The probe should be positioned as shown in Figure 9 in the posterior and mid-axillary lines since the anterior view is usually

disrupted by gas in the stomach and the splenic flexure of the colon. Views should be obtained both on top of and below the lower ribs. Rotate the probe to allow both longitudinal and oblique subcostal and intercostal views.

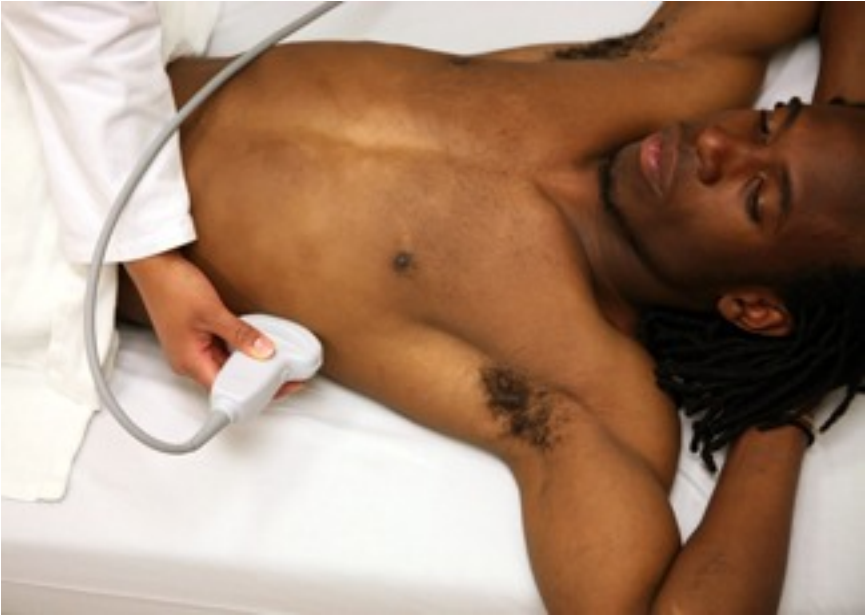

Figure 9. Probe position for spleen imaging in long axis view

Basic measurements

The oblique diameter of the spleen should be measured at the widest point. The longitudinal view of the spleen will vary significantly with respiration and measurements should be taken in various respiratory phases to ensure that the greatest diameter is seen. The

greatest diameter between the diaphragm and lower pole should be taken. The maximum dimensions of the normal spleen are 5 x 7 x 12 cm.

The splenic vein

The splenic vein runs horizontally from the spleen along the posterior edge of the pancreas until it joins the portal vein. It appears slightly comma-shaped because it is wider on the patient's right where it is joined by the superior mesenteric vein before joining the portal vein (Figure 10), Color Doppler may be used to differentiate the splenic vein from artery, if the sonographer is unsure.

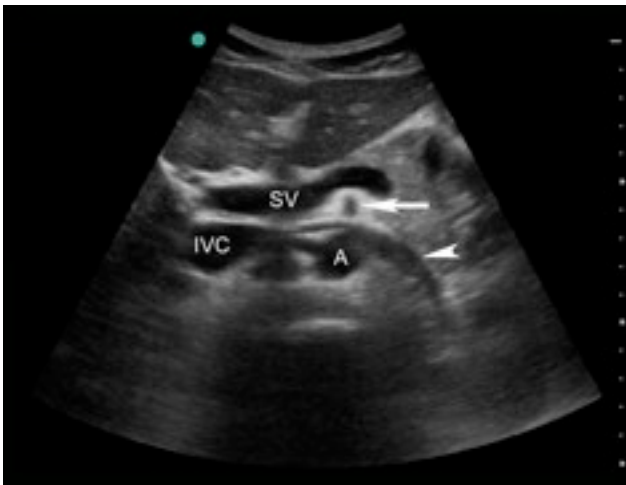


Figure 10. The proximal aorta (A), superior mesenteric artery (arrow), renal (arrowhead) and splenic veins (SV)

Conclusions

Ultrasound is an important tool for evaluating the spleen. Indications include a variety of inflammatory, hematologic, and infectious conditions (especially protozoal infections, and infections in immunocompromised patients), as well as chronic liver disease where there is concern for portal hypertension. Normal spleen diameter is less than 12 cm. While splenomegaly is non-specific and may be associated with a variety of acute and chronic conditions, serial measurements of the spleen may be helpful to monitor disease progression or treatment. Ultrasound is also useful in the diagnosis of focal splenic lesions, such as abscesses or cysts, and the specific appearance of a lesion may help determine its nature. Measurements of the splenic vein may also be useful to evaluate patients for portal hypertension or thrombosis.

Recommended reading

1. Andrews MW. Ultrasound of the spleen. *World J Surg* 2000;24:183-7.
2. Bonnard P, Lanuit R, Dompnier JP, et al. [Predictive ultrasonographic criteria for portal hypertension due to *Schistosoma mansoni* in a recently established endemic zone]. *Med Trop (Mars)* 2000;60:42-6.
3. Harald T. Lutz HAG. *Manual of Diagnostic Ultrasound in Infectious Tropical Diseases*. Berlin, Germany: Springer-Verlag, 2006.
4. Richter J, de Bernardis C, Sagir A, et al. Is ultrasound a useful adjunct for assessing malaria patients? *Parasitol Res* 2004;94:349-53.
5. Doehring-Schwerdtfeger E, Kaiser C, Schlake J, et al. Ultrasound versus clinical examination as indication for *Schistosoma mansoni* associated morbidity in children. *Trop Med Parasitol* 1992;43:245-8.
6. Mathieson JR, Cooperberg PL. The Spleen in Diagnostic Ultrasound. *Mosby Year Book*. St. Louis, MO: Mosby; 1997:154-177.

Kidney

JENNIFER CARNELL MD

Introduction

Diseases of the kidney and urinary tract are commonly encountered in patients presenting with complaints of fever, flank or back pain, lower abdominal pain, or urinary symptoms. There are many ways to obtain images of the kidneys including ultrasound, computed tomography (CT), angiography, intravenous pyelogram and magnetic resonance imaging (MRI). Advantages to using ultrasound to image the kidneys include that ultrasound, 1) can be performed at patient's bedside, 2) may be more accessible than tests such as CT and MRI, 3) provides images without radiation exposure to patient, and 4) does not require iodinated contrast.

Anatomy

An understanding of the ultrasound appearance of the normal kidney allows providers to recognize disease states in an abnormal kidney. During a properly performed ultrasound exam, the kidney is visualized in two perpendicular planes — the longitudinal or long axis, and the transverse or short axis.

In the longitudinal plane, the kidney appears oval shaped, like a bean or mango, as shown in Figure 1.

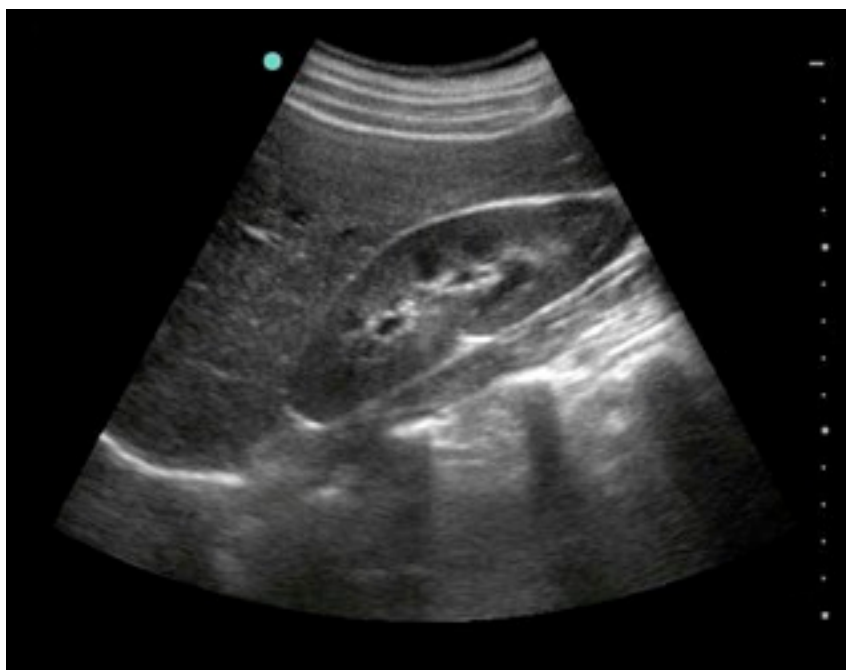


Figure 1. Long axis of the right kidney

In the transverse plane, the kidney is round or C-shaped, as shown in Figure 2.

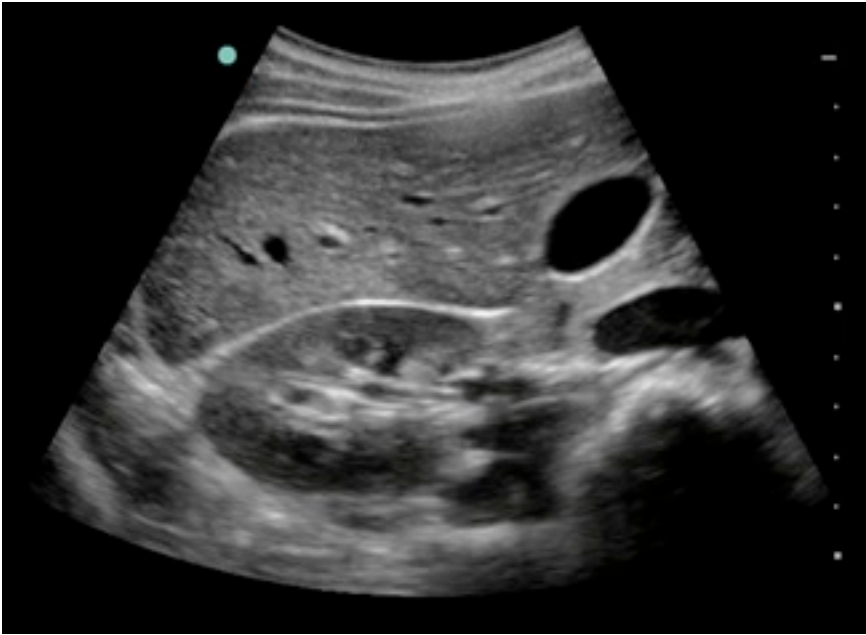


Figure 2. Right kidney in the transverse axis

The width of a normal kidney is 4-6 cm and the length is 9-13 cm. The kidneys should not differ in size by more than 2 cm.

The kidney is surrounded by a bright white (echogenic) capsule called Gerota's fascia. Outside the fascia, there is a layer of perinephric fat of variable thickness. Providers must be cautious not to mistake the fat for a layer of fluid. Fat appears black, as fluid does. Fat has

some echogenicity and appears light gray on careful examination. Within Gerota's fascia lies the kidney. The echogenic renal sinus, containing renal blood vessels, the urine collecting system, fibrous and fatty tissue, is located in the center of the kidney. The parenchyma — cortex and medulla — surrounds the sinus, is less echogenic and appears gray. Normal renal parenchyma is less echogenic than the liver. The medullary pyramids may be seen within the parenchyma as hypoechoic triangular structures. The anatomy of the kidney is demonstrated in Figure 3.

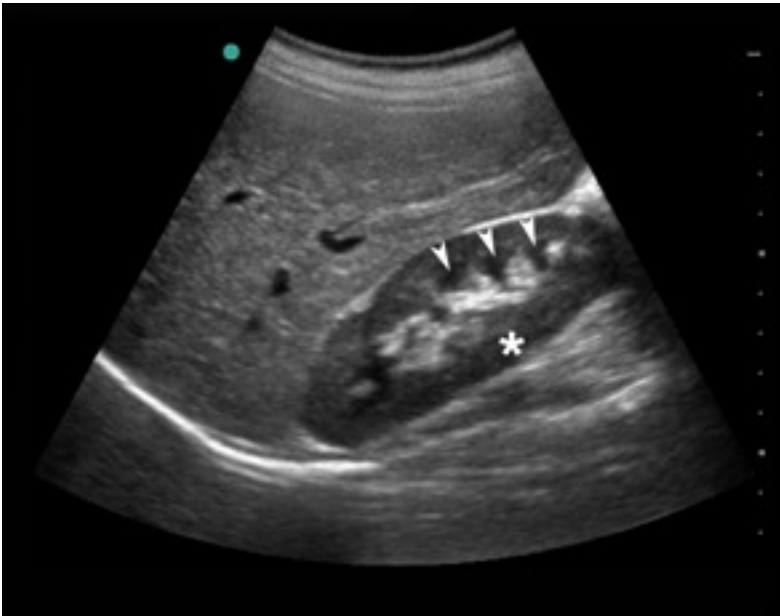


Figure 3. The kidney contains medullary pyramids (arrowheads) and an outer cortex (*)

The kidneys are located between the 12th thoracic and the 4th lumbar vertebrae. The right kidney is next to the liver, which helps provide a better view of the kidney when used as an acoustic window, as shown in Figure 4a. The left kidney lies next to the spleen, which acts as an acoustic window, as shown in Figure 4b. The spleen is near the stomach, which appears as a gas or fluid-filled structure, and may interfere with the search for a good kidney image. Due to the presence of the liver, the right kidney is usually more inferior (more toward the patient's feet) than the left kidney. The left kidney is usually located more posterior (toward the patient's back) than the right kidney. The position of both kidneys will change as the patient breathes.

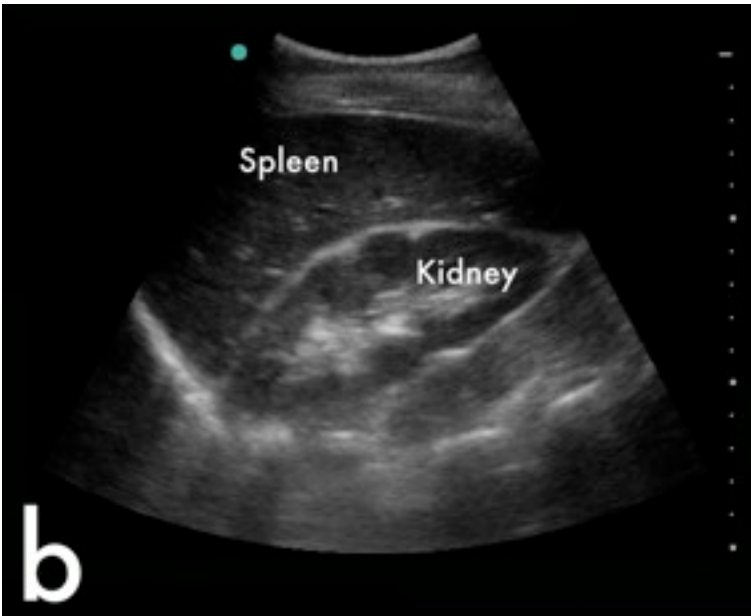
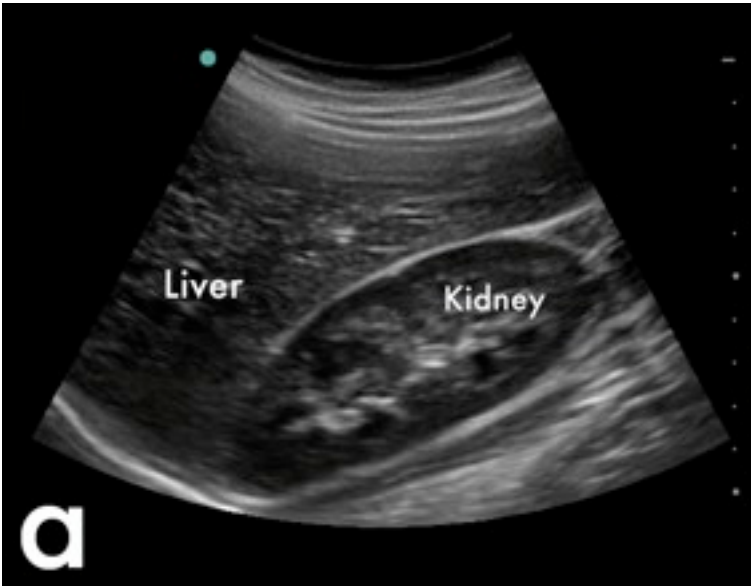


Figure 4. a: The right kidney is adjacent to the liver. b: The left kidney is adjacent to the spleen.

Clinical applications

- Hydronephrosis
- Kidney stones
- Kidney size may suggest pathology
- Kidney masses, tumors or cysts
- Polycystic kidney disease
- Infection including abscess
- HIV/AIDS nephropathy

Sonographic findings

Hydronephrosis

Hydronephrosis is most often due to an obstruction of the urinary system. The obstruction may lie within the urinary tract due to stone, blood clot, tumor, infection with *Schistosomiasis haematobium* or tuberculosis, or narrowing due to scarring. Obstruction may be caused by compression from outside the urinary tract by an intra-abdominal tumor, aortic aneurysm, enlarged uterus, cervical cancer, or prostate enlargement or

cancer. Neurologic problems and medications can also cause hydronephrosis.

The urine collecting system, renal pelvis and calyces, dilates in hydronephrosis. The collecting system is located in the center of the kidney, within the renal sinus. When urine accumulates due to obstruction, the resulting dilation causes this area to appear black or anechoic. Hydronephrosis in only one kidney is usually due to an obstruction of the ureter on that side. If unsure whether a hypoechoic area is a dilated ureter or vasculature in the renal pelvis, Doppler can help assess for flow through the hypoechoic area. A hydroureter and dilated collecting system will not have a Doppler signal, because the urine does not flow freely. Hydronephrosis in both kidneys, accompanied by a large bladder, may be due to, 1) obstruction of the bladder outlet, 2) obstruction of the urethra, 3) an enlarged prostate, or 4) bladder dysfunction, which may be due to a medication or a neurologic problem such as spinal cord injury or cauda equina syndrome. Hydronephrosis is classified by its severity as mild, moderate or severe. If a patient is dehydrated, hydronephrosis may not be seen, because the patient is not making adequate urine. Therefore, a patient must be hydrated before an exam can be called

negative for hydronephrosis. A full bladder in a patient who has not urinated recently can also produce mild hydronephrosis that will disappear as soon as the patient urinates. For this reason, all patients should be asked to empty their bladders before an ultrasound exam of the kidneys. Figure 5 shows sample images of moderate and severe hydronephrosis.

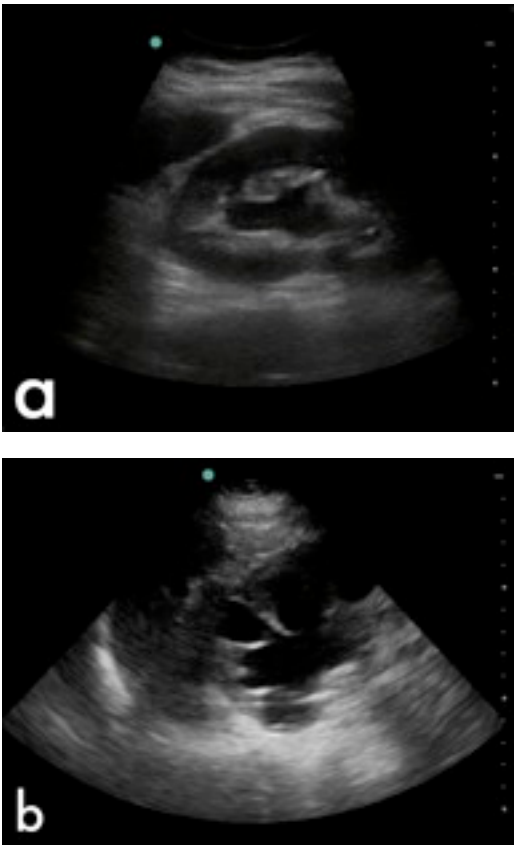


Figure 5. Moderate (a) and severe (b) hydronephrosis

Kidney stone

On ultrasound, a kidney stone appears bright white (hyperechoic) with a dark shadow extending down, like a gallstone (Figure 6). Infrequently, a stone may be seen within the kidney but rarely causes obstruction at this location, unless it is very large. A stone within the ureter is more likely to cause obstruction and pain but can be very difficult to see with ultrasound, especially if the stone is small, bowel gas interferes, or the patient is obese. In typical cases, a stone will not be identified, but hydronephrosis will be seen, if the stone obstructs the ureter.

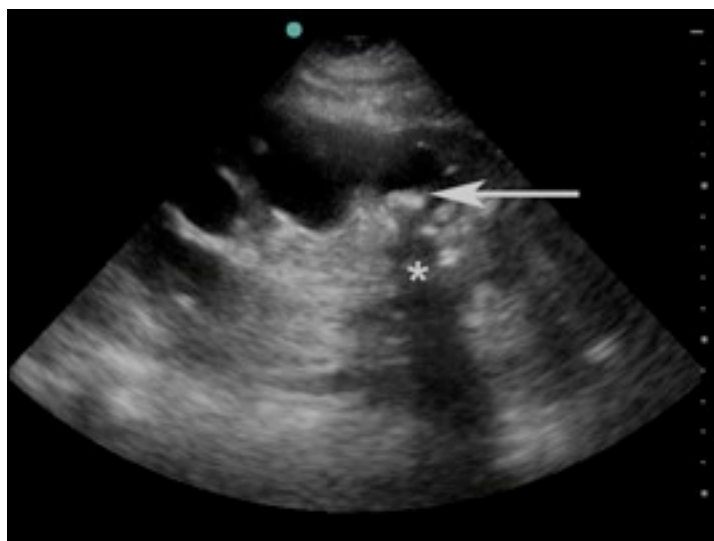


Figure 6. Renal stone (arrow) within the kidney and shadow artifact (*)

Variation in size

Small, shrunken kidneys may be seen in longstanding kidney failure (Figure 7). In addition, the kidney parenchyma may appear more echogenic. Large kidneys may be seen in patients with diabetes, kidney infection, HIV nephropathy or recent onset of kidney failure.

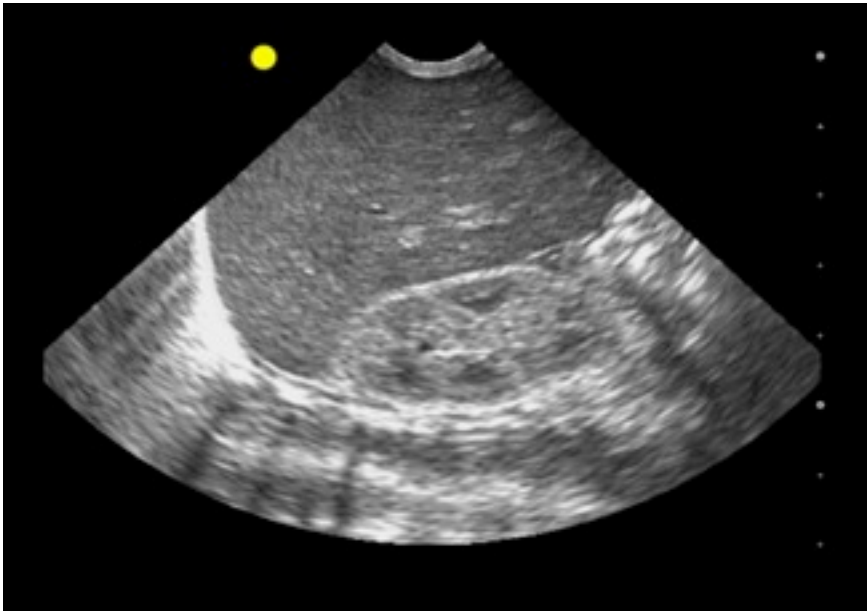


Figure 7. Hyperechoic small kidney in chronic renal failure

Kidney mass

Kidney masses, including cancer, can be identified with ultrasound — sometimes before the patient has

symptoms. Ultrasound is unreliable for detecting smaller masses, especially those less than 2 cm. If the provider suspects renal cancer, other tests such as a CT are needed. Any patient with a kidney mass will need further evaluation by a specialist.

Kidney cysts

Kidney cysts are common. A cyst will be located in the kidney parenchyma toward the periphery of the kidney, not within the renal sinus. A benign cyst will appear as a round, anechoic structure with a thin wall (Figure 8).

The peripheral location distinguishes a cyst from hydronephrosis, which is found in the center of the kidney. If a cyst is larger than 1 cm diameter, has a thick wall, internal septations or solid areas, the patient should follow-up with a specialist for further evaluation.

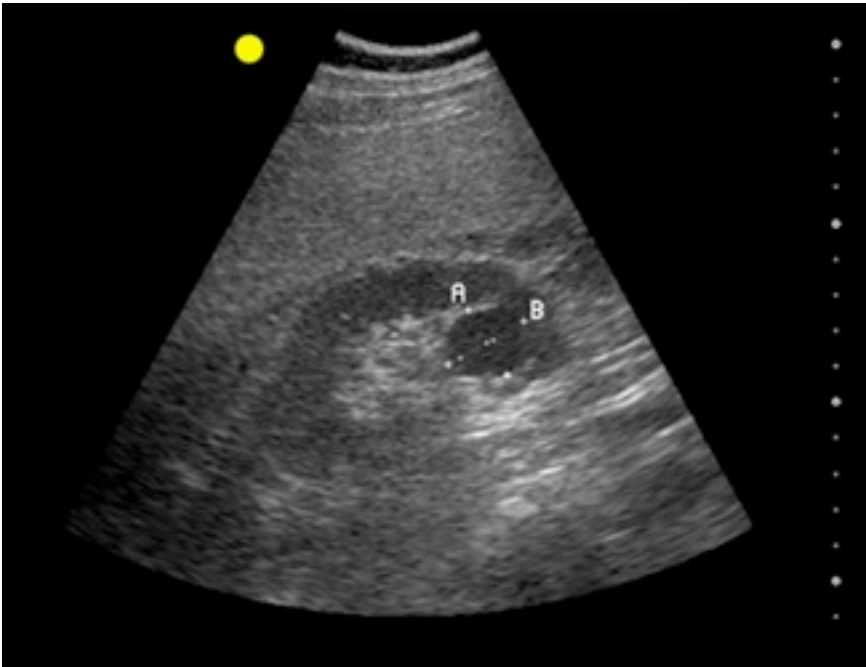


Figure 8. Renal cyst

Polycystic kidney disease

In polycystic kidney disease, the normal architecture of both kidneys is disturbed, and the kidneys appear enlarged due to the presence of many cysts of different sizes and shapes (Figure 9). Patients with this disease need referral to a kidney specialist.

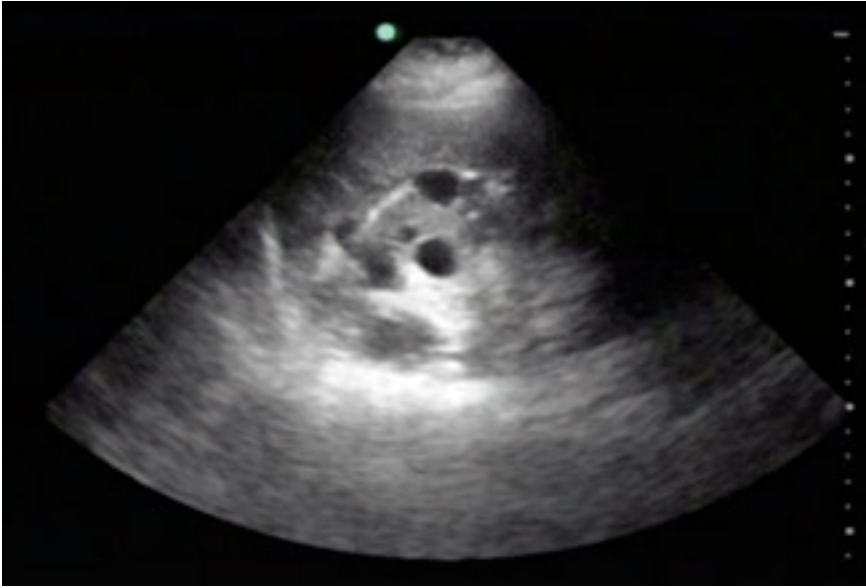


Figure 9. Polycystic kidney disease

Infection

Ultrasound is often normal in kidney infection (pyelonephritis). However, small, hypoechoic areas with irregular borders may be seen in the renal parenchyma. These areas may enlarge or appear anechoic, if an abscess forms.

If infection spreads outside the kidney and forms a perinephric abscess, an anechoic or hypoechoic fluid collection may be seen around or next to the kidney. At times, abscesses may look like cysts. The patient's

symptoms and history are important in making the correct diagnosis.

Severe kidney infections may produce gas within the kidney and require aggressive treatment. Gas may be mistaken for a stone because it appears echogenic with a dark gray shadow extending down. Careful ultrasound imaging and clinical history may help the provider decide if it is gas or a stone. Tuberculosis may cause increased parenchymal echogenicity due to calcifications and/or hydronephrosis.

HIV/AIDS nephropathy

Ultrasound is often normal in HIV/AIDS nephropathy. Kidneys may be enlarged with a more echogenic parenchyma. Loss of corticomedullary differentiation or detail may be seen.

Technique

For this exam, use the curvilinear transducer. Before starting the exam, have the patient attempt to empty their bladder. Start with the patient supine, lying as flat as possible without elevating the head. If the kidneys are

difficult to visualize, the patient can lay left side down to examine the right kidney, and right side down to examine the left kidney. The index marker should point toward the patient's head in the longitudinal axis or toward the patient's right side or back in the transverse axis. The kidney should be imaged in both planes.

Step by step approach

1. To image the right kidney, place the abdominal transducer on the patient's right flank in line with the middle of the axilla with the index marker pointed toward the patient's head, as in Figure 10.

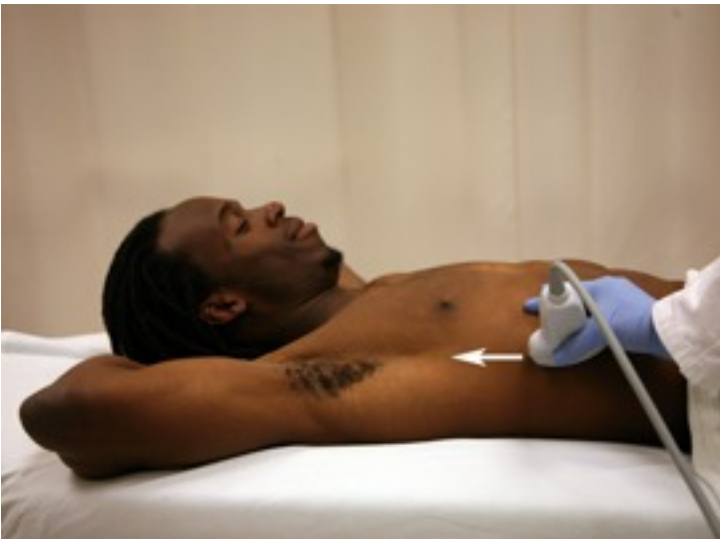

Figure 10. Probe position for a long axis view of the right kidney, with the index marker pointing toward the patient's head (arrow)

2. You will need to change the angle of the transducer in order to obtain the best view of the kidney. Aim the transducer, not the index marker, toward the patient's back and slowly change the angle until you are aiming the transducer toward the front of the patient — this action of changing the angle is called “fanning”. If you do this slowly, you will be able to see many views of the kidney in the longitudinal plane. This is important, because multiple views provide more information than a single view and allow more abnormalities to be detected.
3. In the longitudinal axis, the superior pole of the kidney will be on the left side and the inferior pole will be on the right side of the ultrasound screen, as shown in Figure 11.

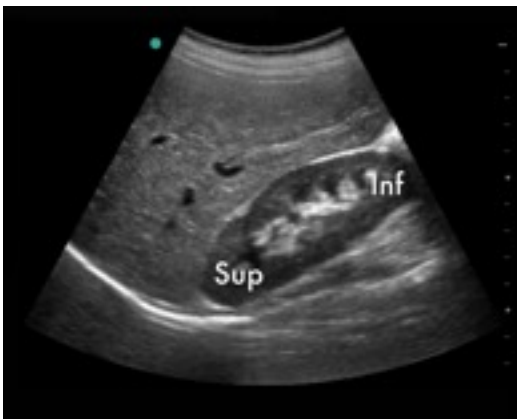


Figure 11. The superior (Sup) and inferior (Inf) poles of the right kidney

4. Once you have obtained views of the kidney in the longitudinal axis, rotate the transducer 90 degrees counterclockwise, so that the index marker is pointing toward the patient's back, as in Figure 12. In this position, a transverse view of the kidney will be seen. Repeat the process of “fanning” as in step 2, but this time angle the transducer upward so that it is pointing toward the patient's head, then downward toward the patient's feet until you can no longer see the kidney. Do this slowly while watching the screen in order to see the entire kidney in this plane.

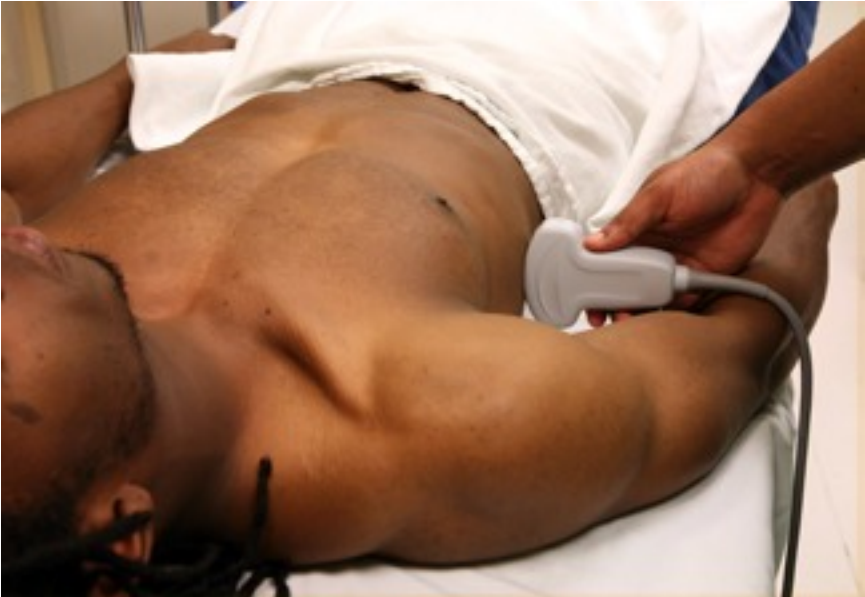

Figure 12. Probe position for a transverse view of R kidney

5. To image the left kidney, place the transducer on the patient's left flank with the index marker pointed toward the patient's head. Compared to the right kidney, the left kidney is located more toward the patient's back, so the transducer must also be positioned more toward the back (Figure 13).

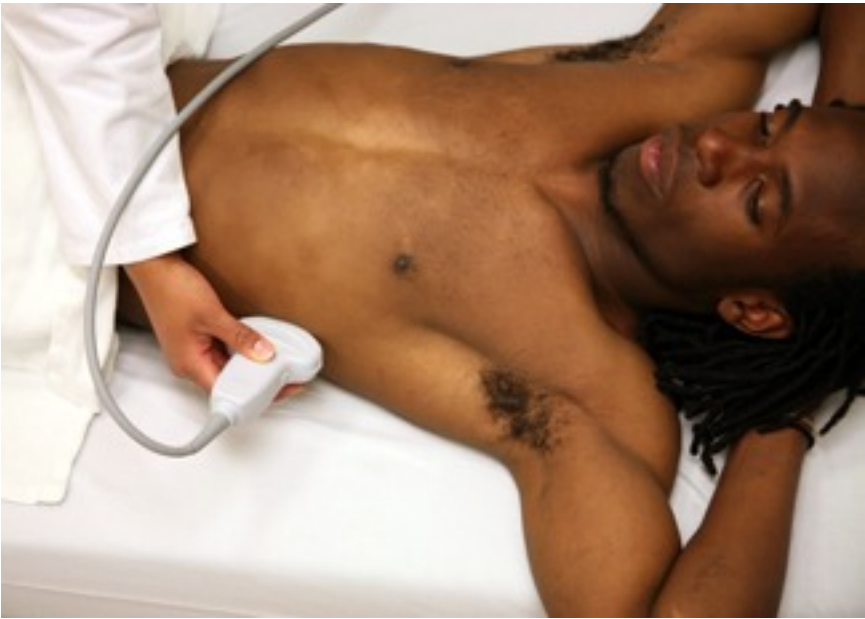

Figure 13. Probe position for a long axis view of left kidney

6. Repeat steps 2-4 to obtain adequate views of the left kidney. In step 4, the transducer is rotated 90 degrees counterclockwise, so the index marker is pointing toward the ceiling when the patient is lying supine.

7. Asking the patient to hold a deep breath may help you better visualize each kidney.

Conclusion

Ultrasound can provide valuable information about the kidneys and help explain a patient's symptoms. Using ultrasound, kidney stones, urinary tract obstruction, and kidney tumors may be detected. At times, ultrasound can demonstrate changes suggesting kidney infection due to bacteria, tuberculosis or HIV.

Recommended reading

1. Blaivas M, Lyon M. Renal Ultrasound. In: Cosby KS, Kendall JL, eds. *Practical Guide to Emergency Ultrasound*. Philadelphia, PA: Lippincott Williams & Wilkins, 2006:237-53.
2. Browne RF, Zwirewich C, Torreggiani WC. Imaging of urinary tract infection in the adult. *Eur Radiol* 2004;14 Suppl 3:E168-83.
3. Lin EP, Bhatt S, Dogra VS, et al. Sonography of urolithiasis and hydronephrosis. *Ultrasound Clin* 2007;2:1-16.

4. Noble VE, Brown DF. Renal Ultrasound. *Emerg Med Clin North Am.* 2004;22:641-59.
5. O'Connor OJ, McSweeney SE, Maher MM. Imaging of Hematuria. *Radiol Clin North Am.* 2008;46:113-32.

Abdominal aortic aneurysm

HEIDI KIMBERLY MD

Introduction

Abdominal aortic aneurysms (AAA) can be difficult to diagnose by history and physical exam. Ultrasound can be useful in diagnosing aortic aneurysms and in measuring aortic diameter to guide potential surgical intervention. Patients presenting with abdominal, back, or flank pain should be evaluated for the presence of AAA, if the clinical scenario is suggestive. A ruptured aneurysm can cause hypotension, syncope, or cardiac arrest.

AAA is more common in older patients who have high blood pressure, smoke tobacco, or have peripheral vascular disease.

Anatomy

The abdominal aorta is retroperitoneal and can be seen using ultrasound from inferior to the xyphoid process to the aortic bifurcation into the iliac arteries near the level of the umbilicus. It is possible to visualize some of the major branches off the aorta including the celiac artery, the superior mesenteric artery and the renal vessels. The inferior vena cava (IVC) travels just to the right of the aorta. These relationships are shown in Figure 1.

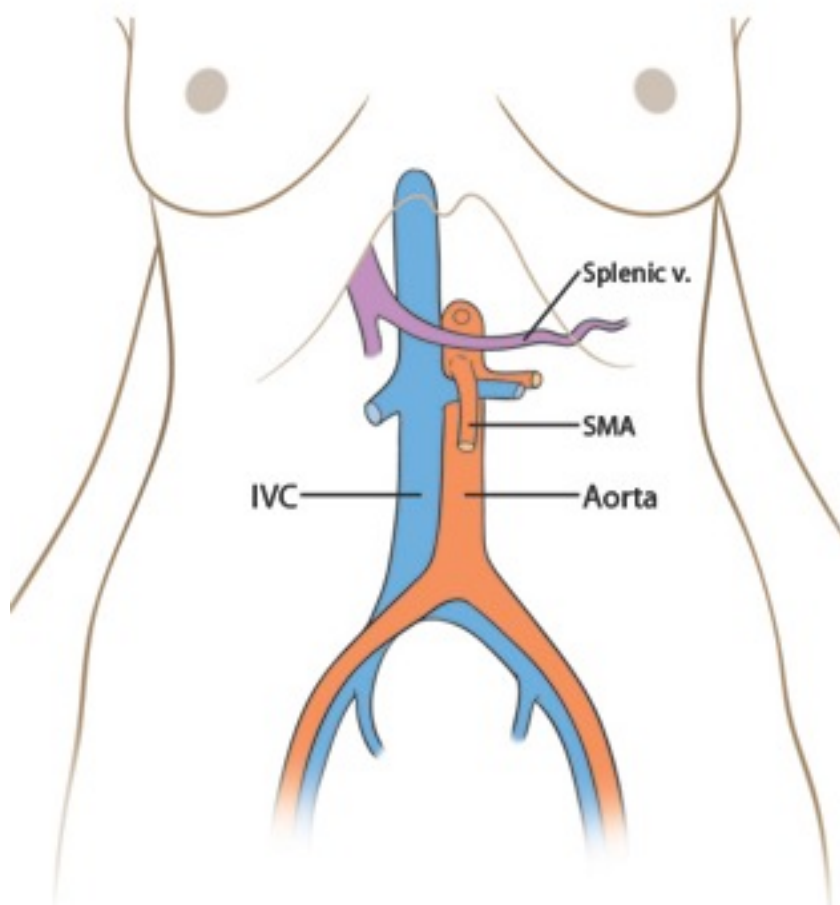


Figure 1. Normal anatomical relationships of the abdominal aorta

The normal abdominal aorta should be less than 3 cm in diameter and the iliac vessels less than 1.5 cm in diameter.

Technique

1. Use the curved or phased array probe.
2. Increase the depth as needed. The aorta will be found deep in the abdomen.
3. Start with the probe marker to the patient's right to get a transverse view.
4. Start in the subxyphoid space using the probe position shown in Figure 2. The sonographer may need to gently press downward to push bowel gas out of the way.

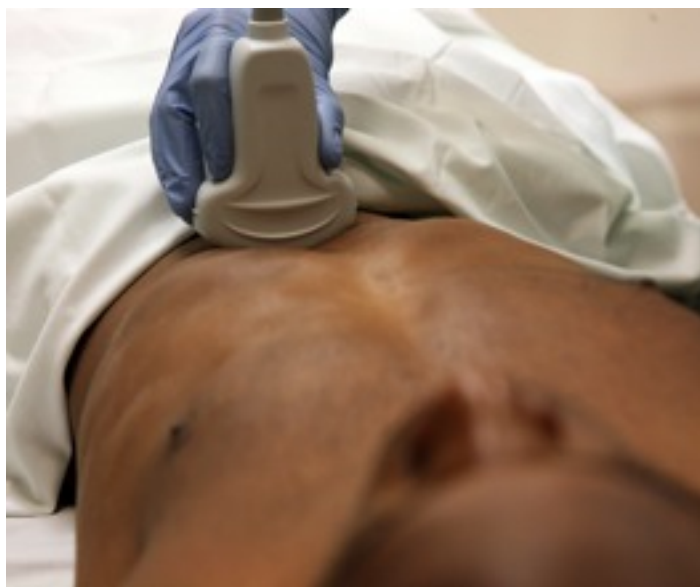

Figure 2. Probe position for transverse view of the aorta

5. Look for anatomical landmarks. First, find the spine shadow. As shown in Figure 3, the aorta is the round, pulsatile vessel superficial to and just to the right of the spine. The IVC is a thin walled, varies in size with respiration, and is located above and just to the left of the spine. When it is difficult to differentiate the aorta from the IVC, consider using color Doppler to demonstrate pulsatile flow.

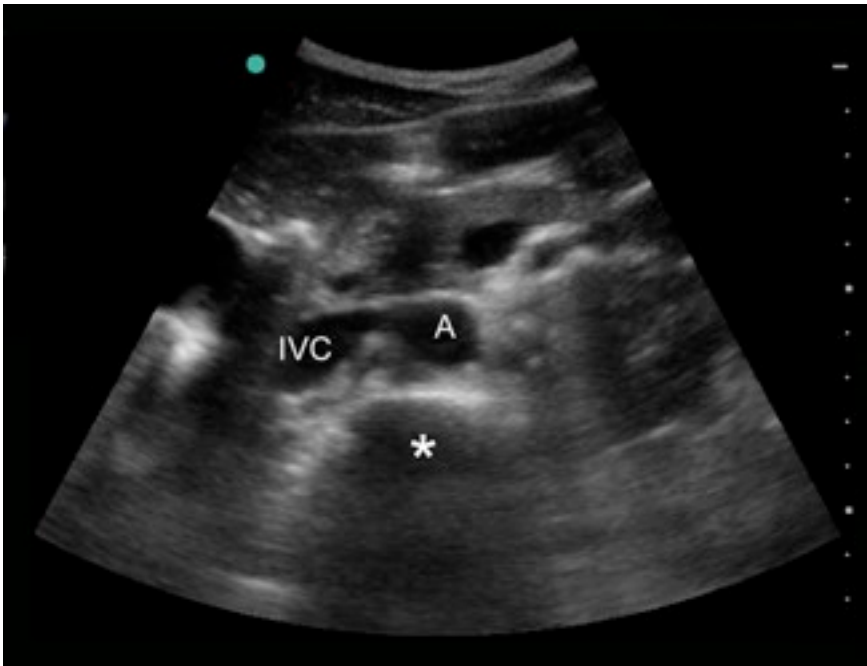


Figure 3. Transverse image of the normal aorta (A), IVC and vertebral body (*)

6. In the area of the proximal aorta, it is possible to view surrounding vessels like the superior mesenteric artery, renal and splenic veins. These relationships are shown in Figure 4.

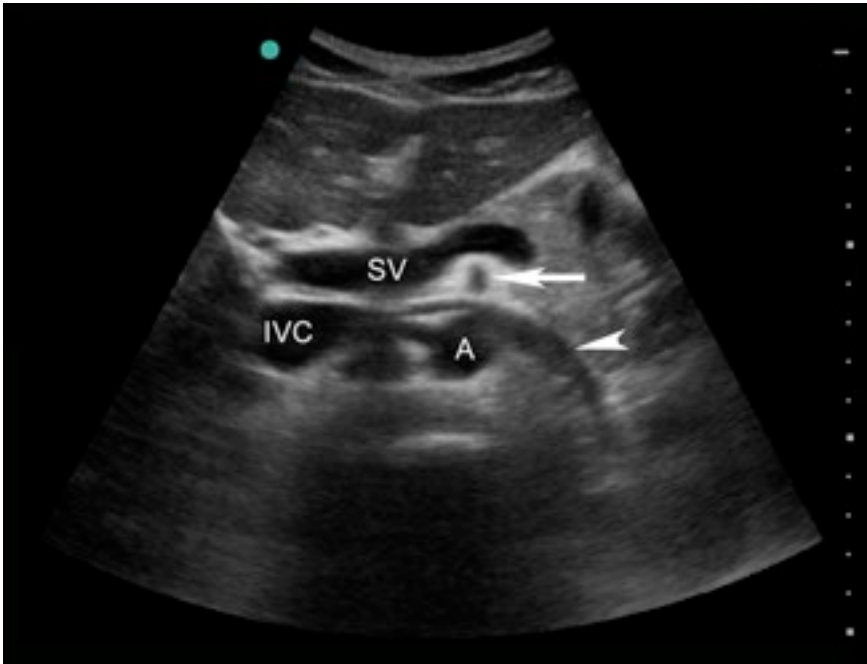


Figure 4. The proximal aorta (A), superior mesenteric artery (arrow), renal (arrowhead) and splenic veins (SV)

7. Freeze the image in preparation of measurement.
Using the calipers, measure the aorta from top to bottom (anterior to posterior) including the walls —

from outer wall to outer wall, as shown in Figure 5. The normal aorta is less than 3 cm in diameter.

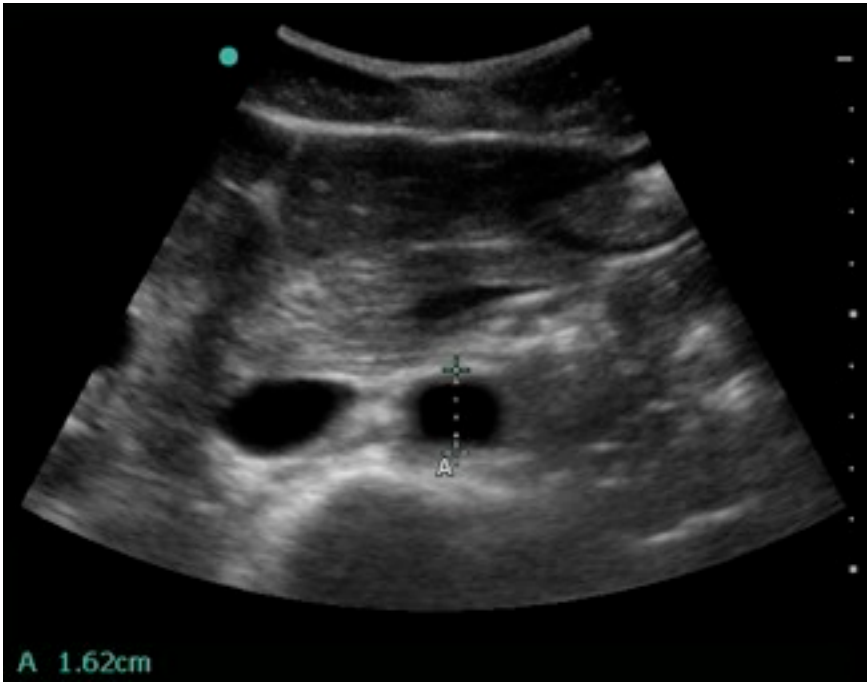


Figure 5. Anterior to posterior measurement of the aortic diameter

8. Slide the probe down toward the umbilicus, following the aorta until it bifurcates into the iliac arteries (Figure 6).

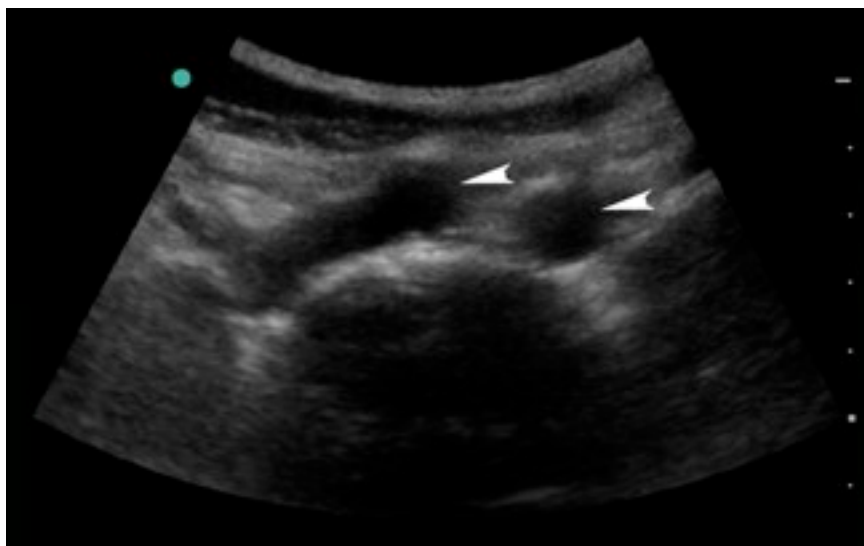


Figure 6. The iliac arteries (*)

9. Measure the aorta at the proximal, mid, and distal portions, and try to visualize the entire aorta.
10. Rotate the probe marker toward the patient's head to get a longitudinal view of the aorta, as demonstrated in Figure 7.

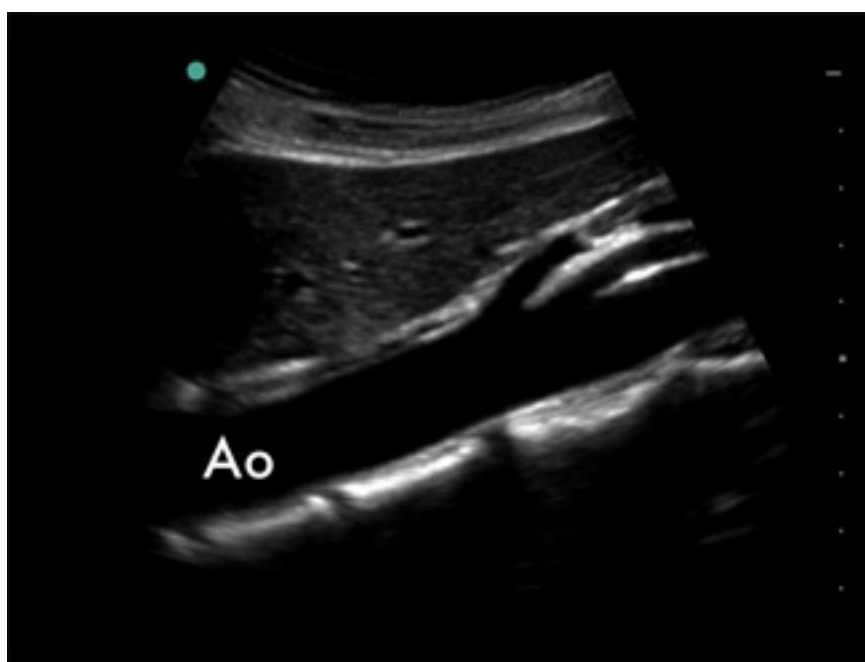
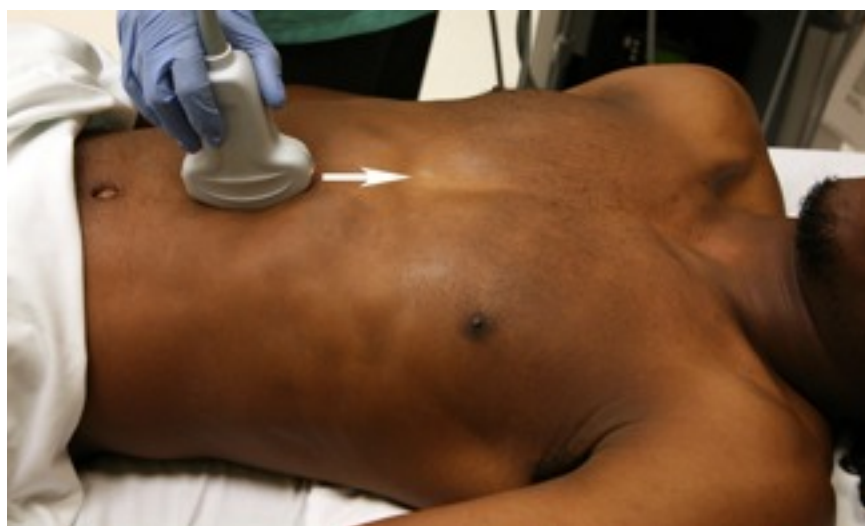

Figure 7. Probe position for the long axis view of the aorta (Ao) and resulting ultrasound image

Pathology

Abdominal aortic aneurysm

AAA is an enlargement of the aorta to greater than 3 cm in diameter. An iliac artery aneurysm is greater than 1.5 cm in diameter. The larger the aneurysm, the greater likelihood of rupture. An AAA greater than 5 cm should be referred to a surgeon, if possible.

Occasionally, the sonographer may notice a thickened aortic wall due to thrombus within the vessel, as shown in Figure 8.

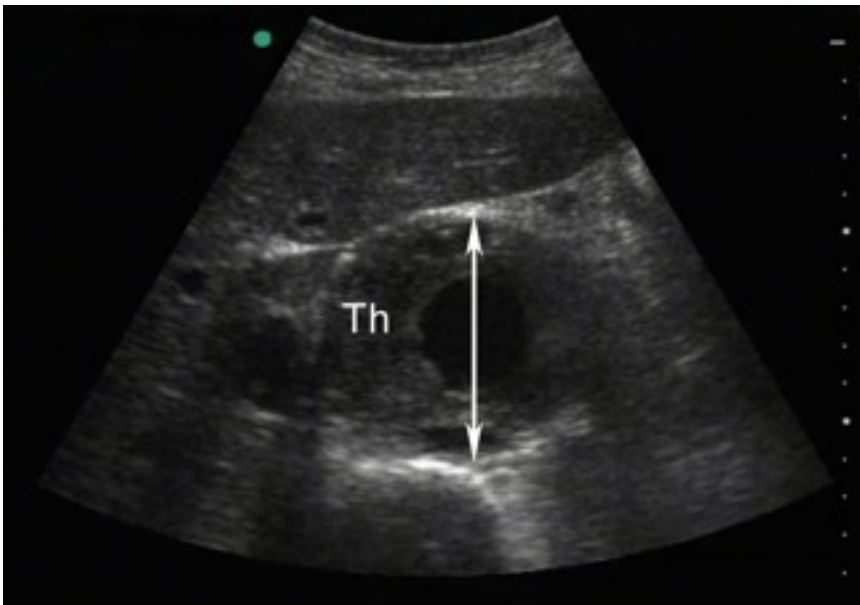


Figure 8. AAA showing thrombus (arrow) within the vessel wall

Ultrasound can help diagnose an AAA but can not reliably determine if the aneurysm has ruptured, because bleeding into the retroperitoneum is difficult to detect with ultrasound.

Aortic Dissection

In a longitudinal view, the sonographer may attempt to image an intimal flap of an aortic dissection. If present, the dissection flap will appear as a bright white line within the vessel, as demonstrated in Figure 9.

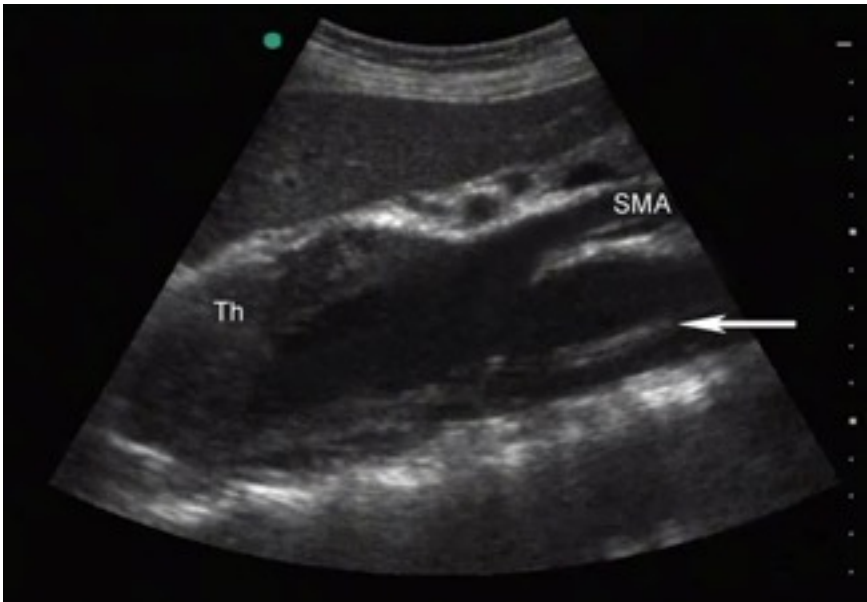


Figure 9. Aortic dissection with a hyperechoic intimal flap (arrow) and thrombus (Th) within the lumen of the aorta

Ultrasound is not as sensitive as computed tomography (CT) with intravenous contrast for detecting aortic dissection, but it can be useful in remote locations where CT is unavailable.

Tips

Obesity and bowel gas can limit the sonographer's views of the aorta. Try gentle compression to push the bowel out of the way. A change in patient position to the left side down (left lateral decubitus) position, may aid in visualization, if the liver is used as an acoustic window. For this view, place the probe in the right mid- axillary line, with the probe marker facing toward the patient's head. This view, similar to the hepato-renal pouch view in the FAST trauma exam, can allow visualization of the aorta in long axis.

Pitfalls

- Unfortunately, it may be difficult to visualize the aorta due to obesity or bowel gas.

- Be careful not to confuse the inferior vena cava or other fluid filled structure (like a pancreatic cyst) with the aorta.
- Be sure to include the aortic wall, not just the lumen, in the diameter measurement to avoid a false measurement.

Conclusions

Ultrasound of the abdominal aorta can help diagnose abdominal aortic aneurysms. Image the aorta from the subxyphoid to the umbilicus, and in two planes (longitudinal and transverse). AAA is an aorta > 3 cm, and the larger the aneurysm the greater chance of rupture. Ultrasound can not diagnose a rupture but a large AAA in an unstable patient is concerning for a ruptured or leaking aneurysm that requires prompt surgical treatment.

Recommended reading

1. Moore CL, Holliday RS, Hwang JQ, et al. Screening for abdominal aortic aneurysm in asymptomatic at-risk patients using emergency ultrasound. *Am J Emerg Med* 2008; 26:883-7.
2. Abdominal Aortic Aneurysm. In Noble V, Nelson B, Sutingco A, eds. *Manual of Emergency and Critical Care Ultrasound*. Cambridge, England: Cambridge University Press, 2007:105-18.
3. Plummer D, Clinton J, Matthew B. Emergency department ultrasound improves time to diagnosis and survival in ruptured abdominal aortic aneurysm. *Acad Emerg Med* 1998;5:417.
4. Reardon R, Cook T, Plummer D. Abdominal Aortic Aneurysm. In Ma O, Mateer J, Blavias M, eds. *Emergency Ultrasound*. New York, NY: McGraw-Hill, 2007:149-168.

Deep vein thrombosis

NATHAN TEISMANN MD

Introduction

Compression ultrasonography of the deep veins of the leg allows the clinician to diagnose venous thrombosis at the bedside. Because it is rapid, accurate and non-invasive, this technique has emerged as the preferred method to assess patients with suspected DVT.

Background

Before the widespread use of ultrasound, patients with suspected DVT typically underwent venography. It is apparent from these studies that DVTs usually begin in the veins of the calf and propagate upward. It was also

observed that proximal (above the knee) DVTs could be discovered either in the popliteal vein, or in the

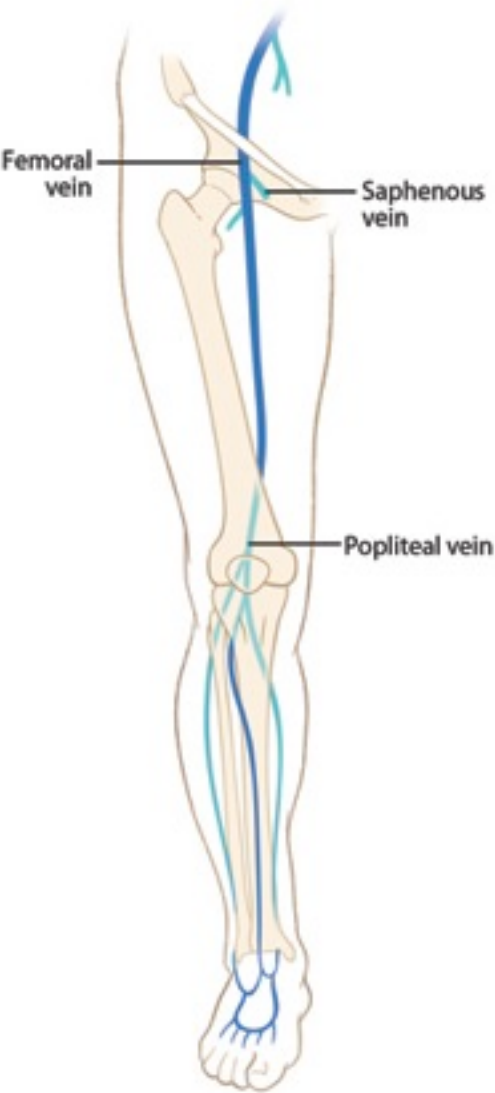


Figure 1. Deep veins of the leg

common femoral vein, or both. No cases were seen in which clots occurred only in the mid thigh. Isolated clots seen only in the common femoral vein are generally thought to begin in the deep femoral vein, rather than the calf veins or popliteal vein, and extend superiorly. A brief review of the anatomy of the lower extremity deep veins is illustrated in Figure 1.

Because isolated calf vein (below the

knee) DVTs are unlikely to cause pulmonary embolism, and because they often resolve without treatment, current practice places emphasis on the diagnosis of proximal DVT. These assumptions form the basis for the 2-point compression technique described below.

Technique

The patient should be in a supine position. The leg should be turned outward with slight flexion at the hip and at the knee in the “frog leg” position, as shown in Figure 2.

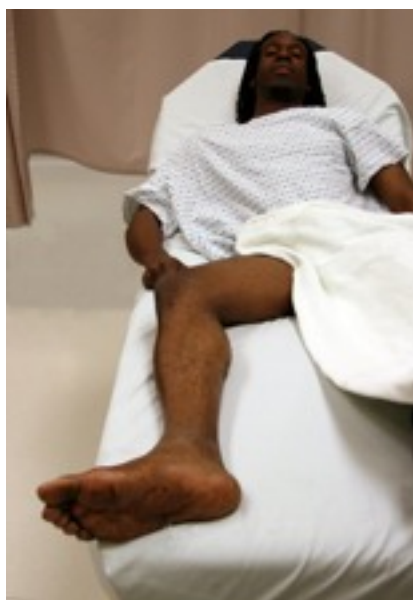

Figure 2. Patient in the “frog leg” position.

Using a linear transducer, images of the vascular structures of the groin should be obtained. Begin scanning at the femoral crease or just above, fanning the probe until an image of the common femoral vein (CFV) and the adjacent common femoral artery (CFA) is achieved, as shown in Figure 3.

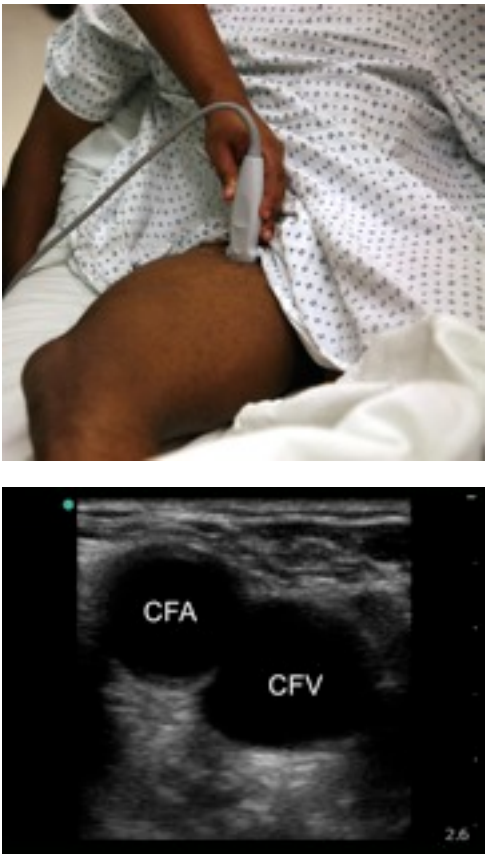

Figure 3a. Probe position at the groin crease.3b. Image of common femoral artery (CFA) and vein (CFV).

The artery at this point is lateral to the vein and will appear pulsatile and round with a thicker wall. Just medial to this, the CFV is seen. If several vascular structures are visible, it is likely that you are imaging below the bifurcation of the common femoral artery, common femoral vein, or both. Fan the probe slightly more superior in order to visualize the paired artery and vein. After establishing the identity of the CFA and CFV, you may wish to scan superiorly to identify the saphenous vein as it joins the CFV and inferiorly to observe the bifurcation of the CFA into the superficial and deep femoral arteries and, below this point, the bifurcation of the CFV into the superficial and deep femoral veins.

With the vessels in view, slowly apply pressure to the patient's leg by pressing down with the probe. In a normal patient, you should see the lumen of the CFV compress until the walls touch each other. The vein should completely collapse so that only the artery is visible. How much pressure should be applied? You may need to press with some force, especially in patients who are overweight or have significant edema. If the artery begins to deform significantly, or collapses, and the vein has not completely collapsed by this time, a

DVT is highly likely. In most patients, the CFV collapses freely without much force, as shown in Figure 4.

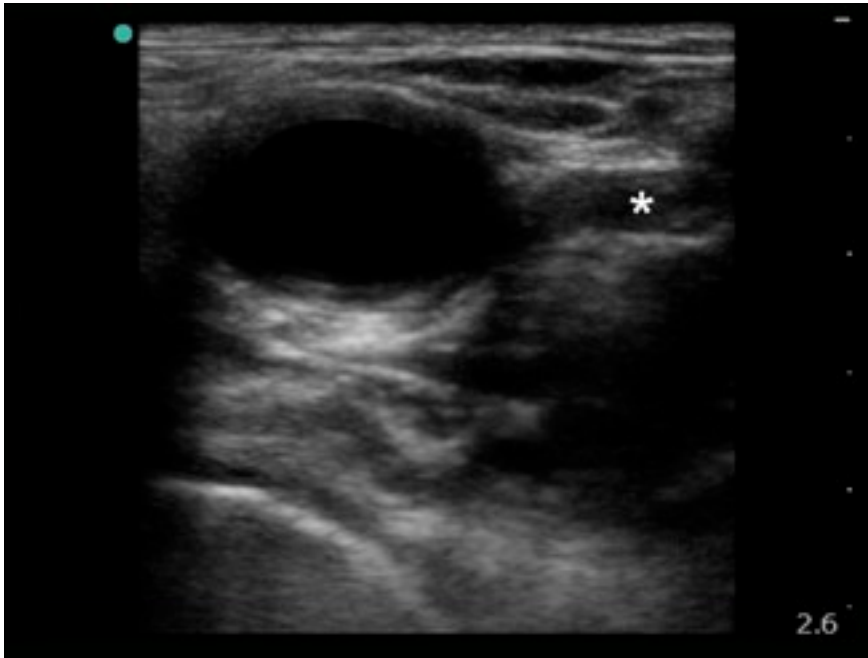


Figure 4. Compression of the common femoral vein (*) is the first point in the 2-point technique.

Turn your attention to the popliteal fossa. The patient's knee should be flexed at about 20-30 degrees. Place the linear transducer in a transverse orientation in the popliteal crease. The popliteal artery and vein will appear as paired structures, usually with the vein posterior and superficial to the artery, as demonstrated in Figure 5.

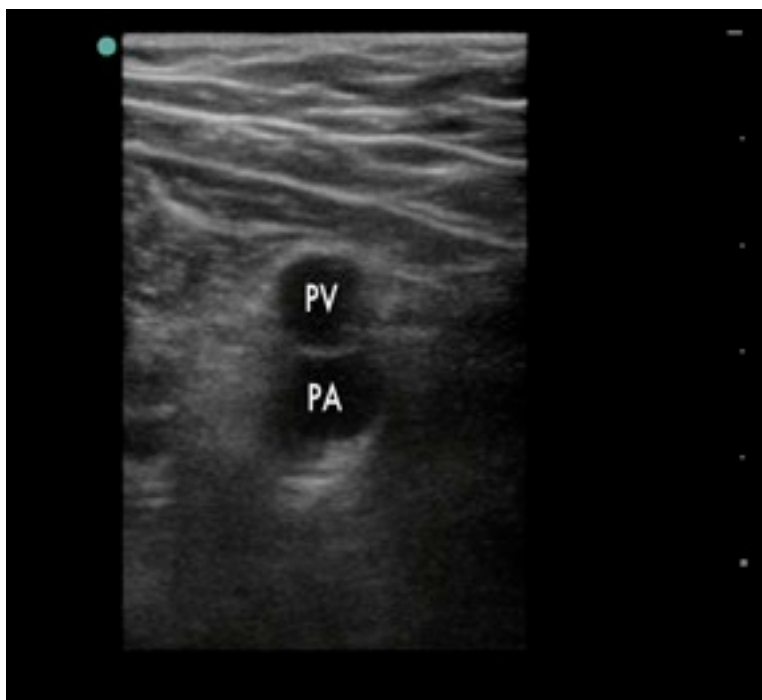
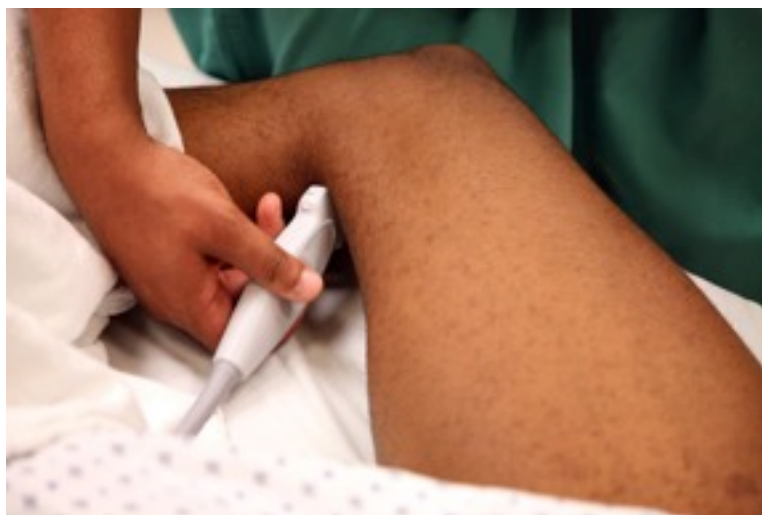
Figure 5. Popliteal probe position and normal popliteal vein (PV) and artery (PA).

On the screen, the vein will appear in the near field relative to the artery. You may recall this with the phrase “the pop is on top.” Smaller perforating veins as well as the greater saphenous vein may be visible at this point. The popliteal vessels are the deepest and usually the largest caliber vessels you will see, but may be difficult to image initially. Make slight adjustments in the probe’s position and angle and be sure the depth setting is adequate. As a landmark, you may see the bony cortex of the distal femur (or less likely proximal tibia) in the far field just beyond the popliteal vessels.

Apply slow, even pressure with the transducer. The popliteal vein should compress and disappear, similar to the common femoral vein above. Compression of the popliteal vein in the popliteal fossa comprises the second point of the 2-point technique. If this vessel collapses freely, a DVT at this position is ruled out.

Interpreting your findings

Negative

If both the common femoral vein and popliteal vein are freely compressible, proximal DVT can be considered

ruled out. If the patient is still symptomatic after one week, it is reasonable to repeat the same study to check for proximal extension of a calf vein DVT to above the knee. As mentioned, emphasis is placed on identifying and treating a proximal DVT, since these have a far greater capacity to embolize to the lungs.

Positive

How will a clot appear if the patient has a DVT? Most DVTs will appear as a circular or ovoid mass that partly or completely fills the lumen of the affected vein. If the clot is completely obstructing the vein, little or no remaining lumen will be visible and compression of the structure will not collapse the vein at all. In these cases, it may be difficult to differentiate the thrombosed vein from the surrounding soft tissue, as the clot may have a similar echogenicity. If the clot does not completely obstruct the vessel, a hypoechoic rim of venous blood may be seen around part of the thrombus. An example of a DVT in the CFV with visible thrombus is shown in Figure 6.

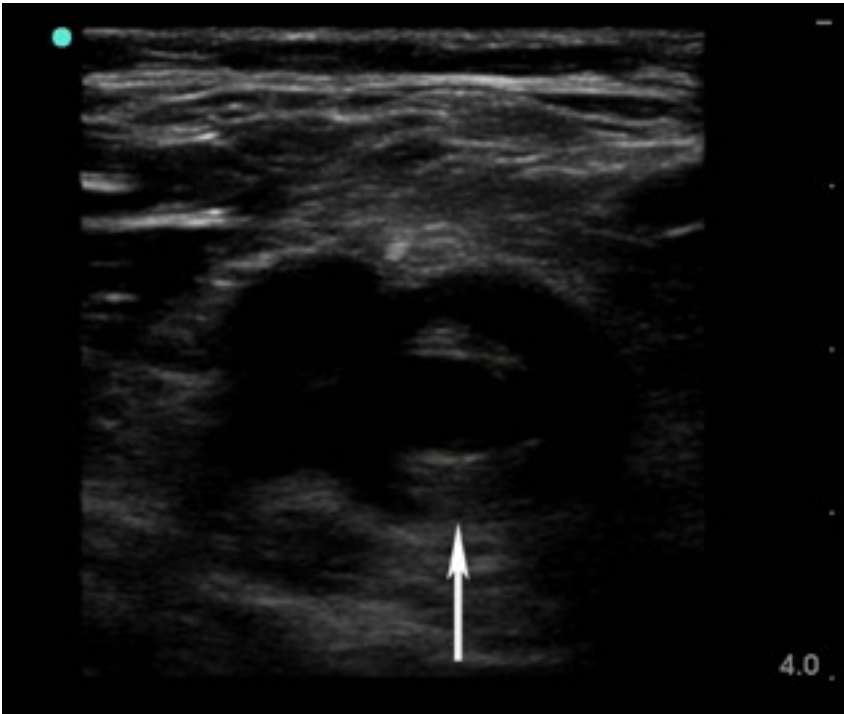


Figure 6. DVT (arrow) in the common femoral vein.

Compression will usually cause the vein to collapse slightly and hug the clot as further pressure is applied. Any amount of thrombus within the popliteal vein or CFV is considered to be a DVT. In many cases of DVT, the clot itself may be relatively hypoechoic, appearing nearly the same echodensity as fluid. In these cases, simply visualizing the lumen of the vein, without using compression to confirm collapsibility, could result in a

missed diagnosis. This fact underscores the central role that compression plays in this technique.

Tips

- When scanning the femoral vessels, ideally the junction of the greater saphenous vein with the CFV should be visualized, since in rare cases a DVT may form in the saphenous vein and extend into the CFV. The saphenous vein at the sapheno-femoral junction appears as a seagull arising medially from the main body of the CFV, as shown in Figure 7.

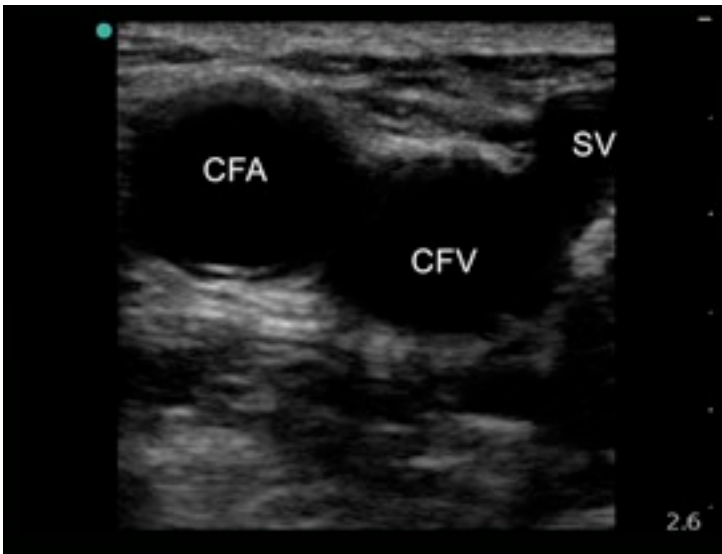


Figure 7. Junction of the saphenous vein (SV) and the common femoral vein (CFV).

- The popliteal region is more difficult to visualize than the femoral region, often because the sonographer presses with too much force while looking for the vessels and unintentionally collapses the popliteal vein before it is visualized. Using a very light touch to avoid unintentional compression, ensuring that the knee is not fully extended, and placing the patient in a slight reverse Trendelenberg position may assist you in acquiring images of the popliteal vessels.
- Normal compressibility of a vein proves only that there is no DVT at that point. A clot in the CFV, for instance, would not create enough hydrostatic pressure to impede compression of the veins below it. Thus, observing normal compressibility in the popliteal region does not eliminate the possibility of a clot in the femoral region, and *vice versa*.
- Despite its name, the superficial femoral vein is part of the deep venous system. Some textbooks now refer to this vessel as simply the femoral vein to avoid confusion. If a thrombus is found in this vessel, it should be considered a DVT and treated as such.
- Lymph nodes occur in close proximity to the femoral vessels and may be easily mistaken for a DVT. Scan

carefully and identify the paired femoral artery and vein in order to distinguish a lymph node from a clotted femoral vein. An example ultrasound image of a lymph node is shown in Figure 8.

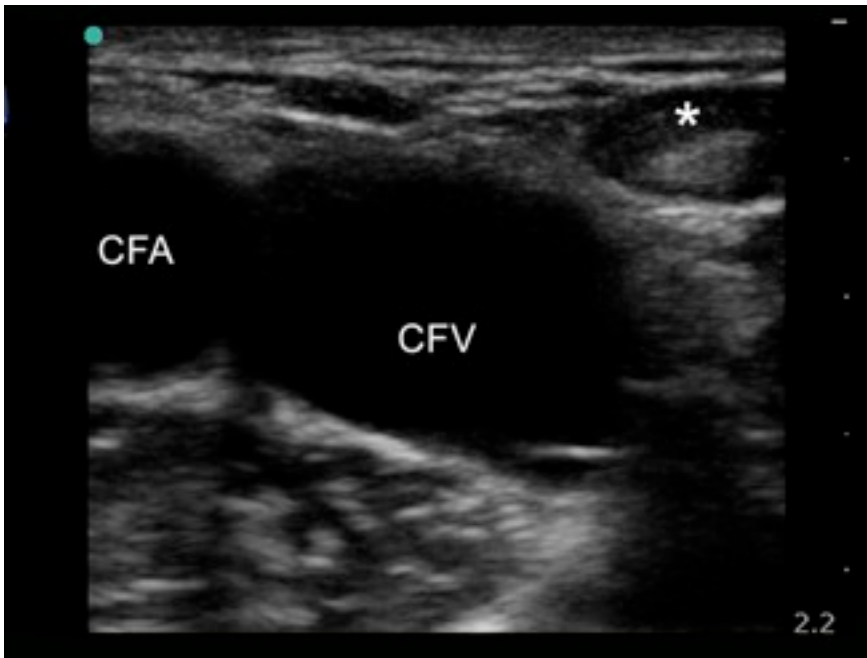


Figure 8. Lymph nodes (*) can be mistaken for DVT.

- Baker's cysts can occur in the popliteal fossa and may be mistaken for a DVT. Like a DVT, a Baker's cyst is noncompressible but is much larger than a DVT and can usually be easily palpated without ultrasound.

Conclusions

A 2 point technique for ultrasound assessment of deep venous thrombosis is a useful exam in resource-limited settings and should be performed in cases of leg pain, swelling or suspected DVT.

Recommended Reading

1. Andrews EJ, Fleischer AC. Sonography for deep venous thrombosis: current and future applications. *Ultrasound Q*. 2005;21(4):213-225.
2. Bernardi E, Camporese G, Büller HR, et al. Serial 2-point ultrasonography plus D-dimer vs whole-leg color-coded Doppler ultrasonography for diagnosing suspected symptomatic deep vein thrombosis: a randomized controlled trial. *JAMA*. 2008;300(14):1653-1659.
3. Frazee BW, Snoey ER, Levitt A. Emergency Department compression ultrasound to diagnose proximal deep vein thrombosis. *J Emerg Med*. 2001;20(2):107-112.
4. Goodacre S, Sampson F, Thomas S, van Beek E, Sutton A. Systematic review and meta-analysis of the diagnostic accuracy of ultrasonography for deep vein thrombosis. *BMC Med Imaging*. 2005;5:6.

5. Jacoby J, Cesta M, Axelband J, et al. Can emergency medicine residents detect acute deep venous thrombosis with a limited, two-site ultrasound examination? *J Emerg Med.* 2007;32(2):197-200.
6. Kline JA, O'Malley PM, Tayal VS, Snead GR, Mitchell AM. Emergency clinician-performed compression ultrasonography for deep venous thrombosis of the lower extremity. *Ann Emerg Med.* 2008;52(4):437-445.
7. Prandoni P, Cogo A, Bernardi E, et al. A simple ultrasound approach for detection of recurrent proximal-vein thrombosis. *Circulation.* 1993;88(4 Pt 1):1730-1735.
8. Zierler BK. Ultrasonography and Diagnosis of Venous Thromboembolism. *Circulation.* 2004;109(12_suppl_1):I-9-14.

Volume status

ADAM LEVINE MD, MPH

Introduction

Assessment of a patient's volume status is one of the first important goals in resuscitation of a critically ill or injured patient. Ultrasound imaging of the inferior vena cava (IVC) can be used to estimate a patient's volume status, and to help guide resuscitative efforts. Consider ultrasound of the IVC in patients presenting with dizziness, orthostatic symptoms, vomiting and diarrhea, shock, trauma, or other causes of suspected dehydration or hypovolemia.

Physiology

The IVC is a large, thin walled vessel that carries blood back from the lower extremities and the abdomen to the right atrium of the heart. As a thin walled vessel, it has

the ability to expand and contract based on the volume of blood running through it at any point in time. As a patient's overall blood volume increases, the IVC will increase in size, and as the patient's blood volume decreases, the size of the IVC will decrease.

The IVC also varies in size with breathing. During inspiration, negative pressure is created in the chest cavity. This causes air to rush into the lungs. The negative pressure also causes blood from other parts of the body to rush back into the chest, leading to increased venous return to the heart. As a result, the blood volume in the abdominal portion of the IVC will briefly decrease during inspiration, causing the abdominal IVC to decrease in size. During expiration, positive pressure is created in the chest cavity, which decreases venous return to the heart. As a result, the abdominal portion of the IVC will increase in size with expiration. The variation in IVC diameter can be estimated by calculating the Caval Index:

$$\text{Caval Index} = \frac{\text{IVC expiratory diameter} - \text{IVC inspiratory diameter}}{\text{IVC expiratory diameter}}$$

The Caval Index is usually written as a percentage between 0% (no change in IVC size with inspiration) and 100% (complete collapse of the IVC with inspiration).

The Caval Index can also be an important tool for estimating a patient's volume status. As a patient's overall blood volume decreases, the proportion of blood in the abdominal IVC that rushes into the chest with each breath will increase. There is the same venous return to the heart, but there is a decreased amount of blood in the abdominal IVC to start with. So, the proportionate change in abdominal IVC volume with each breath will be greater. As a patient's blood volume decreases, their Caval Index will increase. Alternatively, as a patient becomes fluid overloaded, their Caval Index will decrease, because the IVC exhibits little change with each breath.

Applications

There are several clinical applications for ultrasound measurement of the IVC. First, it can be used to estimate volume status in patients with severe sepsis. Perhaps the most important initial treatment for septic patients is to provide intravenous fluids (normal saline or lactated

ringers) to increase their central venous pressure (CVP) to a normal level (8-12 mmHg). While CVP can be measured directly by placing a central venous catheter with its tip in the right atrium, providers in pre-hospital, rural, or developing world settings may not have access to this technology. Several studies have found that both IVC size and CI correlate well with CVP. These studies included patients suffering from sepsis and dehydration in intensive care units and emergency departments. For further details, please see the recommended reading list at the end of the chapter. In summary, IVC size and Caval Index are highly sensitive for identifying patients who are volume depleted and who will respond well to fluid boluses. Table 1 shows a rough estimate of CVP based on initial IVC size and CI.

IVC size (cm)	Respiratory Change	CVP (cm)
< 1.5	Total collapse	0-5
1.5-2.5	> 50% collapse	5-10
1.5-2.5	< 50% collapse	11-15
> 2.5	< 50% collapse	16-20
> 2.5	No change	> 20

Table 1. Estimates of CVP based on respiratory change and IVC size

Another important application of IVC ultrasound is determining blood loss in trauma patients. Young healthy patients may not develop hypotension until they have lost a significant amount of blood volume, and hemoglobin may be normal early on despite significant blood loss. Several studies support the idea that a smaller IVC diameter in trauma patients correlates well with significant blood loss and suggests that this may be a more sensitive indicator than elevated heart rate. In trauma patients, multiple measurements of the IVC may be most useful in evaluating blood loss over time.

Ultrasound measurement of the IVC can also be used to help in the initial assessment of patients with undifferentiated shock. Patients with cardiogenic shock will have a large IVC and a small CI. Those with hemorrhagic or septic shock will have a small IVC and a large CI. Finally, there is ongoing research into the use of ultrasound to measure volume status in children — especially those with dehydration due to diarrhea. The aorta provides an internal control for IVC, since it does not change much in size with dehydration.

Technique

1. Place the abdominal probe in the patient's midline with the marker pointed towards the patient's right, just inferior to the xyphoid process (Figure 1).

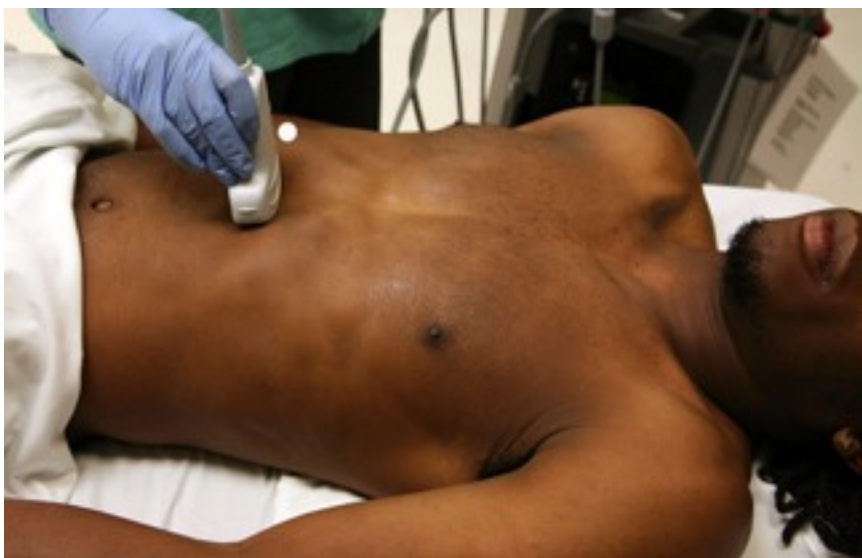

Figure 1. Abdominal transducer in transverse orientation with the index (•)marker to the patient's right

2. In this position, you should see the left lobe of the liver at the top of the screen and the vertebral shadow at the bottom (see Figure 2). The aorta will be a circular structure just above the vertebral shadow. If you have trouble finding it, try using color Doppler. The IVC will be just to the right and runs through the

liver. It will be circular to oval in shape depending on the degree of dehydration and the angle of the probe.

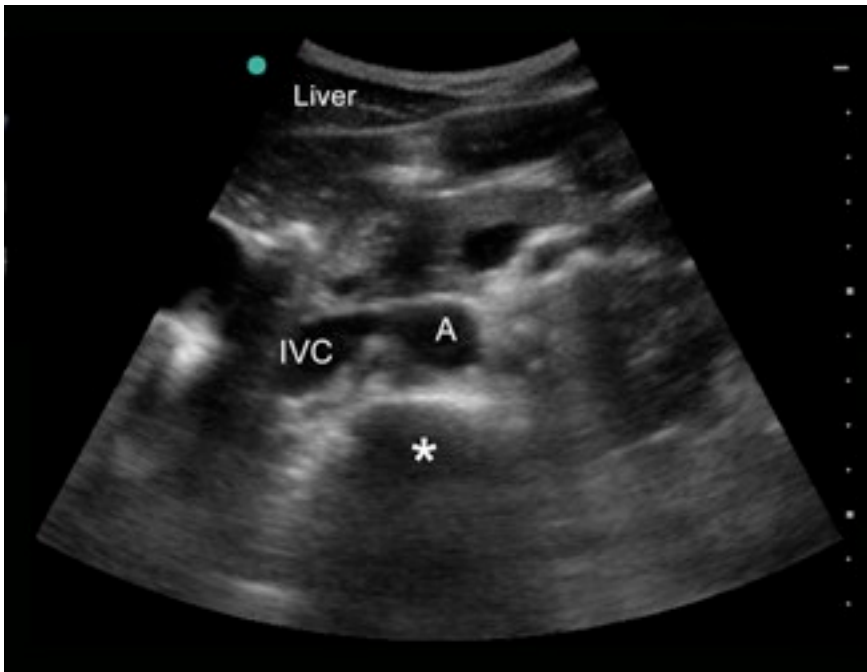


Figure 2. Transverse view of the upper abdomen showing the IVC and aorta (A) overlying a vertebral body (*) with the liver in the near field.

3. If your view is obstructed by bowel gas, you can press down *gently* to disperse the gas.
4. To obtain a longitudinal view of the IVC (Figure 3), center the IVC in the middle of the screen. Then rotate the probe 90 degrees, so that the marker is pointed towards the patient's head.

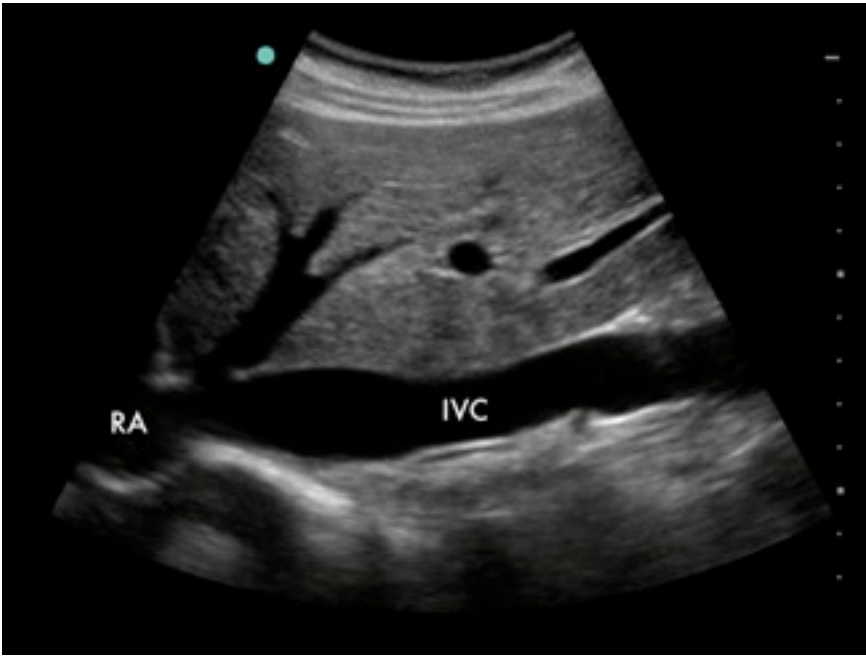

Figure 3. Longitudinal view of the IVC emptying into the right atrium (RA)

5. Rock the probe slightly until you can see the IVC empty into the right atrium of the heart. This allows differentiation of the IVC from the descending aorta, which passes posterior to the heart.
6. Freeze the image and use the cine function to scroll back image by image until the IVC diameter appears largest (this will be during a period of expiration for a non-intubated patient, or during forced inspiration for an intubated patient). Use the calipers to measure the

anterior-posterior diameter of the IVC 2-3 cm distal to the right atrial border. Measure from inner wall to inner wall. This will be the IVC expiratory measurement, or IVCe (Figure 4).

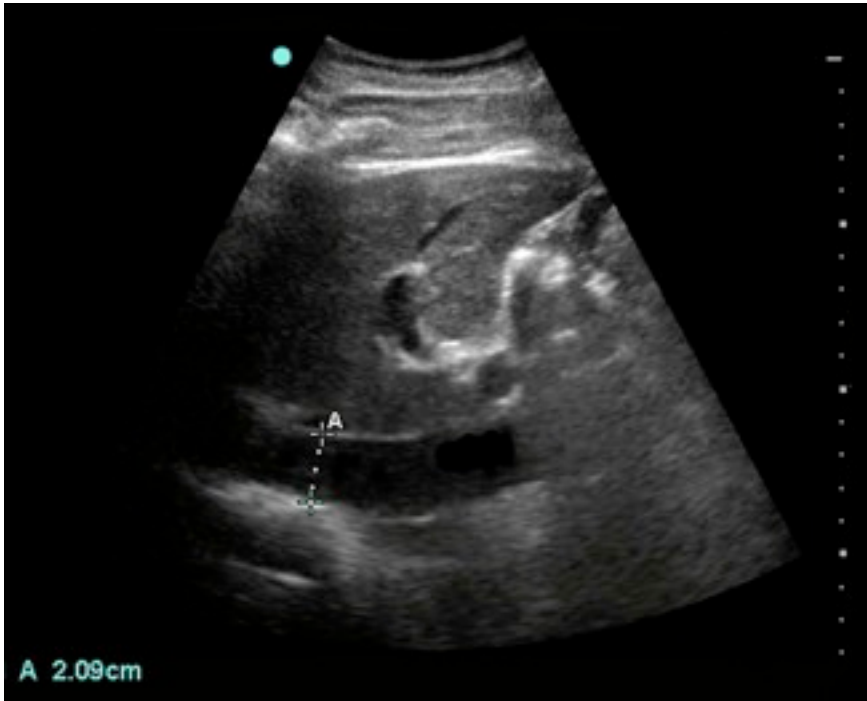

Figure 4. Transverse view of the IVC during expiration. The anterior-posterior diameter measures 2.09 cm.

7. Continue to scroll backwards until you find the IVC at its smallest width (during inspiration for a non-intubated patient and during expiration for an intubated patient). Use the calipers to measure the

anterior-posterior diameter of the IVC. Measure from inner wall to inner wall. This will be the IVC-inspiratory measurement, or IVCi (Figure 5).

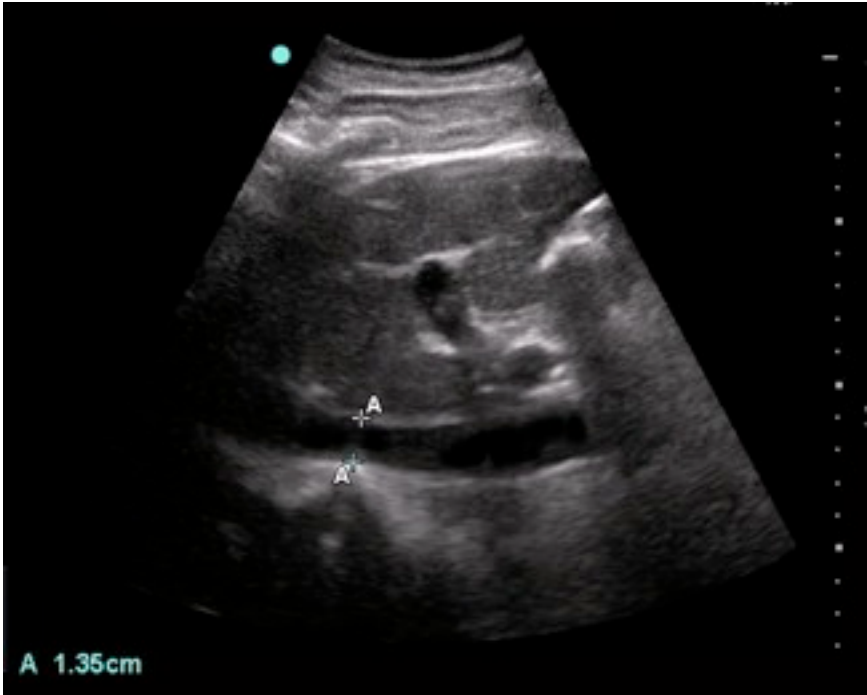

Figure 5. Transverse view of the IVC during inspiration. The anterior-posterior diameter measures 1.35 cm.

8. Use the following equation to calculate the Caval Index from the measurements that you have taken:

Conclusion

Accurately assessing volume status is critically important in many clinical scenarios — from trauma patients to septic patients to those with undifferentiated shock. Ultrasound of the IVC can be an important tool for helping clinicians assess volume status, especially in critically ill patients and in settings where direct measures of central venous pressure are not available.

Recommended reading

1. Kircher BJ, Himelman RB, Schiller NB. Noninvasive estimation of right atrial pressure from the inspiratory collapse of the inferior vena cava. *Am J Cardiol* 1990;66:493-6.
2. Feissel M, Michard F, Faller JP, et al. The respiratory variation in inferior vena cava diameter as a guide to fluid therapy. *Intensive Care Med* 2004;30:1834-7.
3. Nagdev AD, Merchant RC, Tirado-Gonzalez A, et al. Emergency department bedside ultrasonographic measurement of the caval index for noninvasive determination of low central venous pressure. *Ann Emerg Med* 2010;55:290-5.

4. Lyon M, Blaivas M, Brannam L. Sonographic measurement of the inferior vena cava as a marker of blood loss. *Am J Emerg Med* 2005;23:45-50.
5. Yanagawa Y, Sakamoto T, Okada Y. Hypovolemic shock evaluated by sonographic measurement of the inferior vena cava during resuscitation in trauma patients. *J Trauma* 2007;63:1245-8; discussion 1248.
6. Levine AC, Shah SP, Umulisa I MR, et al. Ultrasound assessment of severe dehydration in children with diarrhea and vomiting. *Acad Emerg Med* 2010 (accepted for publication).

Bladder

OTTO LIEBMANN MD

Introduction

Ultrasound trained healthcare providers can use bedside ultrasound to measure bladder volume and to select the optimal location for suprapubic bladder catheterization. Bladder volume assessment prior to catheterization of infants and children improves success rates and reduces repeat catheterization. Ultrasound can be diagnostic in suspected urinary retention and may aid in the performance of suprapubic catheterization when urethral catheterization has failed.

Clinical applications

- Identify adequate urine volume prior to catheterization

- Estimate post-void residual in urinary retention
- Guide suprapubic catheterization

Sonographic findings

The bladder can be identified as a hypoechoic structure in the pelvis posterior and caudad to the superior pubic ramus, as seen in Figure 1.

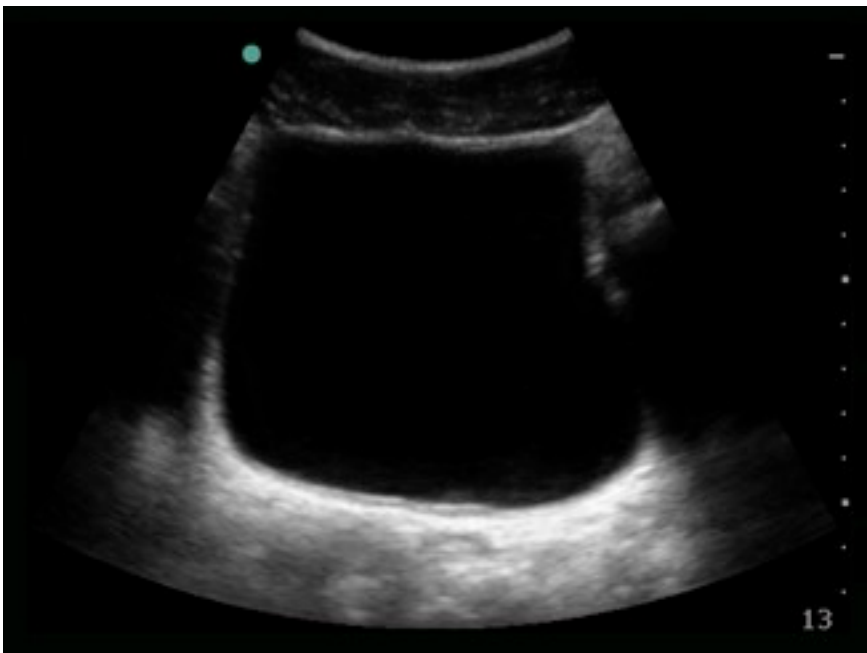


Figure 1. Bladder in transverse view

When completely empty, the bladder will be difficult to visualize due to surrounding bowel gas.

Technique

Bladder volume

1. Place the curvilinear transducer just above the pubic ramus with the index marker towards the patient's right. This is the transverse plane.
2. Fan the probe caudad to localize the bladder in the pelvis, as shown in Figure 2.

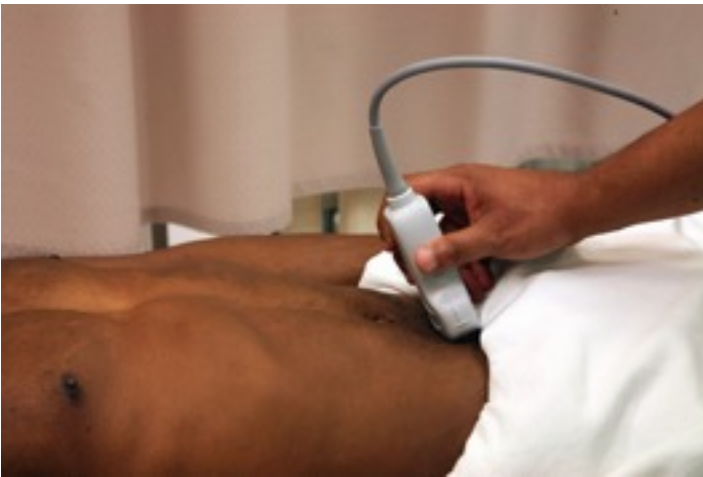
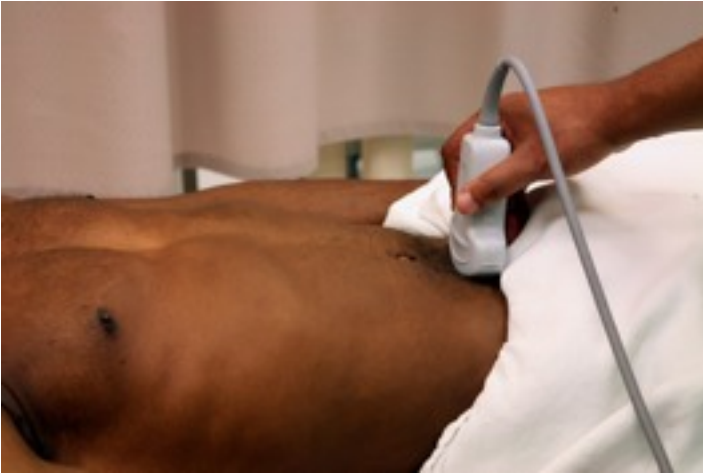
Figure 2. Probe position for bladder imaging

3. Measure the bladder dimensions using the calipers from the top to bottom and from left to right of the screen, as shown in Figure 3. These are the depth and width of the bladder, respectively.

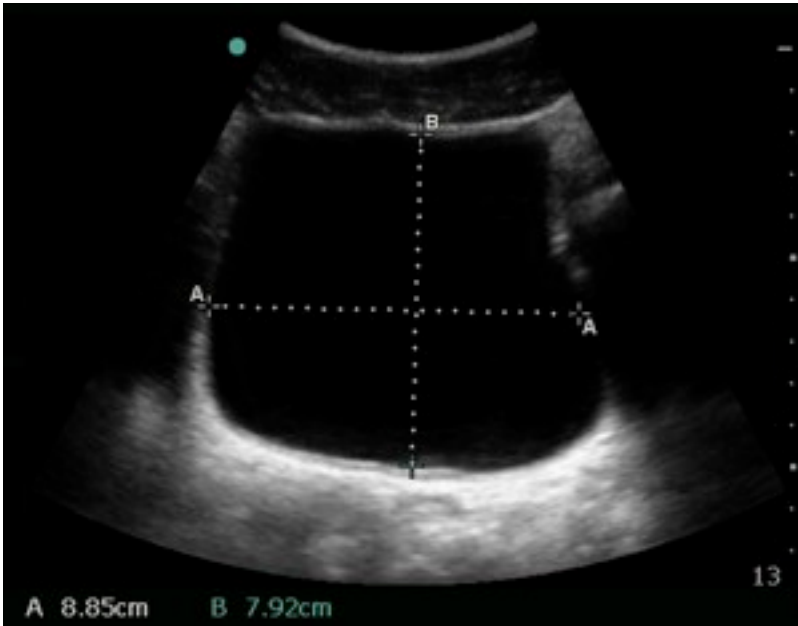


Figure 3. Bladder measurement of depth and width using calipers

4. Rotate the probe so that the index marker is pointed towards the patient's head, as shown in Figure 4. This is the longitudinal, or long axis view.

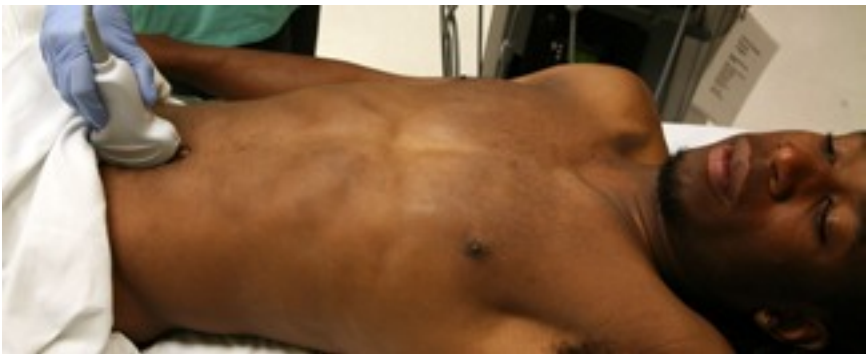

Figure 4. Probe position for long axis view of the bladder

5. Measure the bladder dimension from the left to right of the screen. This is the height of the bladder from cephalad to caudad, as demonstrated in Figure 5.

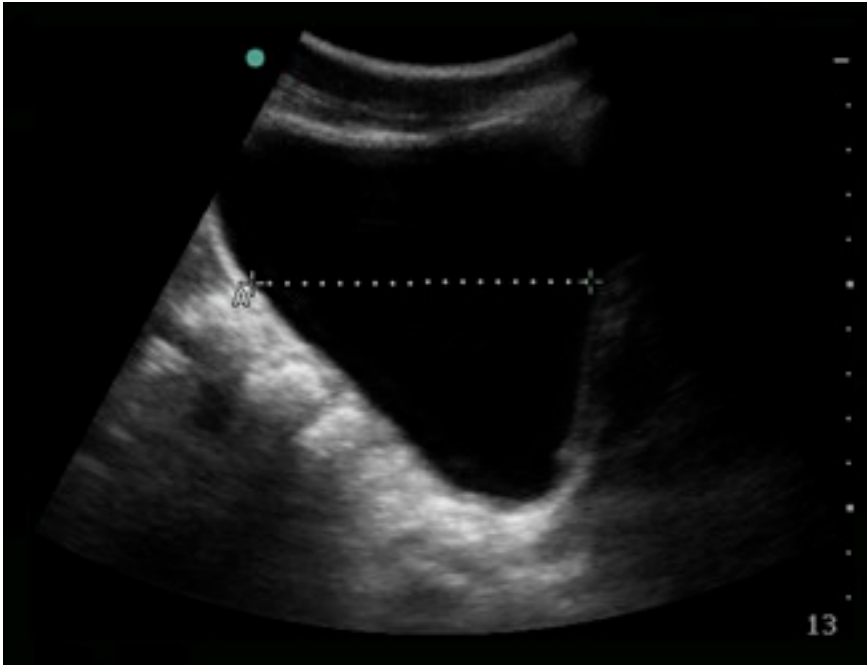


Figure 5. Cephalad-Caudad dimension of bladder in long axis

Bladder volume calculations:

The product of bladder width, height, and depth estimates bladder volume. This method overestimates volume by approximately 15%. If a urine sample is necessary, a minimal transverse diameter (width) greater than 2 cm corresponds to a bladder volume greater than

2-3 mL. This volume is adequate for urinalysis and urine culture.

Ultrasound-guidance for Suprapubic Catheterization

Ultrasound may be used to select the optimal location for suprapubic catheterization. There are two methods. In the “mark-and-stick” method, the skin is marked where the bladder approximates the abdominal wall prior to blind catheterization at this location. The second method involves real time guidance. The ultrasound probe is placed lateral to the point of insertion with a diagonal orientation to visualize and direct the procedure as it is being performed, as shown in Figure 6.

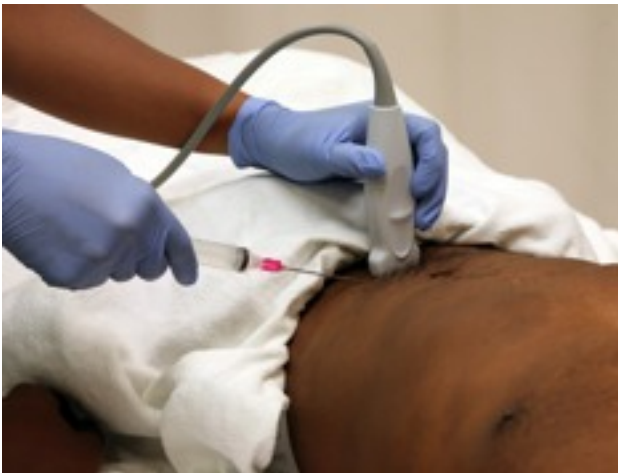

Figure 6. Real time technique for suprapubic bladder tap

Conclusions

Ultrasound may be used to estimate bladder volume and facilitate suprapubic catheterization. Ultrasound reliably estimates bladder volume, provides diagnostic information, and improves success rates when performed prior to catheterization for urine sample.

Recommended reading

1. Aguilera PA, Choi T, Durham BA. Ultrasound-guided suprapubic cystostomy catheter placement in the emergency department. *J Emerg Med* 2004;26:319-21.
2. Chen L, Hsiao AL, Moore CL, et al. Utility of bedside bladder ultrasound before urethral catheterization in young children. *Pediatrics* 2005;115:108-11.
3. Milling TJ Jr, Van Amerongen R, Melville L, et al. Use of ultrasonography to identify infants for whom urinary catheterization will be unsuccessful because of insufficient urine volume: validation of the urinary bladder index. *Ann Emerg Med* 2005;45:510-3.

Skin

BRITA ZAIA MD

Introduction

Generalist physicians and health care providers frequently encounter skin and soft tissue infections and foreign bodies in their practices. Ultrasound is useful in evaluating, diagnosing, and treating these conditions.

Infections

Skin and soft tissue infections are common, and distinguishing between simple cellulitis and a superficial or deep space abscess is critical to effective treatment and improved patient outcome. In most cases, the diagnosis of cellulitis can be made by physical examination alone, especially when redness, increased warmth, and tenderness are present. Similarly, a superficial abscess may be easily diagnosed in the

presence of swelling, fluctuance, and tenderness with or without active drainage of pus. There are cases in which the diagnosis of an abscess is less clear. For example, an abscess may be too small or too deep to be detected on physical examination. When the affected region involves an area of pre-existing scar tissue from prior abscess drainage, other surgical procedures, or trauma, it can be difficult to determine the presence of an abscess by physical exam. Pyomyositis, an infection of the skeletal muscle, can also be a difficult diagnosis to make by history and physical examination alone, because this is a deep tissue infection that may not have overlying skin changes.

Ultrasound is extremely helpful in detection of superficial and deep space abscesses when the clinical information is unclear. Even when the diagnosis of an abscess is obvious, ultrasound can help locate the best site for incision and drainage or aspiration of the abscess. After the procedure, ultrasound can be used to confirm adequate drainage or aspiration of the abscess.

Clinical applications

- Detection of cellulitis

- Detection of abscess
- Localization of the optimal site for abscess incision and drainage or aspiration
- Post-procedural confirmation of adequate drainage or aspiration

Ultrasound findings

Normal skin

Normal soft tissue maintains a regular, linear appearance on ultrasound, as shown in Figure 1. There are clear boundaries between the skin that lies immediately below the transducer at the top of the screen, the subcutaneous tissue and fat beneath the skin, and the deeper underlying fascia and connective tissue.

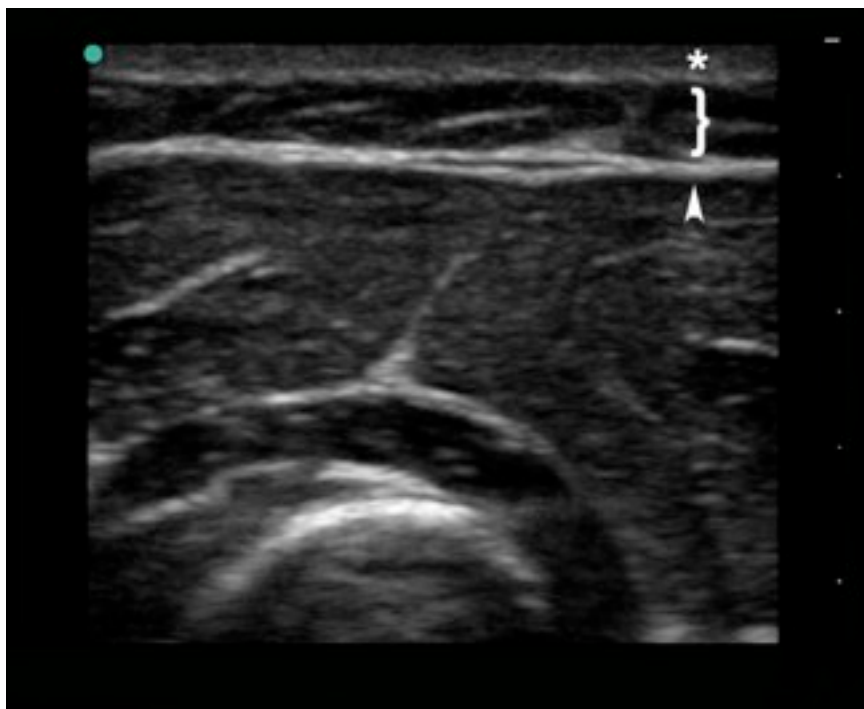

Figure 1. Transverse view of the forearm showing normal skin (*), subcutaneous tissue (}) and fascia (arrowhead). The bone in the far field is the radius.

Cellulitis

Ultrasonographic findings in cellulitis result from edema or swelling, as seen in Figure 2. These findings include:

- Increased distance between skin and the underlying tissue planes or bone due to swelling, when compared to unaffected tissue

- A characteristic cobblestone appearance with hypoechoic edema in the subcutaneous tissue layer

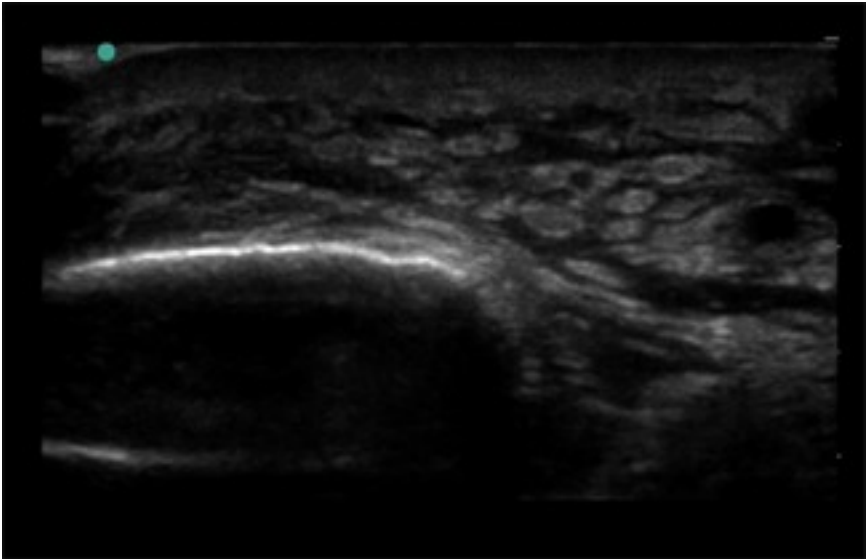


Figure 2. Cellulitis is evidenced by a cobblestone appearance of edema between the tissue layers.

Abscess

Abscesses are seen as hypoechoic or anechoic fluid collections that are often round or oval (Figure 3). The inside of these collections vary, and may range from black to shades of gray or even white, and may contain hyperechoic material.

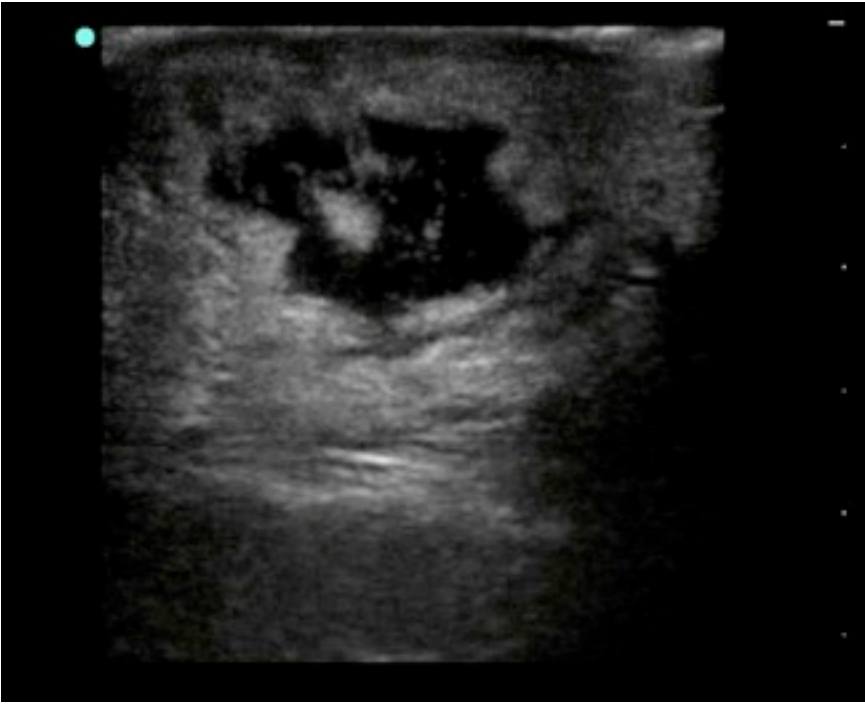

Figure 3. An abscess appears as a hypoechoic fluid collection.

Pyomyositis

Ultrasonographic findings of pyomyositis include the presence of hypoechoic or anechoic abscess cavities and/or edema within skeletal muscle layers. It is useful to compare to the normal contralateral side.

Technique

For this ultrasound exam, use the linear transducer (Figure 4). To start, the index marker should point toward the patient's right side in a transverse plane or toward the head in a longitudinal plane.

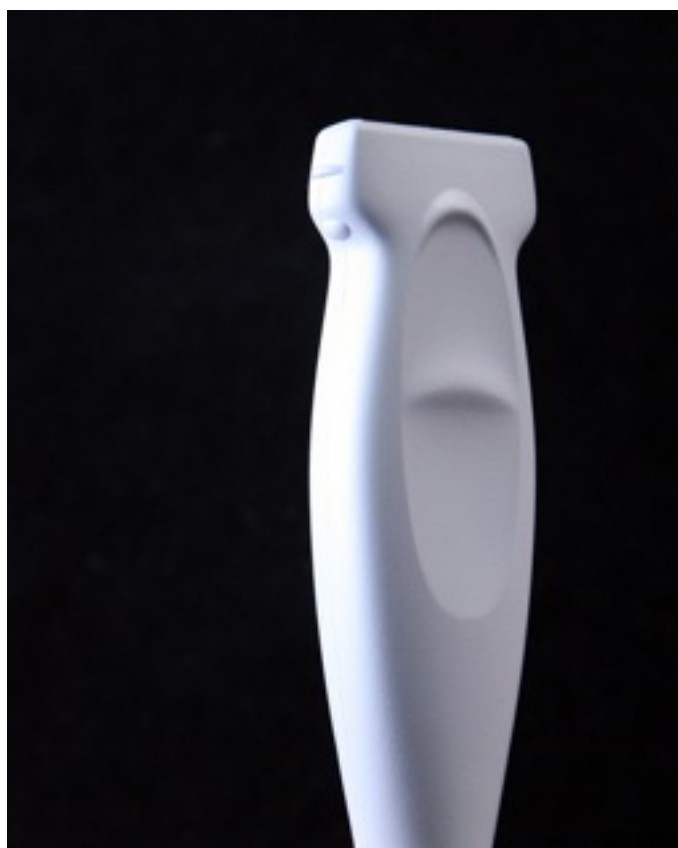

Figure 4. The linear transducer is used to evaluate superficial skin and soft tissue.

Abscesses should be evaluated in two planes to define the shape and size. The depth of the abscess is estimated by using the depth markers on the side of the image screen. These depth markers help determine how deep to make the incision or position the needle for abscess drainage or aspiration. It is helpful to compare the affected area to an unaffected area on the contralateral side in order to appreciate deviation from the patient's normal anatomy. For very superficial infections, a standoff pad may be used to optimize image quality (see Foreign body section below).

Step by step approach

1. Place the linear transducer over the unaffected, contralateral body part to define normal anatomy. For example, if you suspect an abscess in the right arm, first place the ultrasound transducer on the left arm to see normal anatomy.
2. Place the linear transducer over the affected area with the index marker towards the patient's right. This is the transverse plane.

3. Look for an abnormal area of edema or fluid collection, representing cellulitis and/or abscess.
4. Once the affected area is localized, visualize it along the entire plane. To do this, hold the probe in the transverse position, and simply move the probe upward towards the patient's head, then downward towards the patient's feet until you can no longer see the area of cellulitis or abscess in both directions. Do this slowly while watching the screen in order to see the entire area in this plane and determine its size.
5. Now scan the area of cellulitis and/or abscess in the other plane, the longitudinal plane. Place the linear transducer over the affected area with the index marker towards the patient's head. This is the sagittal plane.
6. Repeat step 4, but instead of moving the probe up and down, keep the probe in the same longitudinal position, and move the probe toward the patient's right and then left to visualize the area entirely in this plane and determine its size.
7. Determine the depth of the abscess by holding the probe over the deepest part of the abscess and

looking at the depth markers on the side of the image screen (Figure 5).

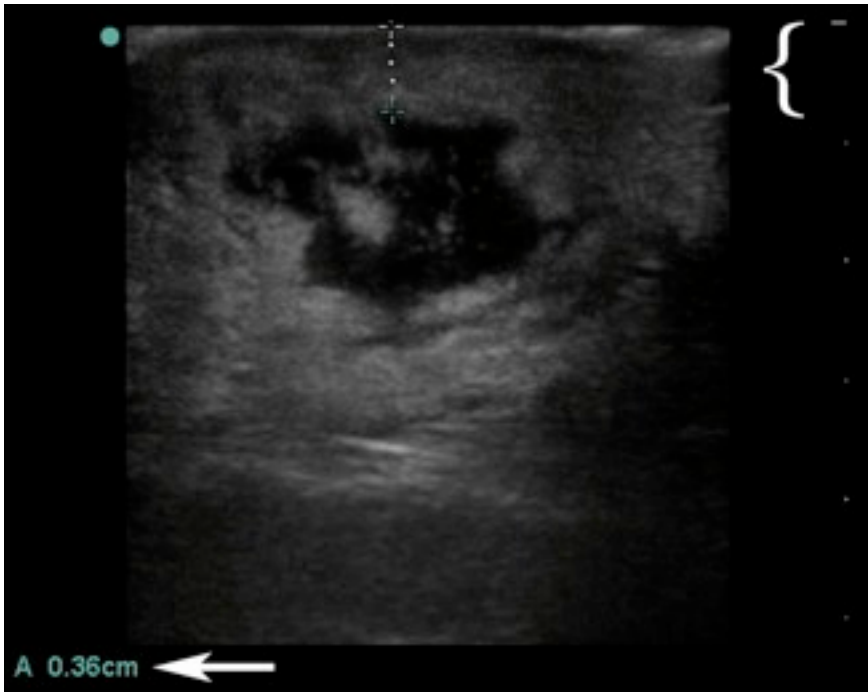

Figure 5. Depth markers on the right side of the screen help to estimate the depth of the abscess cavity. Depth can also be measured with calipers. The measurement appears in the lower left corner (arrow).

8. If unsure of the liquid nature of the fluid collection, place gentle pressure over the abscess with the transducer to induce motion of the purulent material within the abscess, which can be visualized on the screen.

Foreign bodies

Diagnosing and localizing foreign bodies can be challenging. Some foreign bodies are easily seen on x-ray or even physical exam, while others are not. Missed or retained foreign bodies can lead to severe infections as well as long term pain and disability.

Clinical applications

- Detection of foreign body
- Localization of foreign body for removal
- Post-procedural confirmation of adequate foreign body removal

Ultrasound findings

Foreign bodies can have many different appearances on ultrasound. Some foreign bodies visible on ultrasound, may be missed on plain radiography. Foreign bodies such as wood, glass, metal, plastic, and gravel often appear bright and hyperechoic. Occasionally, there is a dark, hypoechoic shadow artifact that can be seen

below the object on the screen. This shadow looks similar to the shadow produced by a gallstone and may help to localize the foreign body. Metal objects may produce a bright white, hyperechoic reverberation artifact, as seen in Figure 6.

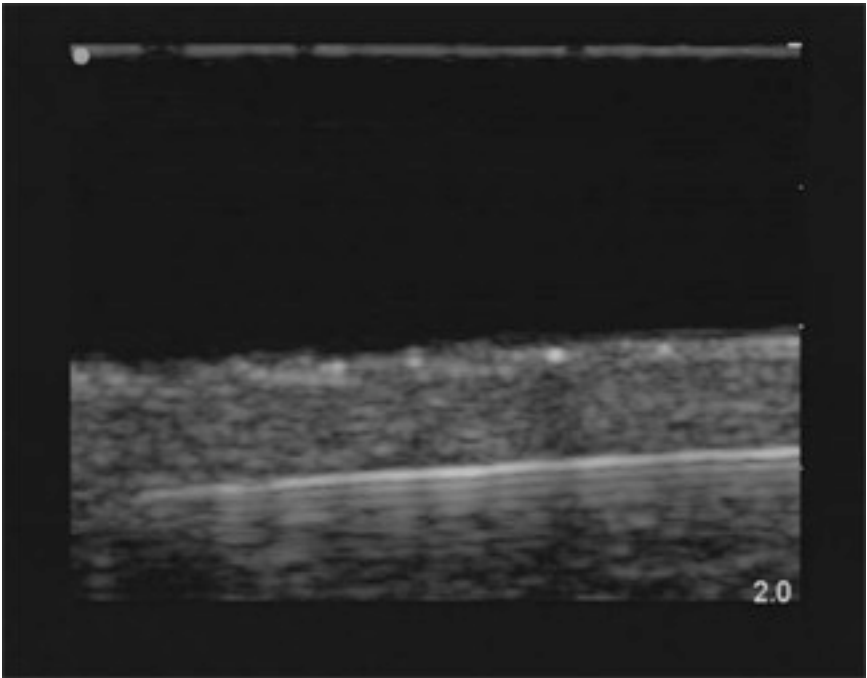


Figure 6. Longitudinal view of a needle foreign body in the leg. Note the reverberation artifact deep to the needle. The black area in the near field represents the use of a stand-off pad (see Figure 7).

Step by step approach

1. Place the linear transducer over the area with the suspected or known foreign body with the index marker towards the patient's right. This is the transverse plane.
2. Localize the foreign body. This can be the most difficult step.
3. Once you locate the foreign body, follow the same steps for skin and soft tissue infections in order to fully visualize the foreign body in two planes and determine its size, shape, depth and orientation.
4. The use of a "stand-off pad" may be necessary to adequately image superficial foreign bodies, especially in small body parts such as the hand, fingers, feet, and toes. Standoff pads are used to raise the transducer 1-2 cm above the patient's skin and improve image quality. A stand-off pad can be made by filling a glove with water or gel. It is placed over the affected area of the patient with gel between the skin and the glove. With the transducer on top of the glove, the ultrasound examination is performed to

locate the foreign body. An example of a standoff pad is shown in Figure 7.

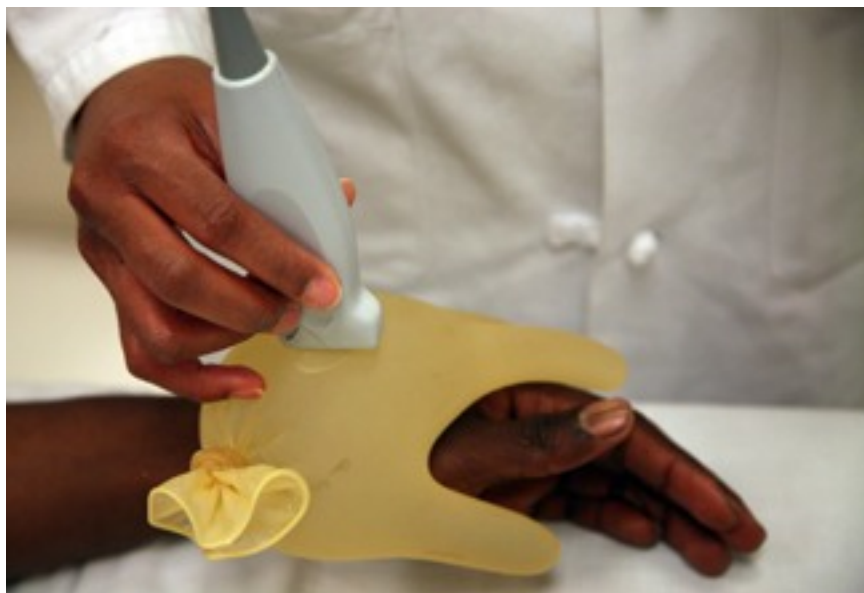


Figure 7. A stand-off pad can be made by filling a glove with water.

Conclusions

Ultrasound is a useful and important tool for evaluating, diagnosing, and guiding treatment of skin and soft tissue infections and foreign bodies. Ultrasound can diagnose cellulitis and help confirm the presence or absence of an abscess, when the physical exam is not definite.

Ultrasound can also aid in the treatment of an abscess

by first locating the largest area of pus to be drained and then confirming adequate removal of pus following incision and drainage or aspiration. Ultrasound can also help locate foreign bodies and aid in foreign body removal.

Recommended Reading

1. Frazee BW, White DAE. Soft Tissue. In: Cosby KS, Kendall JL, eds. *Practical Guide to Emergency Ultrasound*. Philadelphia, PA: Lippincott Williams & Wilkins; 2006:331-351.
2. Dewitz A, Frazee BW. Soft Tissue. Ma OJ, Mateer JR, Blaivas M, eds. *Emergency Ultrasound*. 2nd ed. New York, NY: McGraw Hill; 2008:414-421,439-444.

Procedures

JAMES HWANG MD, RDMS, RDCS

Introduction

Healthcare providers frequently encounter patients with ascites, pleural effusions, and pericardial effusions. The cause for these fluid accumulations are diverse and can range from relatively benign to life threatening. Fluid in the abdomen or thorax can become infected, or when massive, can cause cardiopulmonary compromise. As such, paracentesis, thoracentesis, and pericardiocentesis can be diagnostic and therapeutic. These procedures can also be emergent or non-emergent. Physical examination is not sensitive for detecting intra-abdominal or intra-thoracic fluid and cannot reliably determine the best site for drainage. Clinician performed bedside ultrasound can easily and reliably identify fluid in the abdomen or chest and can aid in choosing the safest site for its removal. While these procedures are

often performed “blindly” using the landmark technique, ultrasound can be used to increase the success rate and to decrease the complication rate.

Paracentesis

The physical exam findings of ascites include a distended abdomen, presence of a fluid wave, and shifting dullness on percussion. While physical exam can assess for the presence of ascites, it is limited in terms of its ability to assess the amount of fluid, whether the fluid is loculated, or where the largest pocket of fluid is located. Physical exam cannot assess for underlying bowel, omentum or the nearby inferior epigastric vessels. Paracentesis by the traditional landmark technique carries an increased risk for bowel puncture, vascular injury and bleeding. Ultrasound is extremely helpful for confirming the presence of ascites, especially when fluid collections are small, and for determining the optimal site for puncture.

Clinical applications

- Detection of ascites

- Identifying the largest pocket of fluid
- Detection of underlying bowel or omentum
- Detection of underlying inferior epigastric vessels
- Determination of distance from the skin surface to the peritoneum
- Post-procedural confirmation of adequate drainage

Ultrasound findings

Ascites: Intraperitoneal fluid typically appears anechoic or hypoechoic, depending on its etiology. The fluid is free flowing within the peritoneum, unless it is loculated. Fluid can be seen in the dependent areas of the abdomen, such as the right upper quadrant and pelvis, and outlines intra-abdominal organs, as shown in Figure 1.

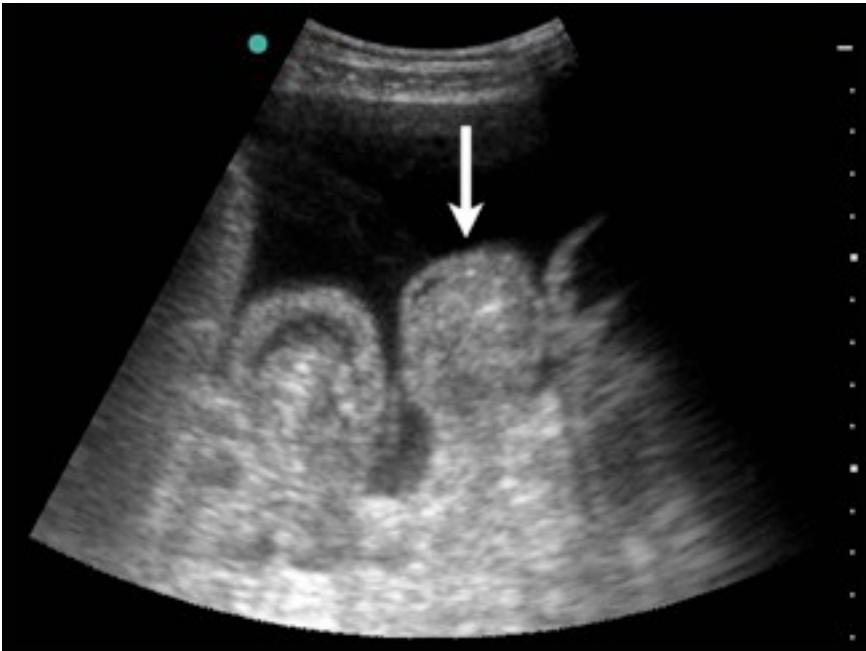


Figure 1. Ascites and bowel (arrow)

Bowel: Usually hyperechoic in appearance, unless filled with fluid, bowel gas can scatter the ultrasound beam, making visualization of distal structures challenging. Ascitic fluid surrounds bowel, and care must be taken not to confuse this with fluid within the bowel.

Bladder: The midline, infraumbilical, fluid-filled bladder is located against the pubic symphysis, as seen in Figure 2.

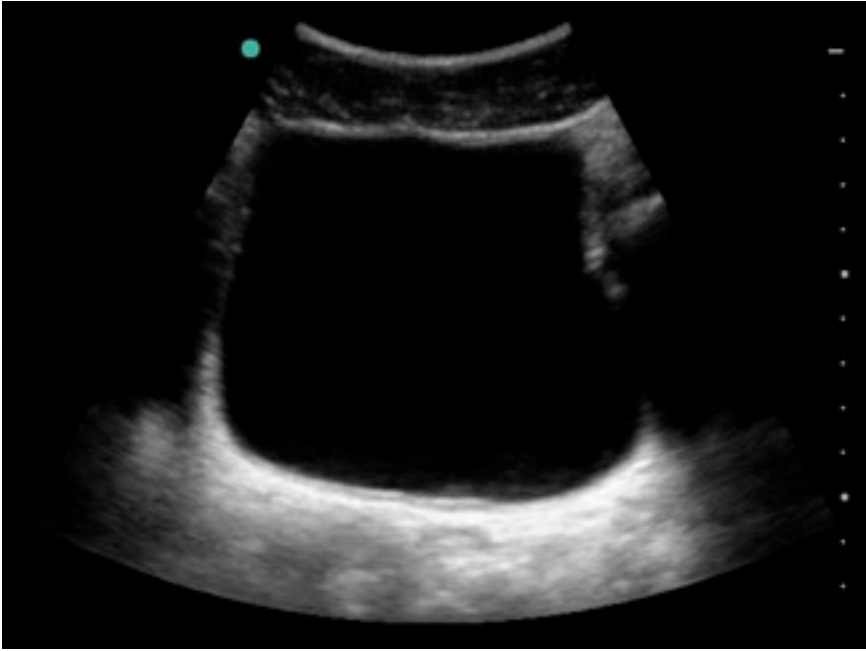


Figure 2. Urinary bladder

Inferior epigastric vessels: These vessels originated from the external iliac vessels and course along the lower, medial abdominal wall and extend toward the lateral border of the rectus muscle. These vessels run along the peritoneum, and blood flow can be confirmed using color flow Doppler.

Technique

To assess for ascites, use the large curved transducer. The index marker should point toward the patient's right

side or toward the head. For the right and left upper quadrant views, a longitudinal view is used. The probe is moved inferior to the kidney to the paracolic gutter to assess for a fluid pocket. For the pelvis, both longitudinal and transverse views should be obtained (Figure 3). After the fluid is identified in the midline, shift the probe laterally to either the right or left lower quadrant to find the largest fluid pocket for puncture.

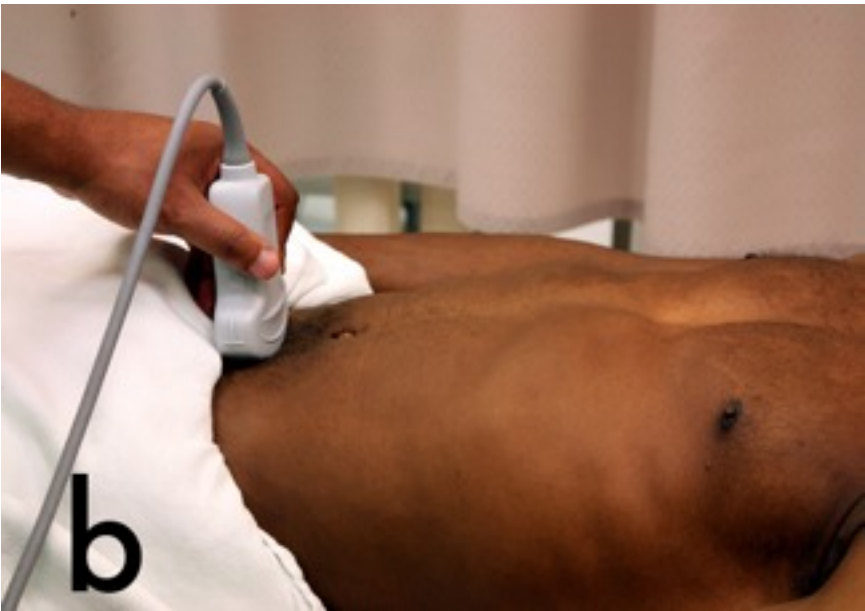
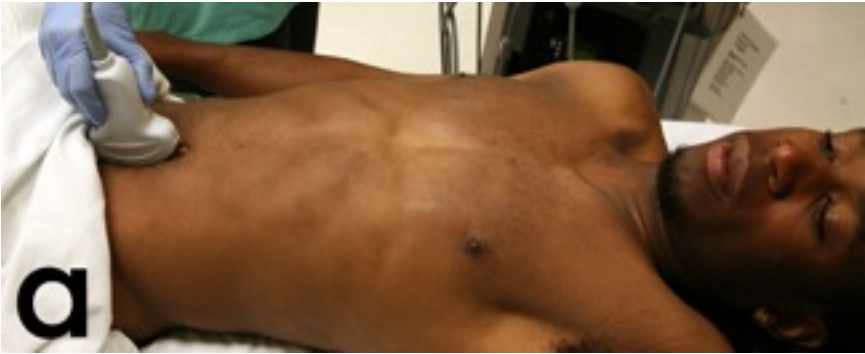
Figure 3. Longitudinal (a) and transverse (b) probe positions for free fluid assessment in the pelvis

Ultrasound guidance may be static or dynamic. If the static approach is used, then the optimal location for puncture is marked in either the right or left lower quadrant and the depth from the skin surface to the

peritoneum is noted. The distance to the peritoneum is estimated by using the depth markers on the side of the screen. If the dynamic approach is used, then the paracentesis needle is visualized as it penetrates down to and through the peritoneum. Real-time guidance allows the clinician to assess for underlying bowel and for adequate needle entry.

Step by step approach

3. Ask the patient to empty his/her bladder by voiding. Then place the patient in the lateral decubitus position or supine with the head slightly elevated.
4. Place the curved transducer in the right and left upper quadrants, and pelvis to assess for ascites, to determine the location of the largest pocket of fluid, and to look for peritoneal adhesions.
5. You may use the curved probe, or switch to the linear transducer to assess for underlying loops of bowel and blood vessels and to estimate the distance from the skin surface to the peritoneum using depth markers on the side of the screen.
6. Prep and drape the patient according to standard sterile procedure protocol.

7. For the static approach, the skin is marked and patient positioning is carefully maintained.
8. For the dynamic approach, the needle tip is visualized with the linear transducer, as it penetrates down to and through the peritoneum, as shown in Figure 4. On ultrasound, the needle appears hyperechoic and produces a reverberation artifact.

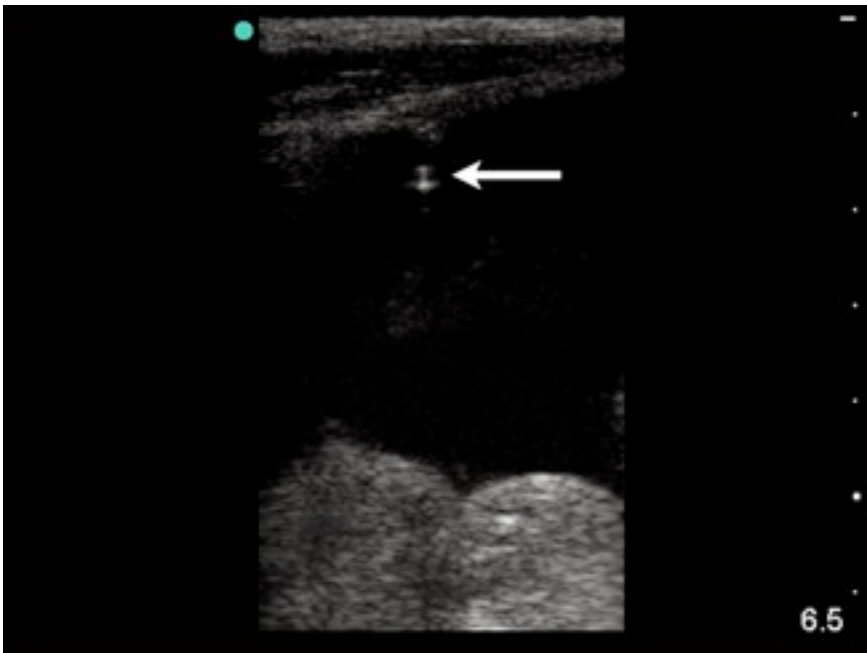


Figure 4. Needle tip (arrow) penetrating the peritoneum

9. Ultrasound can also be used to assess why the catheter may have stopped draining during the procedure or to assess the adequacy of drainage.

Thoracentesis

The physical exam findings of pleural effusions include diminished breath sounds, dullness to percussion, and reduced tactile and vocal fremitus. While physical exam and chest radiography can assess for the presence of pleural fluid, they are limited in their ability to assess the amount of fluid — smaller amounts in particular — and whether the fluid is loculated. Physical exam is limited in its ability to determine the extent of diaphragmatic excursion and cannot assess for underlying adhesions. Thoracentesis by the traditional landmark technique is at increased risk for pneumothorax and for diaphragm puncture and abdominal organ injury. Thoracentesis under ultrasound guidance has a lower complication rate than thoracentesis performed blindly. Ultrasound is extremely helpful for confirming the presence of pleural fluid, especially when fluid collections are small, and for assessing for loculations and adhesions. It may also

differentiate findings noted on chest radiography such as atelectasis, consolidation, or an elevated hemidiaphragm.

Clinical applications

- Detection of the presence of pleural fluid and the location of the largest pocket of fluid
- Identification of the diaphragm and its location throughout the respiratory cycle
- Detection of loculations or underlying adhesions
- Determination of the distance from skin to parietal pleura and from parietal pleura to visceral pleura
- Post-procedural assessment for adequate drainage and for pneumothorax

Ultrasound findings

Ribs: Ribs are hyperechoic structures with associated acoustic shadowing.

Pleural line: A hyperechoic line is formed by opposition of the parietal pleura of the thoracic wall and the visceral pleura of the lung. The parietal and visceral

pleurae can be seen sliding or shimmering against one another during respiration.

Pleural effusion: An effusion typically appears anechoic or hypoechoic depending on its etiology and may have internal echoes. Unless loculated, the fluid is free flowing within the hemithorax and is seen in dependent areas above the diaphragm (Figure 5).

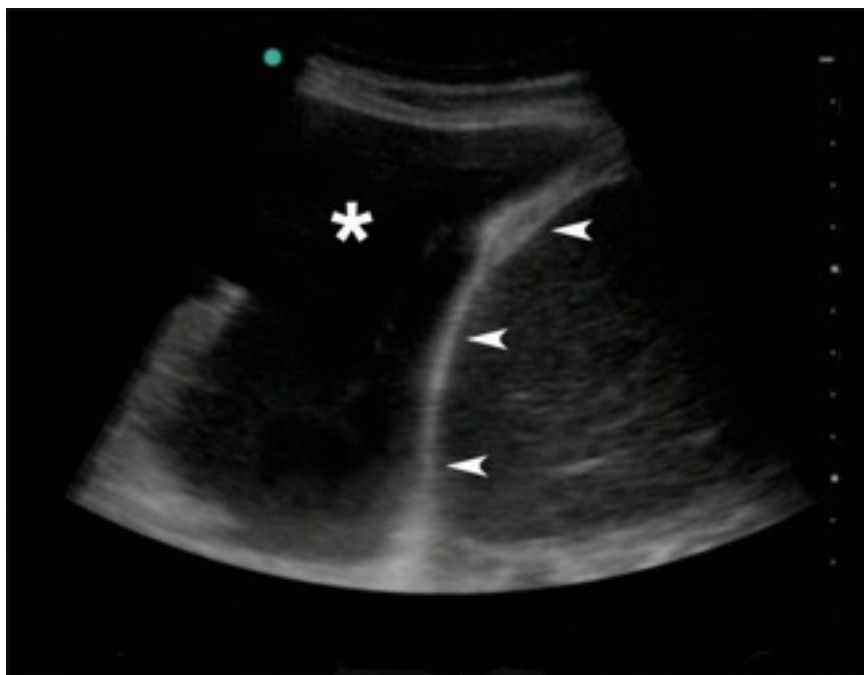


Figure 5. Pleural effusion (*) overlying the diaphragm (arrowheads)

Lung: Usually hyperechoic in appearance, air within the lung scatters the ultrasound beam making visualization of distal structures challenging.

Diaphragm: The diaphragm is the brightly echogenic line overlying the liver in the right upper quadrant (Figure 6) and the spleen in the left upper quadrant.

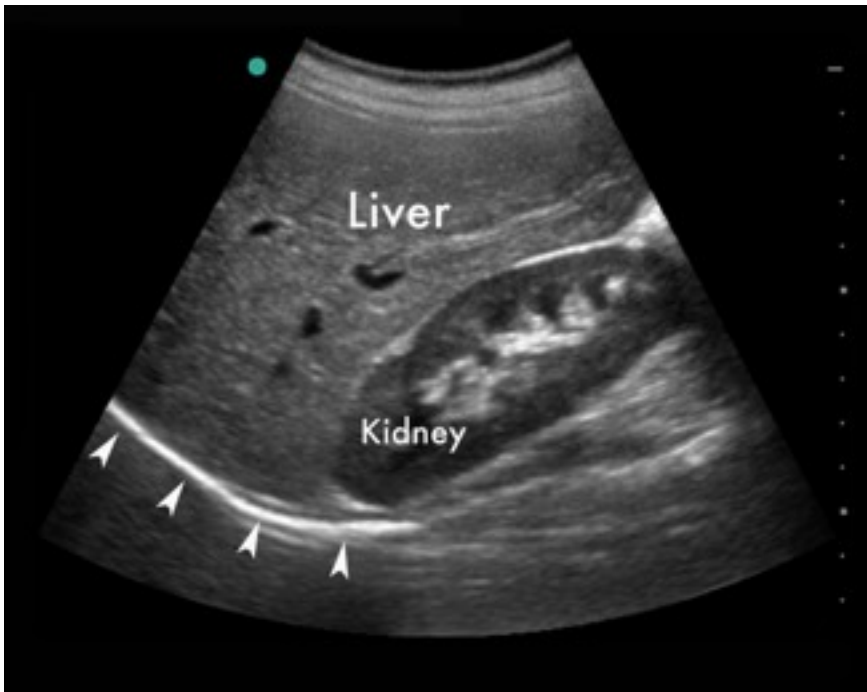

Figure 6. Right upper quadrant view showing the diaphragm (arrowheads) and the liver and kidney

Technique

To assess for pleural fluid, use the curved transducer. The index marker should be directed toward the patient's head. For both the right and left hemithorax, a longitudinal view is used to scan from the anterior axillary line to the midscapular line of the back. A linear probe can be used to identify the optimal rib interspace and to guide administration of local anesthetic down to the parietal pleura.

Ultrasound guidance may be static or dynamic. If the static approach is used, then the optimal location for puncture is marked and the depth from the skin surface to the parietal pleura is noted. The distance to the parietal pleura is estimated by using the depth markers on the side of the screen. If the dynamic approach is used, then the thoracentesis needle is visualized as it penetrates down to and through the parietal pleura. Real-time guidance allows the clinician to assess for adequate needle entry and to avoid underlying lung.

Step by step approach

1. Ask the patient to sit upright, leaning forward and facing away from the clinician performing the

procedure. If the patient is unable to sit upright, place the patient in a semirecumbent position and use an axillary approach. The affected hemithorax should face the clinician and the patient's arm is placed by their head, as demonstrated in Figure 7.

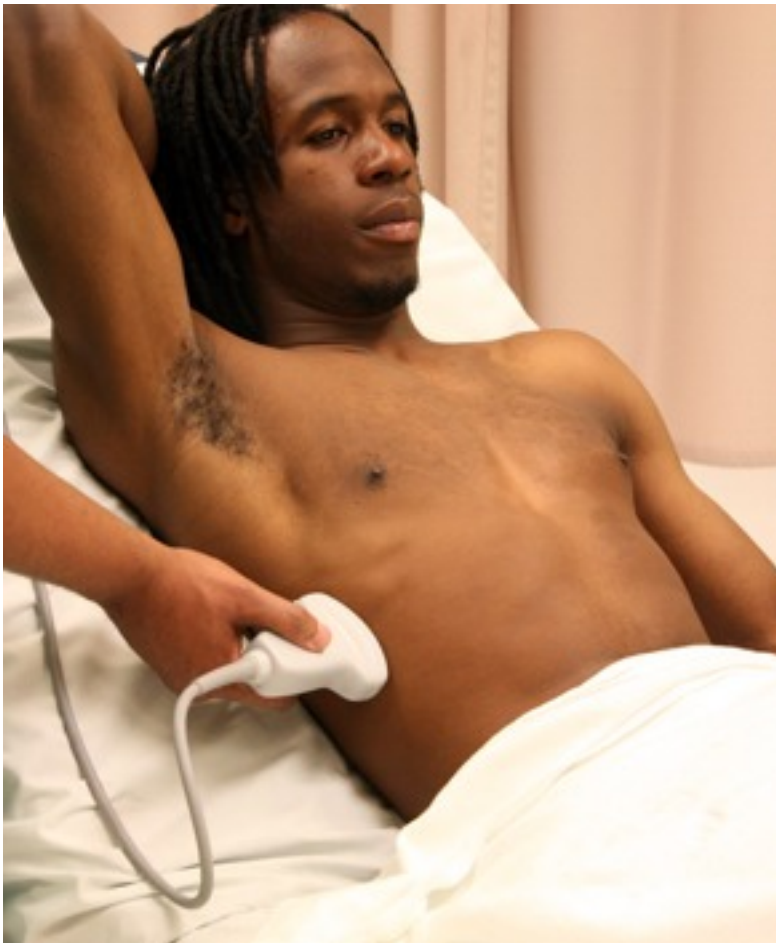

Figure 7. Semirecumbent positioning for ultrasound guided thoracentesis

2. Place the curved transducer in the right and left upper quadrants and use the liver and spleen as acoustic windows. The probe index marker should point cephalad to assess for pleural fluid and to determine the location with the largest pocket of fluid.
3. Switch to the linear transducer to determine the exact location of the diaphragm throughout the respiratory cycle and to look for pleural adhesions. Select a rib interspace to which the diaphragm does not rise at end exhalation. Estimate the distance from the skin surface to the parietal pleura.
4. Prep and drape the patient according to standard sterile protocol.
5. For the static approach, the skin is marked and patient positioning is carefully maintained.
6. For the dynamic approach, the needle tip is visualized with the linear transducer as it is guided above the rib and then down to and through the parietal pleura. On ultrasound, the needle appears hyperechoic and produces a reverberation artifact.

7. Ultrasound can help investigate why the catheter may have stopped draining and assess the adequacy of drainage. Ultrasound is very accurate in evaluating for pneumothorax (see Trauma chapter).

Pericardiocentesis

The physical exam findings of pericardial effusion include diminished or muffled heart sounds and dullness to percussion. Chest radiography may reveal a large cardiac silhouette. Exam findings suggestive of cardiac tamponade include hypotension, distended neck veins, and pulsus paradoxus. While physical exam and chest radiography can provide findings that suggest a pericardial effusion, they are limited in their ability to assess the size or location of the effusion and, more importantly, the hemodynamic significance of the surrounding pericardial fluid. Pericardiocentesis by the traditional landmark technique places the patient at increased risk for pneumothorax, gastric injury, and myocardial puncture. Pericardiocentesis under ultrasound guidance has the potential to decrease complications and add alternative approaches, such as the parasternal or apical views, to the traditional

subxyphoid landmark technique. Ultrasound is extremely helpful for confirming the presence, location, and amount of pericardial fluid and for assessing for impending cardiac tamponade. The earliest findings include: right atrial inversion during ventricular systole, right ventricular free wall inversion during ventricular diastole (a hallmark finding of cardiac tamponade), and a dilated inferior vena cava with decreased respiratory variation.

Clinical applications

- Detection of the presence, location, and amount of pericardial fluid
- Assessing for findings of impending cardiac tamponade
- Identification of the left lobe of the liver, the stomach (if visible), and the left lung
- Determination of the distance from the skin to the pericardium
- Post-procedural assessment for adequate drainage and for pneumothorax

Ultrasound findings

Ribs: hyperechoic structures with associated acoustic shadowing.

Pericardial effusion: appears anechoic or hypoechoic depending on its etiology and may contain internal echoes. True pericardial effusions are still visible during ventricular diastole while physiological pericardial fluid is usually obliterated. See Figure 8 for an example of a pericardial effusion from the subxyphoid position.

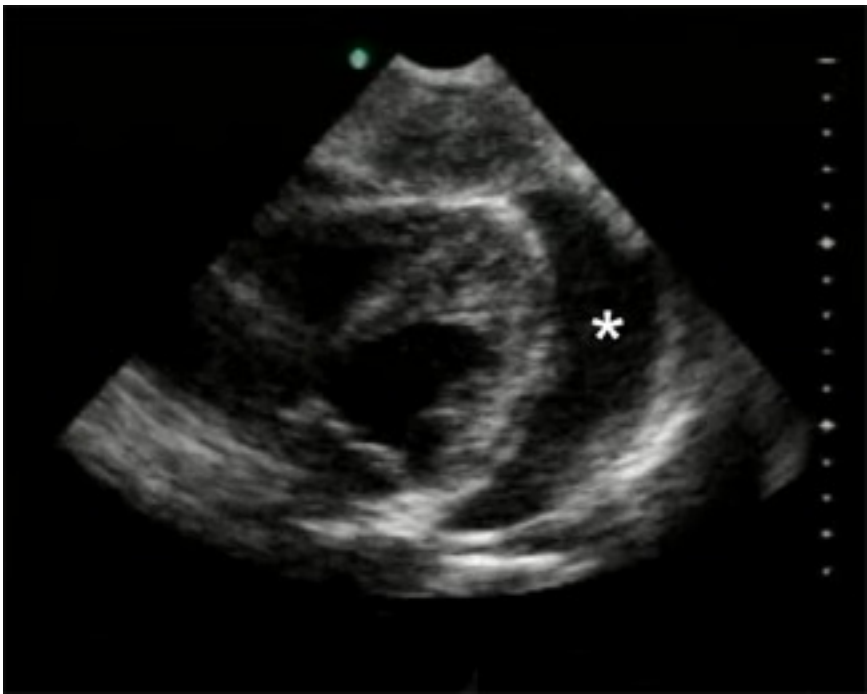

Figure 8. Pericardial effusion (*) in a subxyphoid view

Pleural effusion: An effusion typically appears anechoic or hypoechoic depending on its etiology and may have internal echoes. On the parasternal long axis view, pleural fluid runs posterior to the descending thoracic aorta while pericardial fluid runs anterior, as shown in Figure 9.

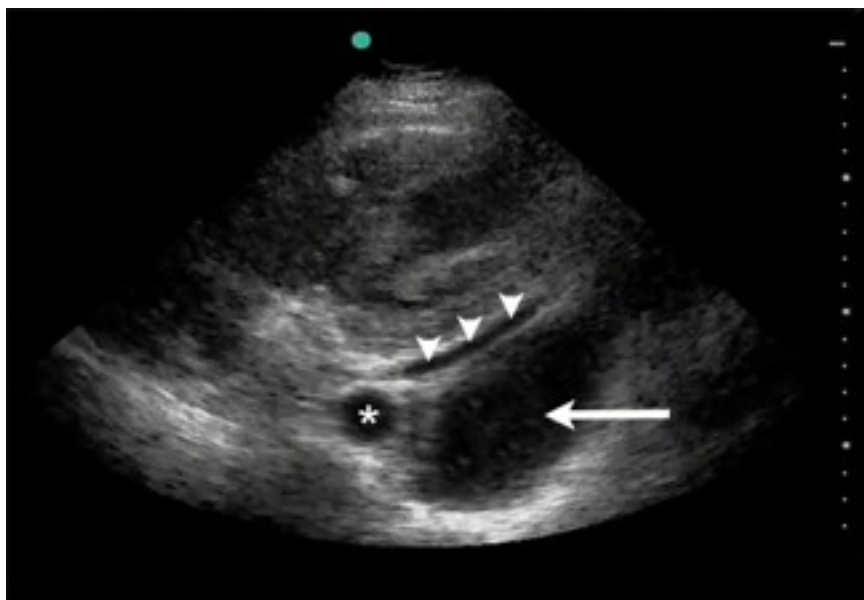


Figure 9. Parasternal long axis view of the heart showing a pleural effusion (arrow), small pericardial effusion (arrowheads) and the descending thoracic aorta (*)

Lung: Usually hyperechoic in appearance, air within the lung scatters the ultrasound beam making visualization of distal structures challenging.

Liver: Liver has a gray echotexture with salt and pepper appearance and brightly echogenic capsule. The subxyphoid view uses the left lobe of the liver as an acoustic window to image the heart.

Stomach: The stomach may be visible on the subxyphoid view when fluid filled. Echogenic foci are often present within gastric fluid and are due to debris or air bubbles. The stomach may have prominent folds and rugae.

Technique

To assess for a pericardial effusion, use the phased array or curved transducer. Multiple views (eg subxyphoid, parasternal, and apical) should be used to better assess for and better characterize a pericardial effusion. Integrating the information obtained from multiple views allows the clinician to determine where the effusion is largest, and whether or not the effusion is hemodynamically significant. Care should be taken to identify the left lobe of the liver, the stomach (if visible), and the left lung. In a parasternal approach, care must be taken to choose a location lateral to the inferior mammary vessels.

Ultrasound guidance may be static or dynamic. If the static approach is used, then the optimal location for puncture is marked and the depth from the skin surface to the pericardium is noted. The distance to the pericardium is estimated using the depth markers on the side of the screen. If the dynamic approach is used, the pericardiocentesis needle is visualized as it penetrates down to and through the pericardium. Real-time guidance allows the clinician to assess for adequate needle entry and to avoid myocardial puncture.

Step by step approach

1. Ask the patient to lie in a semirecumbent position or in the left lateral decubitus position. This brings the heart closer to the anterior chest wall. The patient's left arm is placed by their head.
2. Scan the heart from the subxyphoid, parasternal, and apical views to determine if a pericardial effusion is present and if there are findings suggestive of cardiac tamponade.
3. Determine where the pericardial effusion is largest and which approach offers the shortest distance and the clearest path from the skin surface to the

pericardium. Estimate the distance from the skin surface to the pericardium using depth markers on the side of the screen.

4. Prep and drape the patient according to standard sterile protocol.
5. For the static approach, the skin is marked and patient positioning is carefully maintained.
6. For the dynamic approach, the needle tip is visualized as it is guided into the pericardial space. On ultrasound, the needle appears hyperechoic and produces a reverberation artifact.
7. Ultrasound can also be used to assess the adequacy of drainage and to rule-out pneumothorax.

Conclusions

Physical examination and radiography are limited in their ability to detect intra-abdominal or intra-thoracic fluid collections and cannot reliably determine the best site for drainage. Clinician performed bedside ultrasound is a useful tool for identifying fluid in the abdomen and chest and for assessing the hemodynamic

significance of such fluid. For each of these invasive procedures, ultrasound can be used to determine the shortest and clearest path and to avoid injury to underlying structures. Real-time ultrasound guidance can decrease complications, increase success rates, and improve patient care.

Recommended reading

1. Nazeer SR, Dewbre H, Miller AH. Ultrasound assisted paracentesis performed by emergency physicians vs the traditional technique: a prospective, randomized study. *Am J Emerg Med* 2005;23:363-7.
2. Callahan JA, Seward JB. Pericardiocentesis guided by two-dimensional echocardiography. *Echocardiography* 1997;14:497-504.
3. O'Moore PV, Mueller PR, Simeone JF, et al. Sonographic guidance in diagnostic and therapeutic interventions in the pleural space. *AJR Am J Roentgenol* 1987;149:1-5.
4. Park RS, Metzger JC, Promes S. Emergent Procedures. In: Cosby KS, Kendall JL, eds. *Practical Guide to Emergency Ultrasound*. Philadelphia, PA: Lippincott Williams & Wilkins, 2006:331-51.

5. Noble VE, Nelson B, Sutingco AN. Ultrasound for Procedure Guidance. In: *Manual of Emergency and Critical Care Ultrasound*. Cambridge, England: Cambridge University Press, 2007:212-9.

Vascular Access

GHADA BAKHIDAR MD
VICKI NOBLE MD, RDMS

Introduction

Ultrasound guided vascular access can make an immediate difference in patient care in the emergency setting. Research supports ultrasound guidance for improving success and safety in vascular access compared to the standard, blind technique in both adult and pediatric patients. Ultrasound guidance for central venous access has become the standard of care in many areas. In addition, clinician-performed ultrasound is frequently used to guide peripheral venous catheterization in patients with difficult venous access due to scarring, dehydration or venous anatomy that is difficult to palpate. Ultrasound can help visualize a deeper peripheral vein that may be cannulated but is not easily identified using standard technique.

General Tips

In order to differentiate between artery and vein, note these characteristics of veins:

- Thinner wall
- Compressible
- Expand with valsalva maneuvers
- Non-pulsatile
- Ovoid shape

There are two frequently used techniques for peripheral vascular access:

Static: Using ultrasound to mark the puncture point.

Dynamic: Directly visualizing the needle entering the vein. The clinician holds the probe or has an assistant hold the probe while visualizing the vein throughout cannulation.

This chapter will discuss the real time, dynamic technique, which may have higher success rates and fewer complications than the static technique.

Probe Selection

A high frequency linear probe (Figure 1) is used most commonly.

If the standard linear probe is unavailable, the sonographer may use any ultrasound transducer available, set on the shallowest possible depth for visualization of superficial structures. It is possible to use the curved or transvaginal transducer to obtain vascular access. The linear and transvaginal probes have similar frequency and image quality. One of the main challenges is that the image will be curved, so estimating the needle path can be more difficult.

Preparation

- Use sterile gloves.
- Sterilize the skin with povidone-iodine or chlorhexidine.

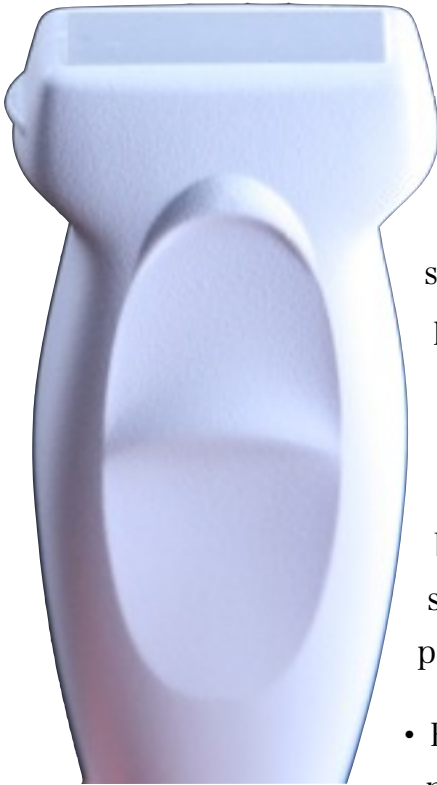

Figure 1. Linear probe

- Use an assistant to hold the probe to maintain sterility while applying non-sterile gel inside the probe cover. Then apply sterile gel outside the sterile probe cover. If a sterile probe cover is not available, a sterile glove may be used. Smooth bubbles away from the scanning surface of the probe to prevent artifacts.
- Estimate the depth of needle insertion by looking at the dots on the screen (Figure 2).

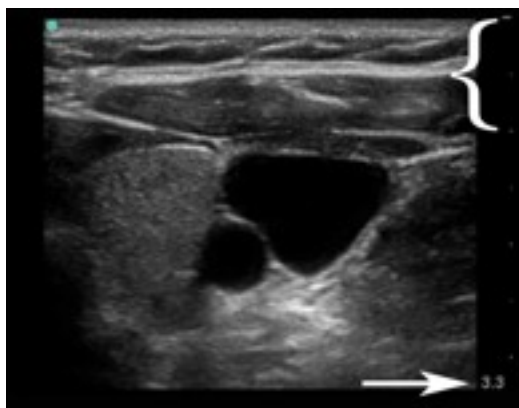


Figure 2. Each large dot on the screen represents 1 cm (bracket). The arrow indicates the total depth of 3.3 cm.

- Make an imaginary right triangle with the probe and vein, and the needle at a 45 degree angle (Figure 3).

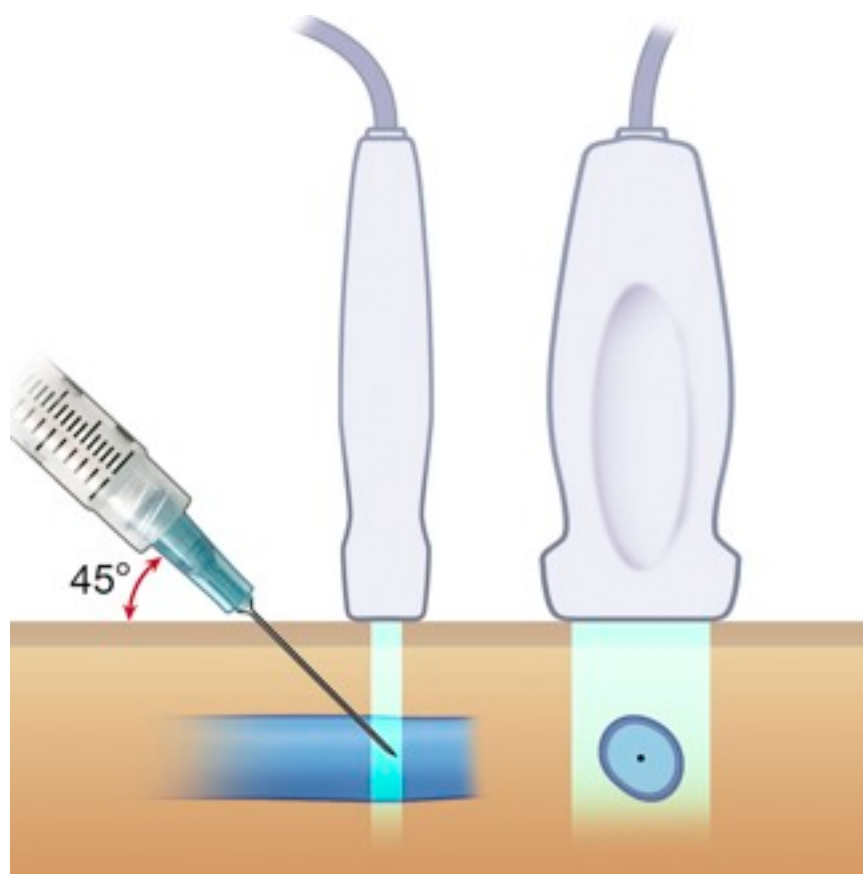


Figure 3. Needle angle 45°

Probe orientation

Transverse views (Figures 4 and 5)

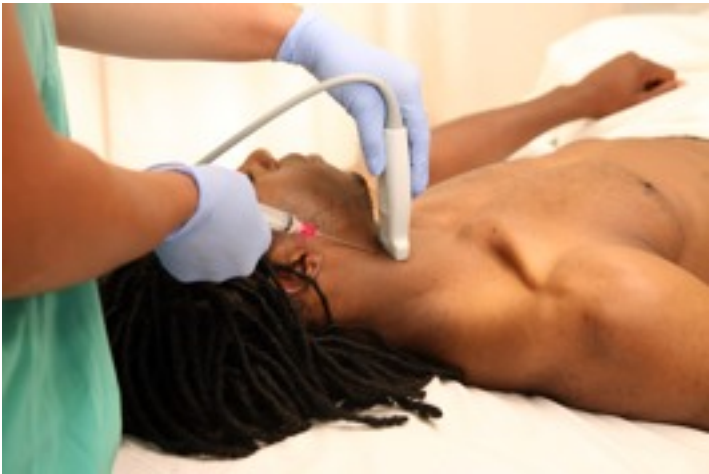

Figure 4. Transverse approach

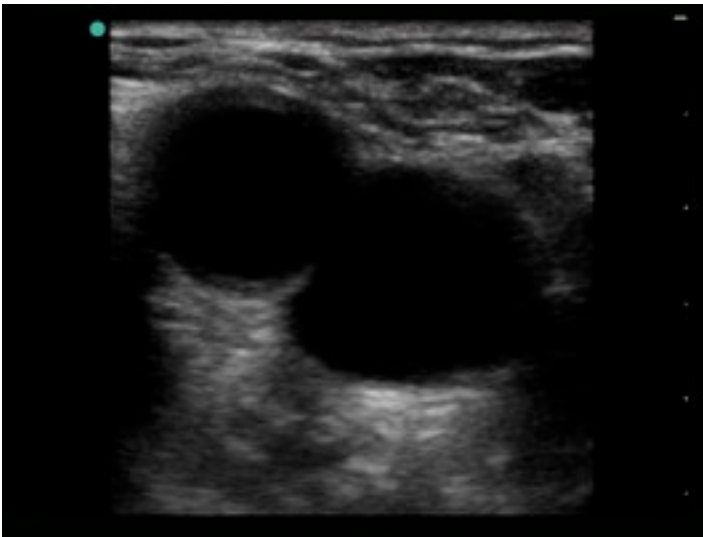


Figure 5. Transverse view of the femoral vessels

Longitudinal views (Figures 6 and 7)

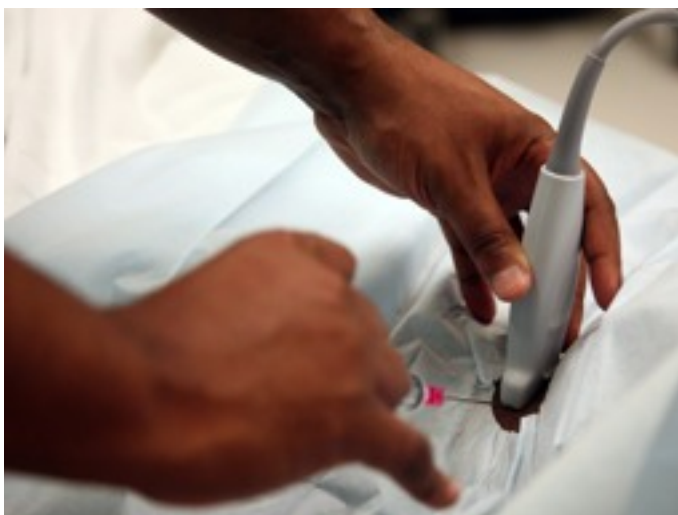

Figure 6. Longitudinal approach. Note: gloves should be worn during procedures.

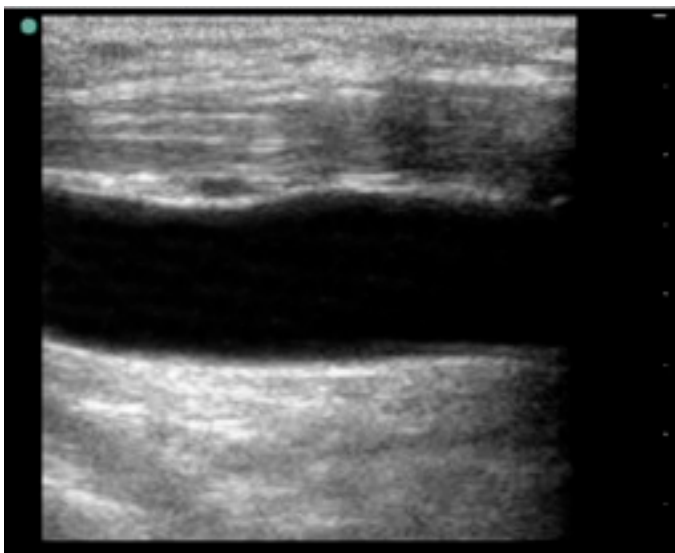


Figure 7. Longitudinal view of the internal jugular vein

Both the long axis and short axis approaches are useful for peripheral venous cannulation under ultrasound guidance. The short axis is the most commonly used approach.

Both

Both techniques can be used together by starting with the short axis view until the vessel wall is reached. The probe is then turned to a long axis view to follow the needle entering the vessel. This technique may help the clinician avoid posterior wall puncture and damage to deep structures.

Another tool is the Color Doppler (Figure 8), which helps to differentiate vein from artery and to guide needle insertion by highlighting the vessel of interest. The color of red or blue denotes flow towards or away from the probe, not vein or artery.

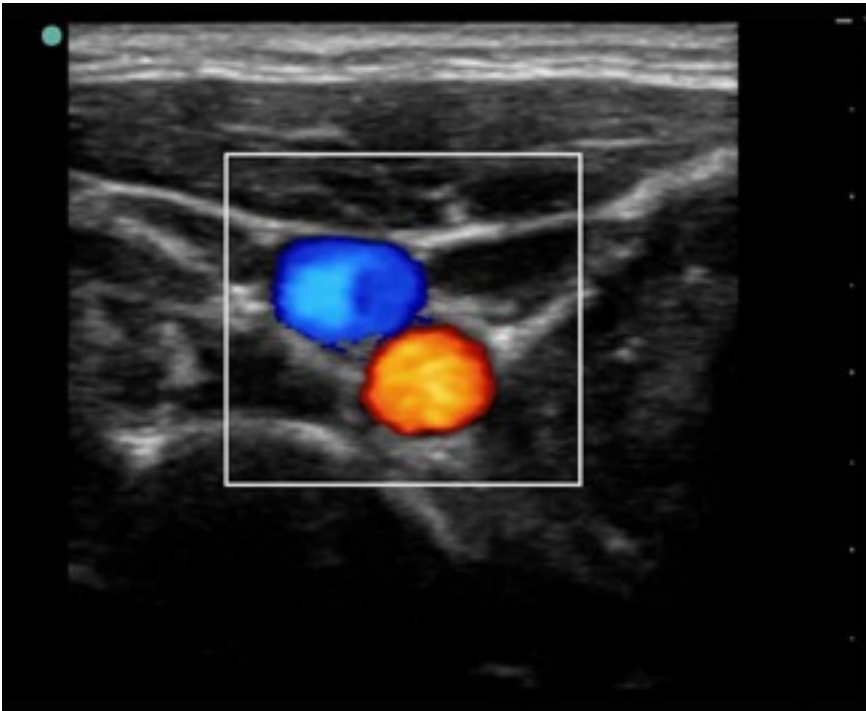


Figure 8. Color Doppler

Pitfalls

- Failure to identify needle tip in tissue (Figures 9 and 10).
- Failure to distinguish between vein and artery, and subsequent arterial puncture.
- Applying too much pressure with the probe will lead to venous collapse.

- Over reliance on external landmarks, which are not always predictive of internal anatomy.

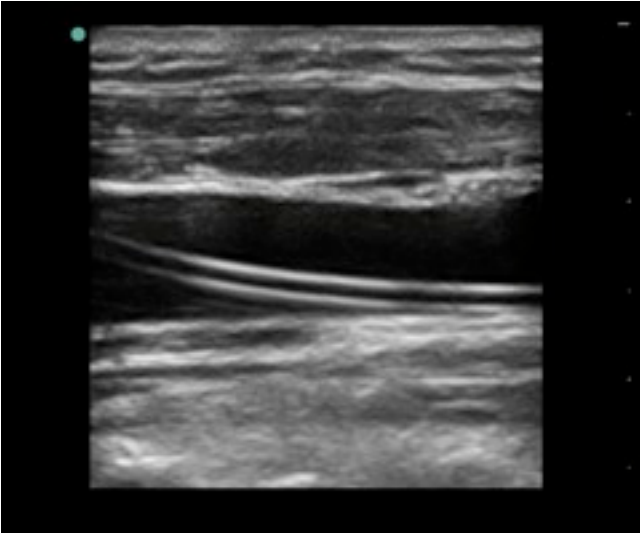


Figure 9. Longitudinal view of a catheter within a vein

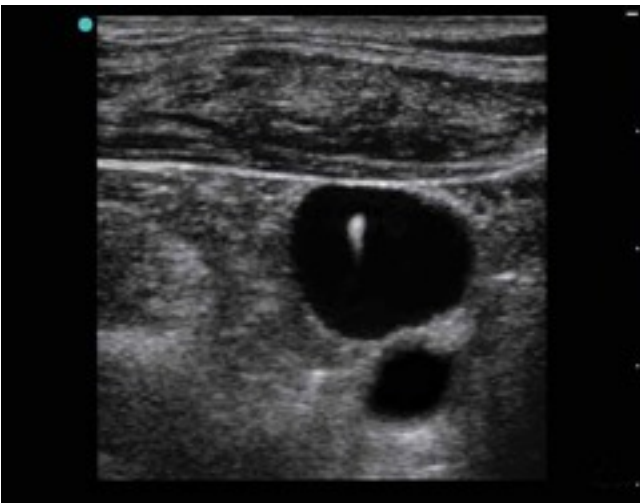

Figure 10. Needle tip within vein

Internal Jugular Vein

Most research on ultrasound guided central venous access has focused on cannulation of the internal jugular vein (IJV). Ultrasound is easier to use due to the anatomy, and benefits to patient safety have been well established. The IJV lies anterior and lateral or overlies the internal carotid artery.

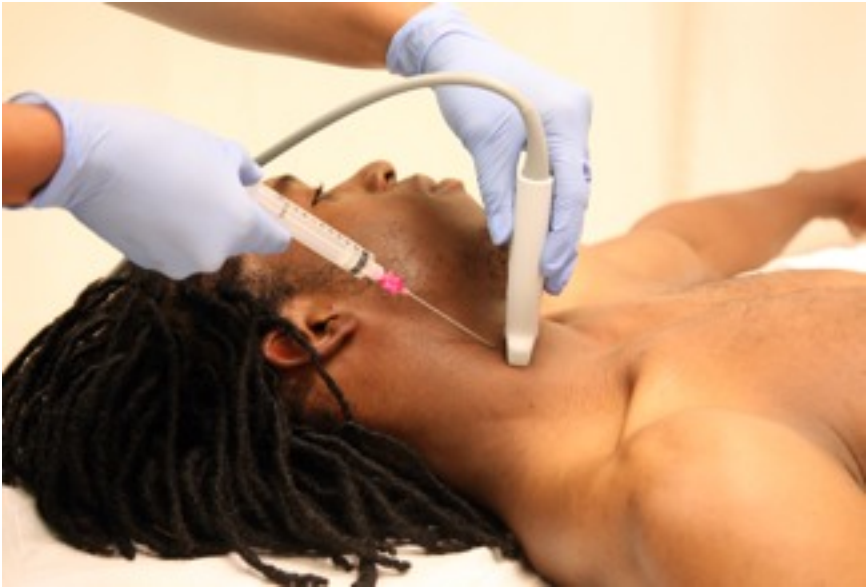

Figure 11. Transverse approach to the internal jugular vein, short axis

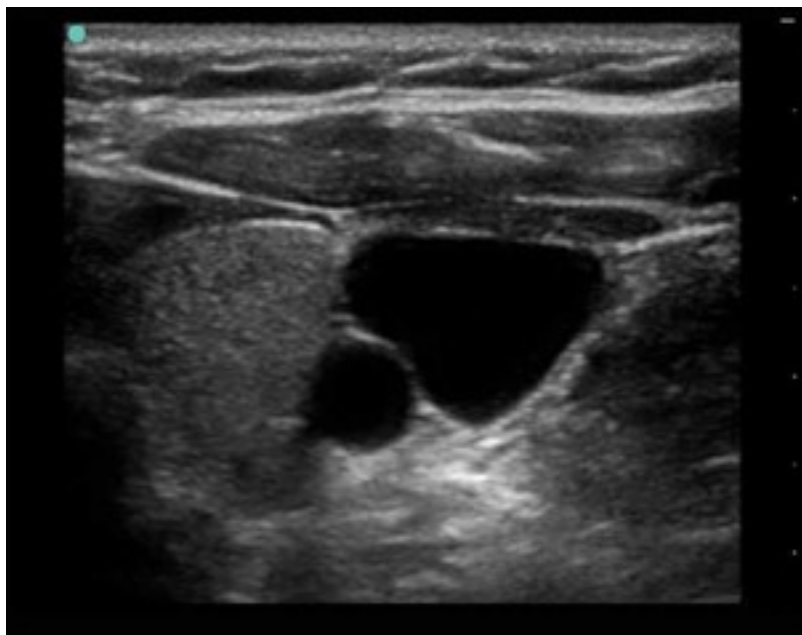


Figure 12. Internal jugular vein and common carotid artery, short axis

Points to remember

- Position the ultrasound screen in the clinician's field of view, so that the clinician can see the screen as well as their hands without turning their head.
- The probe and screen markers should point in the same direction to aid minor adjustments during the procedure, and avoid the confusion of having to move the needle in the direction opposite the probe (Figure 13).

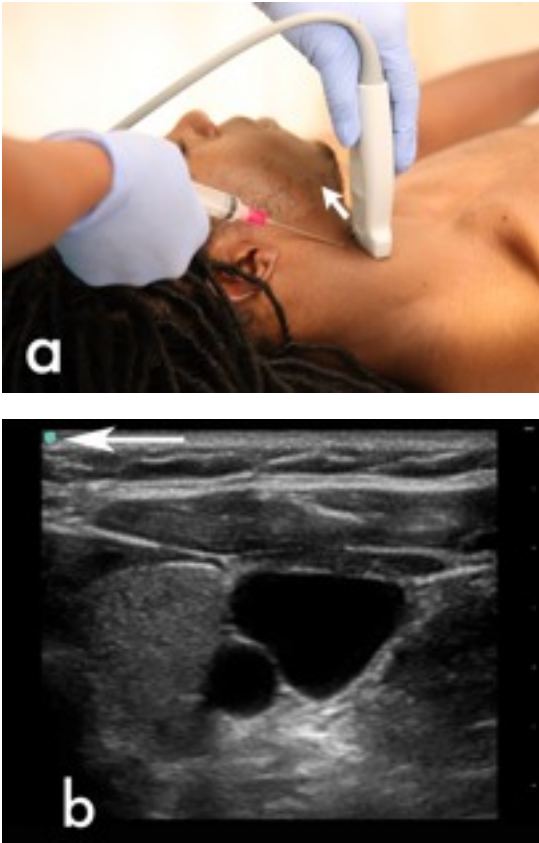


Figure 13. Probe marker (a) and the screen marker (b) pointing the same side as indicated by arrows

- Have all necessary instruments within easy reach prior to starting the procedure.
- Valsalva maneuver, Trendelenberg (head down) position, and humming (like singers) can increase the size of the IJ by increasing the cross-sectional area of the vein.

Pitfalls

- Cannulation when the vein significantly overlaps the artery. Ultrasound can aid in minimizing overlap.
- Applying too much pressure with the probe can collapse the vein.
- If a patient is volume depleted, it is easy to collapse the vein and puncture the posterior wall. This complication may be avoided by noting a slight deformation of the vein as the needle approaches. The clinician can make a quick, jab-like movement with the needle to puncture the vessel.

Femoral Vein

Anatomy

The femoral vein lies medial to the femoral artery, however the vein may overlap the artery near the inguinal ligament. An approach just distal to the inguinal ligament is best (Figures 14 and 15).

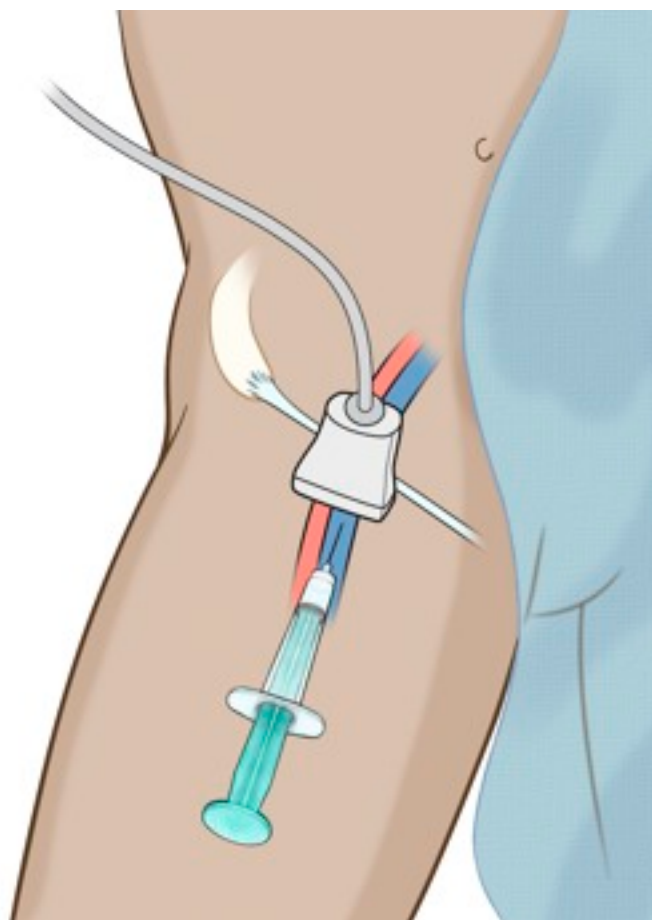


Figure 14. Illustration showing the right femoral vein and artery with the probe in transverse orientation

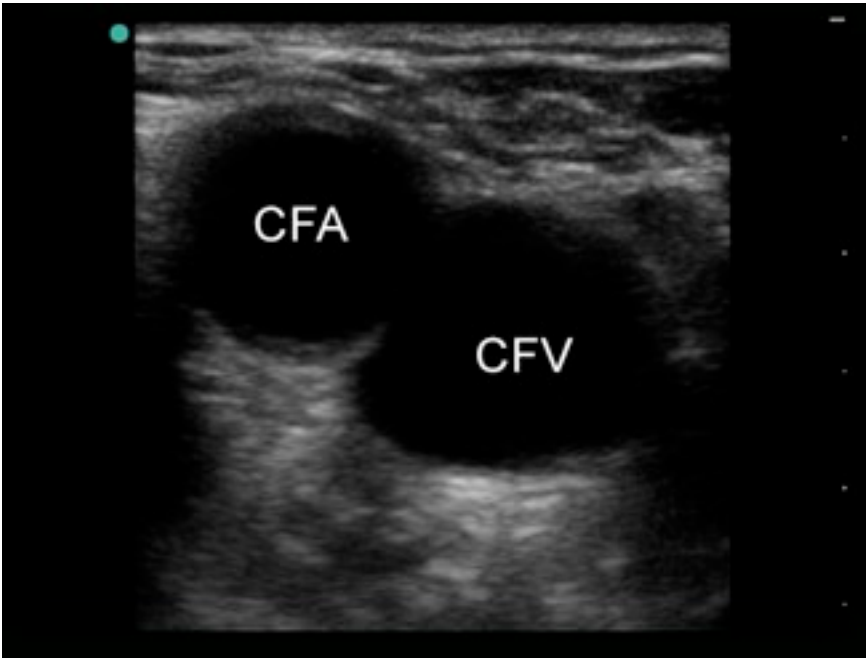


Figure 15. Short axis view of the right common femoral artery and vein

Points to remember

- External rotation of the hip may improve success.
- Augmentation maneuvers may increase the cross-sectional area of the common femoral vein:
 - Reverse Trendelenberg (feet down)
 - Valsalva, such as humming like a singer
 - Abdominal compression

Pitfalls

- The femoral vein overlies the artery and may predispose to arterial injury.
- Inappropriate positioning of the hip may increase overlap of the vein and artery.
- Mistaking a lymph node for a deep venous thrombosis in a femoral vessel (Figure 16).

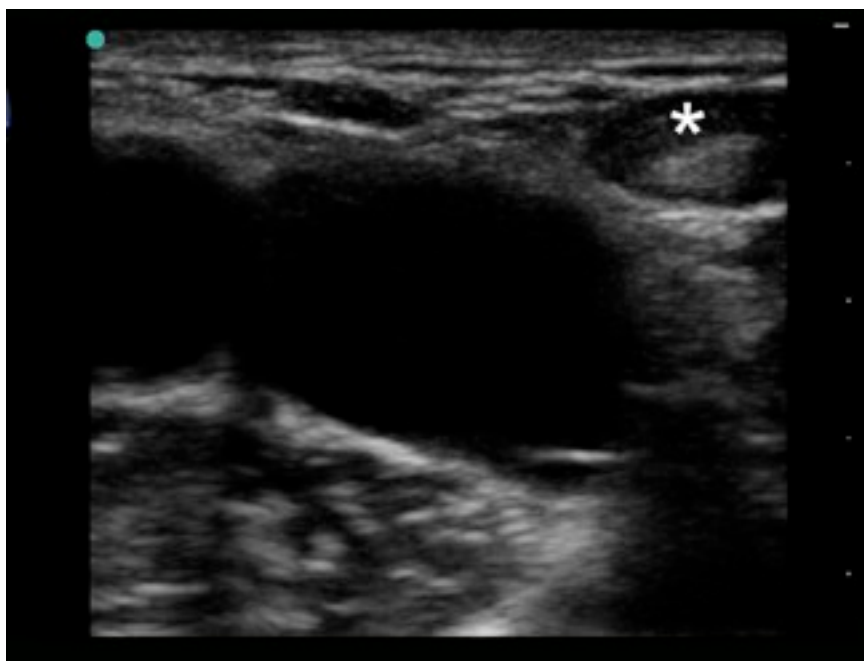

Figure 16. Lymph node (*) above the common femoral artery and vein

Peripheral Veins

Anatomy

Peripheral veins vary in size from just 1-2 mm to 1 cm, and vary in depth as well. The two major veins of the upper extremity, the brachial and cephalic, are not easily palpated but may be easily seen using ultrasound. The brachial vein lies in the medial upper arm while the cephalic vein courses along the lateral upper arm.

Points to remember

- A long catheter (5 cm or greater) will prevent the catheter from slipping out of the vessel, if the patient moves or flexes the biceps muscle.
- Use a 45° angle between the needle and the skin
- Use a tourniquet to increase the size of the vein

Pitfalls

- Median or ulnar nerve injury with proximal cannulation of a vein
- Applying too much pressure with the probe can compress the vein.

- A needle angle greater than 45 degrees may prevent threading of the catheter once the vein is punctured.

Conclusion

Ultrasound is useful in patients with a history of difficult IV access, scarring or other dermatologic processes, or dehydration making the veins collapse easily. Ultrasound can also guide central venous catheterization and prevent complications, when used in real-time.

Recommended reading

- 1.Randolph AG, Cook DJ, Gonzales CA, et al.Ultrasound guidance for placement of central venous catheters: A meta-analysis of the literature. *Crit Care Med* 1996;24:2053-8.
- 2.Hind D, Calvert N, McWilliams R, et al. Ultrasonic locating devices for central venous cannulation: meta-analysis. *BMJ* 2003;327:361.
- 3.Milling TJ, Rose J, Briggs WM, et al. Randomized, controlled clinical trial of point-of-care limited ultrasonography assistance of central venous cannulation: The Third Sonography Outcomes

Assessment Program (SOAP-3) Trial. *Crit Care Med* 2005;33:1764-9.

4. Bauman M, Braude D, Crandall C. Ultrasound-guidance vs. standard technique in difficult vascular access patients by ED technicians. *Am J Emerg Med* 2009;27: 135–40.
5. Denys BG, Uretsky BF, Reddy PS. Ultrasound-assisted cannulation of the internal jugular vein. A prospective comparison to the external landmark-guided technique. *Circulation* 1993;87:1557-62.
6. Karakitsos D, Labropoulos N, De Groot E, et al. Real-time ultrasound-guided catheterisation of the internal jugular vein: a prospective comparison with the landmark technique in critical care patients. *Crit Care* 2006;10:R162.
7. McGee DC, Gould MK. Preventing complications of central venous catheterization. *N Eng J Med* 2003;348:1123-33.
8. Hilty WM, Hudson PA, Levitt MA, et al: Real-time ultrasound-guided femoral vein catheterization during cardiopulmonary resuscitation. *Ann Emerg Med* 1997;29:331-6.
9. Pirotte T. Ultrasound-guided vascular access in adults and children: beyond the internal jugular vein puncture. *Acta Anaesthesiol Belg* 2008;59:157-66.

Cases

Case 1:

Leg swelling

EMILY WROE MD

PROTOGENE NGABITSINZE MD

History

A 3 month old boy presented to Butaro Hospital with swelling of his left thigh after receiving vaccinations in the thigh 2 weeks before. He was found to have jaundice and yellow stools. He had been afebrile, eating well, and gaining weight normally.

Exam

Physical examination revealed an alert infant with tenderness to palpation of his left thigh. He was afebrile, heart rate 148, respiratory rate 42, and oxygen

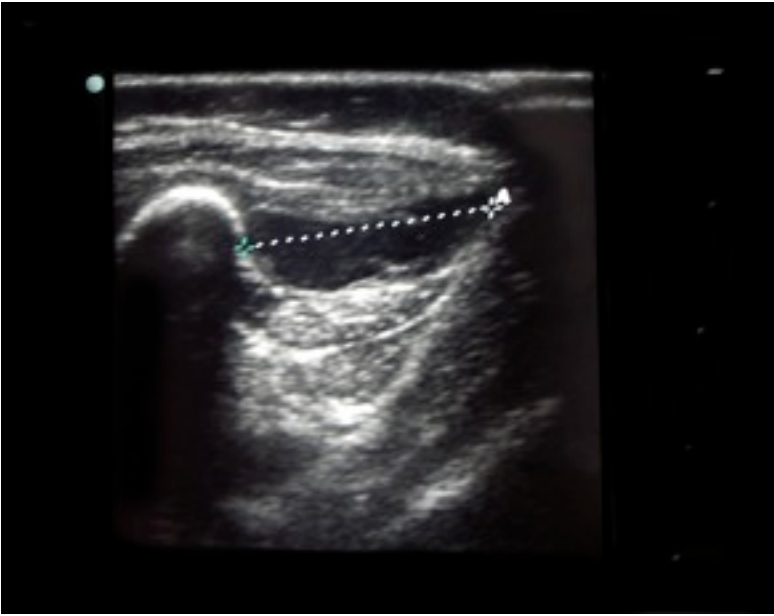
saturation 92% on room air. Exam was notable for scleral icterus and a tense, swollen left thigh without overlying erythema or rash. The remainder of the examination was unremarkable.

Laboratory

Labs revealed a white blood cell count of 21.4, hemoglobin 8.5, ESR 85, total bilirubin 1.8, ALT 186, creatinine 0.4 and LDH 503. A malaria smear was negative.

Ultrasound

Bedside ultrasonography revealed a 1.9 cm hypoechoic area contained within the muscles of the thigh and adjacent to the femur. This was confirmed to be a hematoma by needle puncture.



Case resolution

The hematoma was thought to be a result of his vaccination. Jaundice was due to red blood cell breakdown. One week later, the total bilirubin increased to 10 (direct fraction 6.7), ALT 232 and hemoglobin 6.4. Coagulation time bleeding times were normal. Two weeks after presentation, he was improving clinically and repeat labs showed an improving ALT of 118, total bilirubin of 0.78 (0.17 direct), hemoglobin of 8.5 and LDH 517. He remained afebrile, and the jaundice resolved slowly over a few weeks.

Case 2:

Fever & abdominal pain

PROTOGENE NGABITSINZE MD

EMILY WROE MD

Pediatric case

History

A 27 month old girl presented to Butaro Hospital in Rwanda with a 10 day history of fever and bloody diarrhea. She had several episodes of diarrhea in the preceding year, with one episode being bloody. Each episode lasted about 3 weeks, resulting in several hospitalizations. A review of systems revealed weight loss and anorexia. The child was otherwise healthy and had received all her immunizations.

Exam

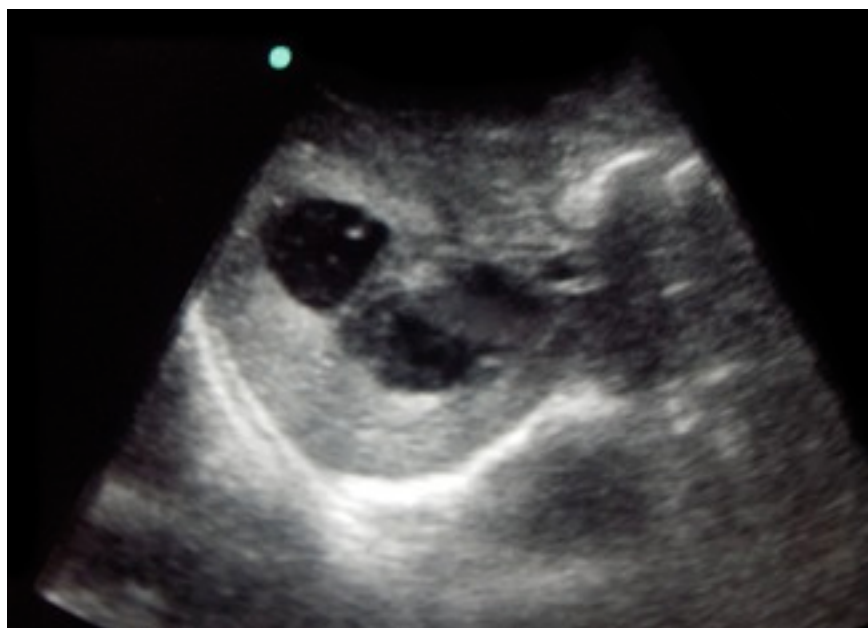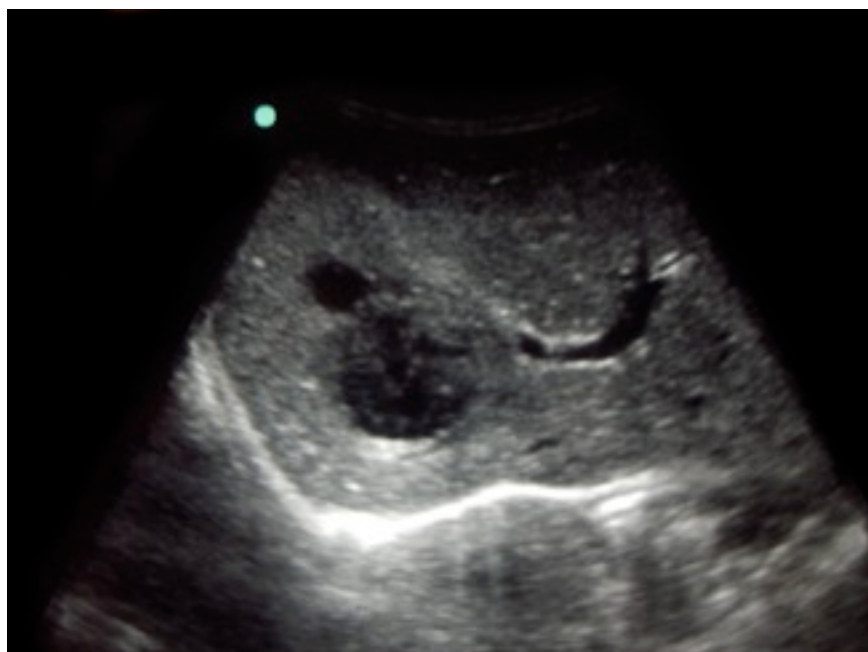Physical exam revealed an alert toddler in no acute distress with a heart rate of 120, blood pressure 80/50, and respiratory rate 48. She weighed 7.7 Kg and was 74 cm tall. Her sclerae were anicteric, lungs were clear, and her abdomen was non-distended with diffuse, mild tenderness to palpation. The rest of the physical examination was unremarkable.

Laboratory

Labs were unremarkable, aside from a slightly elevated bilirubin.

Ultrasound

Bedside ultrasonography revealed a hypoechoic, round structure with ill defined borders in the right lobe of the liver.



Adult case

History

A 90 year old woman presented to Butaro Hospital in Rwanda with a history of several weeks of abdominal pain followed by development of a mass in her right upper quadrant, jaundice, and bilateral lower extremity edema. A review of systems revealed intermittent diarrhea over the preceding weeks.

Exam

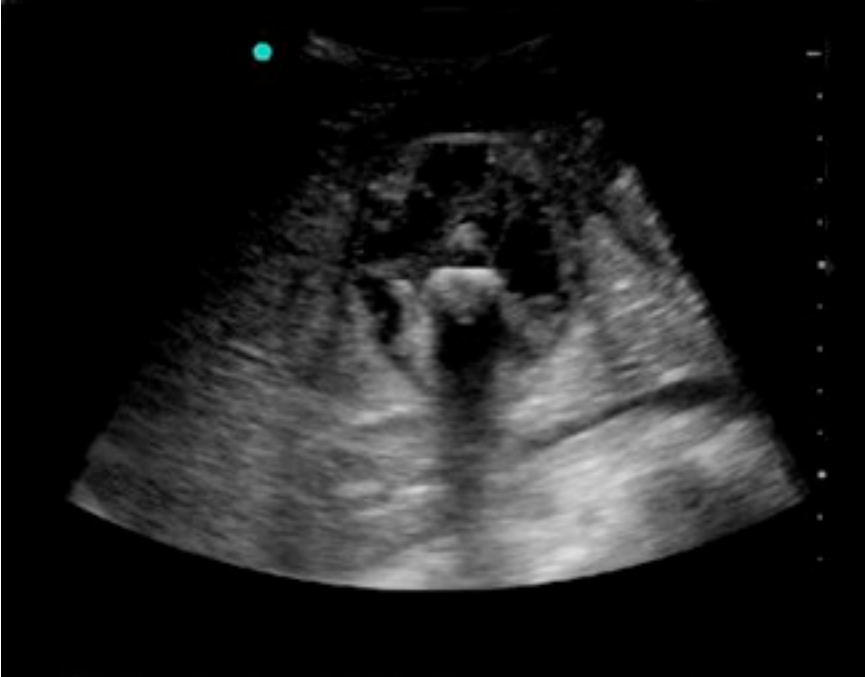Physical examination was notable for tenderness to palpation in the right upper quadrant, edema of the lower extremities, and scleral icterus. The remainder of the exam was normal.

Laboratory

Labs were notable for an ESR of 75, WBC 9.3 (73% neutrophils), Hb 11.7, and creatinine 8.8.

Ultrasound

Bedside ultrasonography revealed a 6 cm abscess in the right lobe of the liver.



Case resolution

Both patients were treated with metronidazole and subsequently improved. Repeat ultrasounds showed resolution of the abscesses.

Entamoeba histolytica infection occurs after ingestion of amebic cysts, which can occur years before the development of liver abscesses. Patients with amoebic liver abscesses can present with acute illness or follow a more indolent course. Those presenting acutely typically have fever, abdominal tenderness, and leukocytosis. Amebic liver abscesses can occur in the absence of amebic colitis, which occurs in a minority of patients. More indolent disease can develop over weeks to months, and these patients are more likely to have a solitary abscess, higher alkaline phosphatase levels, and anemia. Fever and abdominal pain are less common. Liver abscesses develop as a tissue response to trophozoite invasion, resulting in a focal accumulation of fluid and proteinaceous debris within the liver surrounded by a rim of granulomatous inflammation.

For more information see the Liver chapter.

Case 3:

Edema

JUVENAL MUSAVULI MD

EMILY WROE MD

History

A 13 year old girl presented to Butaro Hospital in Rwanda with generalized edema, chest pain, and abdominal distention. These symptoms began several years earlier with facial swelling following by progressive abdominal distention and lower limb edema. When she arrived at Butaro Hospital, she was hospitalized with dyspnea and orthopnea. A review of systems revealed anorexia and fatigue but no change in urine quantity or quality.

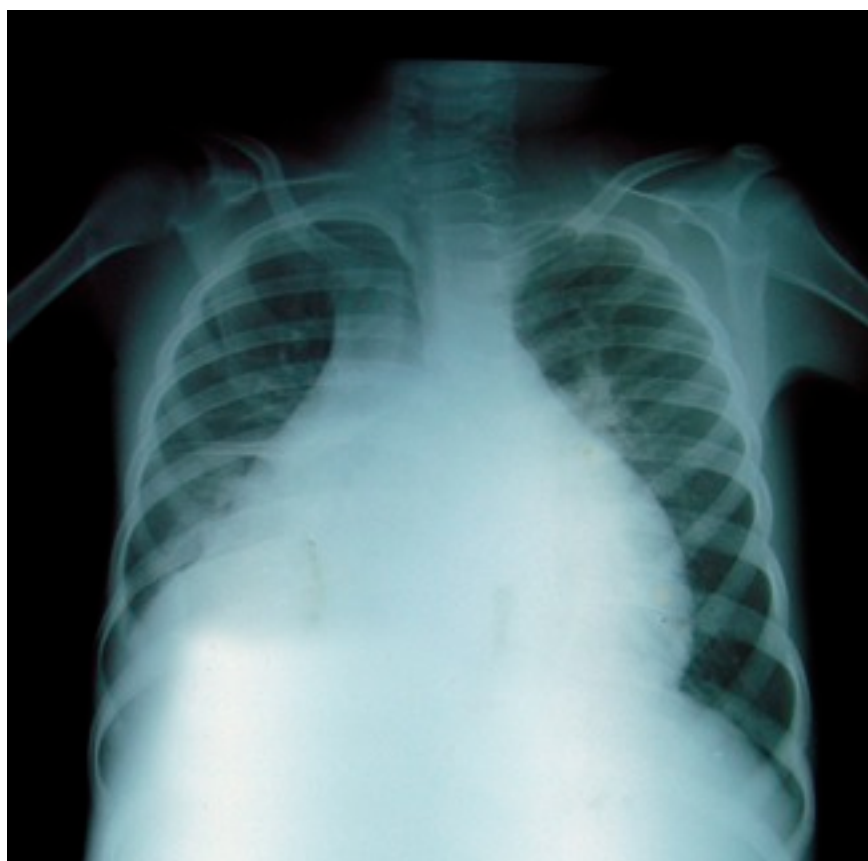Exam

Physical exam revealed a young girl in moderate respiratory distress with anasarca. She was afebrile, with a heart rate of 118, blood pressure 100/70, respiratory rate 34, and oxygen saturation of 85-90% on room air. Her lungs were clear. She had a 4/6 systolic murmur at the apex, ascites, and 3+ pitting edema to her knees.

Laboratory

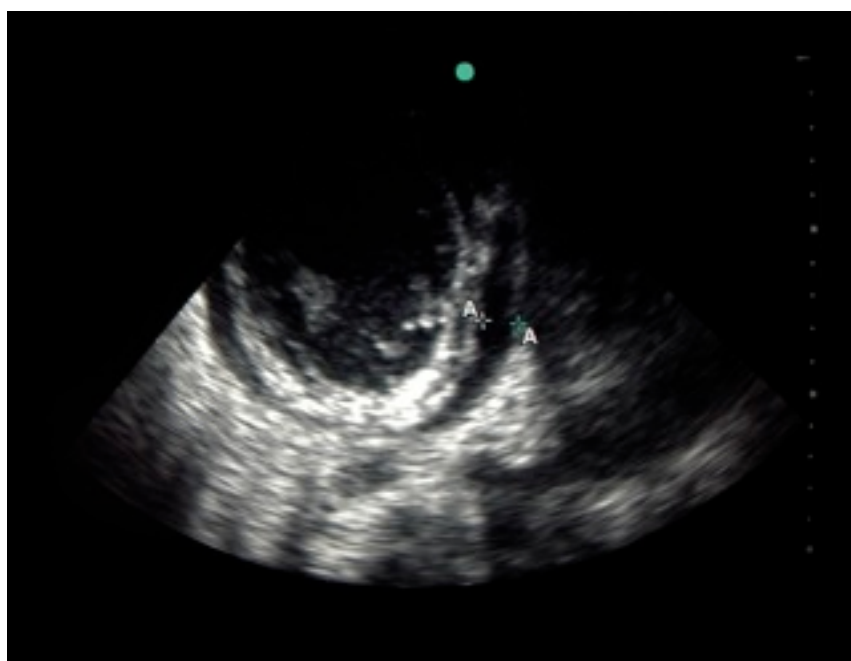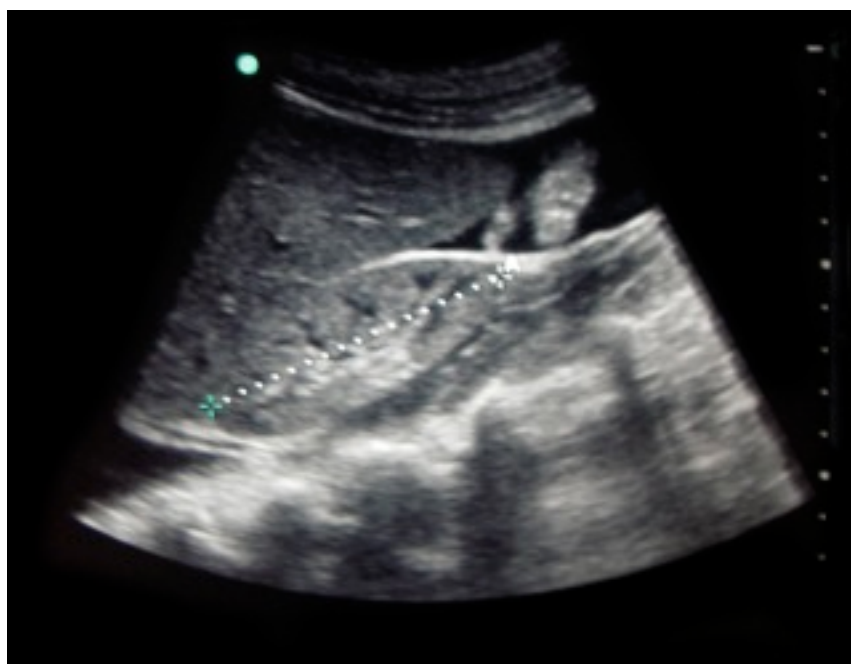Labs were notable for a creatinine of 6.7, urea 41, ESR 5, hemoglobin 12.7, WBC 29.7 (90% poly), platelets 335, HIV negative, proteinuria greater than 300, and a bland urine sediment.

Chest X-ray revealed an enlarged cardiac silhouette with pulmonary edema.



Ultrasound

Bedside ultrasound revealed bilateral pleural effusions, ascites, and small kidneys with loss of differentiation between the cortex and the medulla. In the first image, there is a hypoechoic effusion superior to the diaphragm as well as free fluid between the liver and the kidney. The kidney is hyperechoic and measures less than 8 centimeters. This is consistent with long-standing renal disease. In the second image, a parasternal short axis view of the heart shows a small pericardial effusion seen as hypoechoic fluid outside the myocardium of the left ventricle.



Case resolution

The patient died after 2 days of hospitalization.

Nephrotic syndrome is defined by albuminuria greater than 3.0-3.5 g/day with hypoalbuminemia, edema, and hyperlipidemia. Secondary causes of nephrotic syndrome include systemic diseases such as diabetes, lupus, amyloidosis, and vasculitis. Infections such as streptococcus, syphilis, hepatitis B and C, HIV, and mononucleosis can also cause nephrotic syndrome. Additional secondary causes include medications and certain hereditary and metabolic diseases. Once secondary causes have been excluded, renal biopsy is the best way to diagnosis primary or idiopathic nephrotic syndrome, including minimal change disease, focal segmental glomerulosclerosis, membranous nephropathy, and membranoproliferative glomerulonephritis. In settings where renal biopsy is not possible, a trial of steroids can be considered.

For more information see the Renal & Echocardiography chapters.

Case 4:

Abdominal pain & mass

JEAN NEPOMUSCENE KAMUGISHA MD
EMILY WROE MD

History

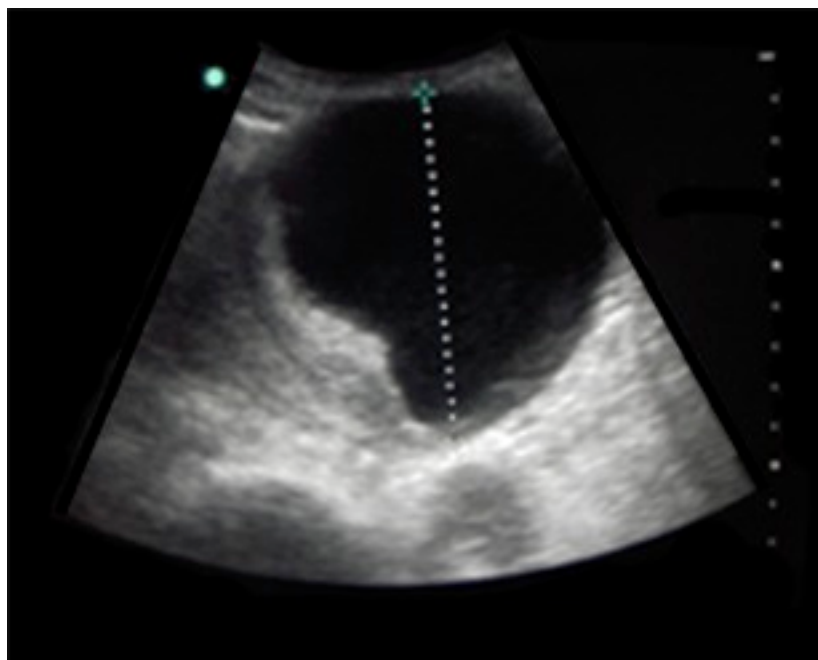
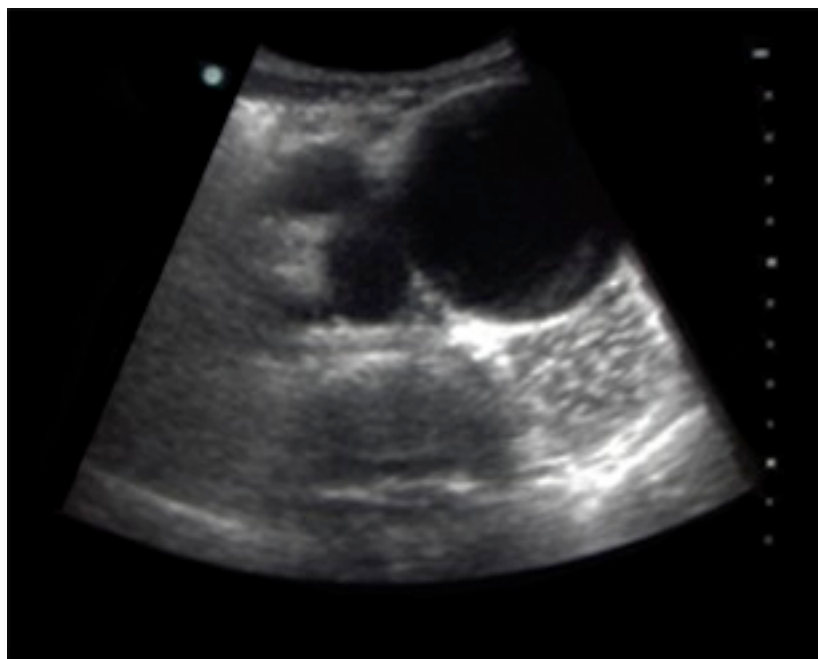
A 63 year old man presented to Butaro Hospital in Rwanda complaining of several years of bilateral lower abdominal pain, which increased in severity in the week prior to presentation. In addition, he said he had a new mass in his abdomen for the past several months. He did not have any medical or surgical history. He did not use tobacco but did drink alcohol on a regular basis.

Exam

Physical exam revealed a thin elderly man in no distress. He had a heart rate of 100 and a blood pressure of 120/70. The abdominal exam revealed a pulsatile, nontender mass at the level of the umbilicus.

Ultrasound

Bedside ultrasonography revealed a large abdominal aortic aneurysm measuring 9 cm in diameter. The thickened wall of the aorta represents clot and atherosclerosis. The vertebral shadow seen deep to the aorta is a helpful sonographic landmark.



Case resolution

Ultrasound is sensitive, as well as practical, for diagnosing abdominal aortic aneurysms. The normal aorta is less than 3 cm in diameter. Aneurysms greater than 5 cm carry a high risk of rupture and typically warrant surgical intervention. Surgical capacity in this setting was limited, and the patient was managed conservatively with aggressive blood pressure control and monitoring.

For more information see the Aorta chapter.

Case 5:

Vaginal bleeding

JUVENAL MUSAVULI MD

ILLUMINEE UWICYEZA MD

JACKLIN SAINT-FLEUR MD

EMILY WROE MD

History

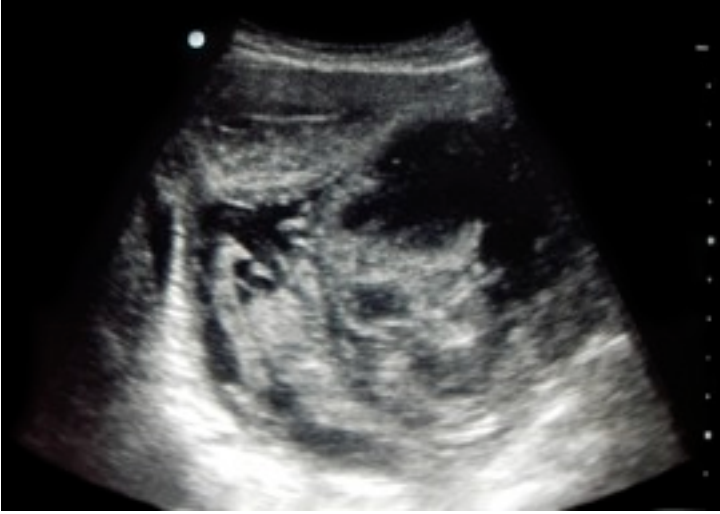
A 31 year old gravida 5 para 4 woman presented to a rural hospital in Rwanda with several hours of abdominal pain and light vaginal bleeding that started a few days prior. Her last menstrual period was 8 weeks before. She had not received an ultrasound exam. All previous pregnancies were uncomplicated resulting in full term deliveries. She denied symptoms of pelvic inflammatory disease and had no significant medical or surgical history.

Exam

Physical exam was notable for severe tenderness of her lower abdomen. Her cervix was closed with a scant amount of old blood in vaginal vault. She had cervical motion tenderness and an adnexal mass on the left side. Vital signs were normal. A urine pregnancy test was positive.

Ultrasound

Bedside ultrasound revealed a large ruptured ectopic pregnancy with clot and debris posterior to the uterus. The uterus as shown in the superior portion of this image, shows an endometrial stripe without a visible intrauterine pregnancy. Most ectopic pregnancies are not seen on ultrasound, as in this case. The most common ultrasound findings are an empty uterus and often free fluid in the pelvis.



Case resolution

In this case, a ruptured ectopic pregnancy was clearly seen on ultrasound. Prior to rupture, the diagnosis can be difficult to make and should be suspected in any woman in early pregnancy with abdominal pain and an empty uterus on ultrasound. Women with ectopic pregnancies often have vaginal bleeding as well. In non-pregnant patients, ruptured hemorrhagic ovarian cysts can have similar symptoms and sonographic findings — free fluid in the abdomen and an empty uterus.

For more information see the Obstetrics: 1st Trimester chapter.

Case 6: Weakness

AGABA FAUSTIN MD

JUVENAL MUSAVULI MD

JEAN NEPOMUSCENE KAMUGISHA MD

EMILY WROE MD

History

A 50 year old man presented to a rural Rwandan hospital with dyspnea on exertion, weight loss, intermittent fevers, and weakness. The review of systems revealed chronic cough, night sweats, anorexia, orthopnea, and a history of abdominal distention.

Exam

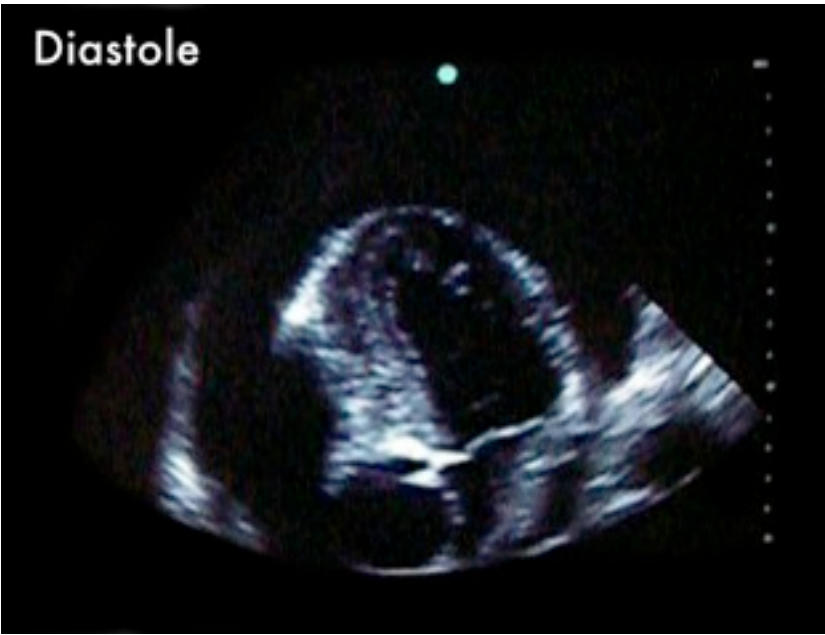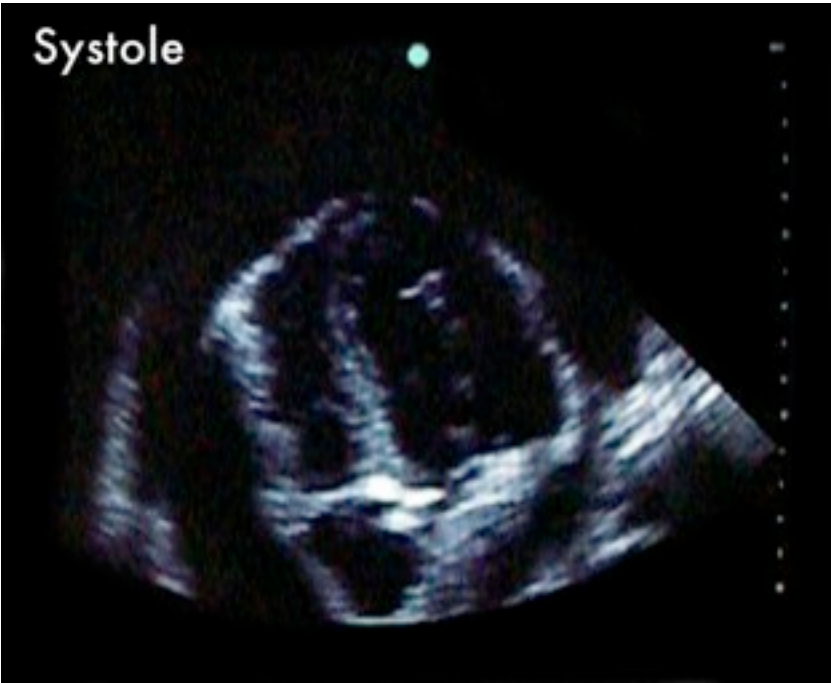
Physical examination was notable for a cachectic man in moderate respiratory distress with a heart rate of 120, blood pressure 110/60, temperature 36.8 degrees Celsius, and a respiratory rate of 32. The patient was pale. He had jugulo-venous pressure of cm, distant heart sounds, mild crackles at both lung bases, and mild abdominal distention.

Approach

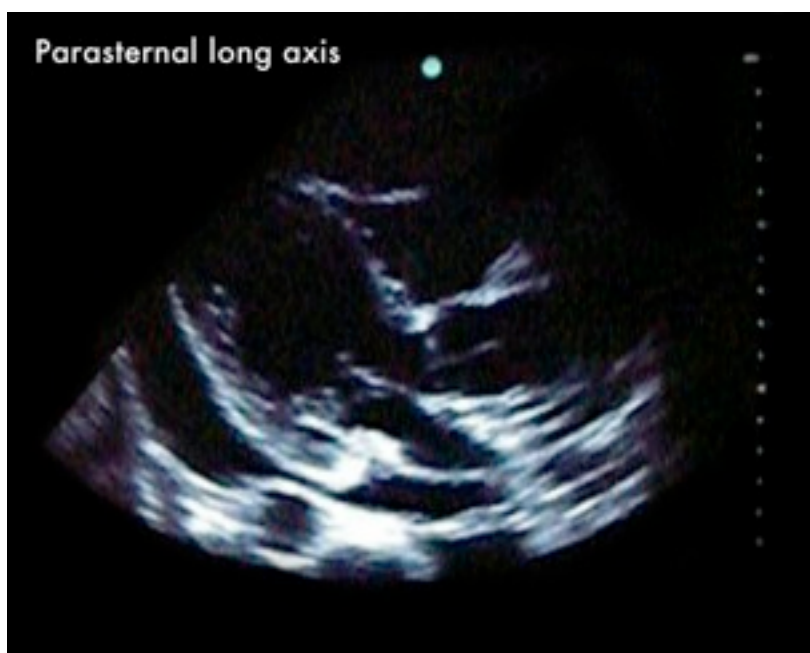The differential diagnosis of dyspnea in this patient includes pleural effusions, heart failure, pulmonary TB, and pericardial effusion. A screening ultrasound in patients with dyspnea can help differentiate between congestive heart failure with systolic dysfunction (for which the clinician might give furosemide) and a large pericardial effusion with signs of tamponade (for which furosemide could be dangerous).

Ultrasound

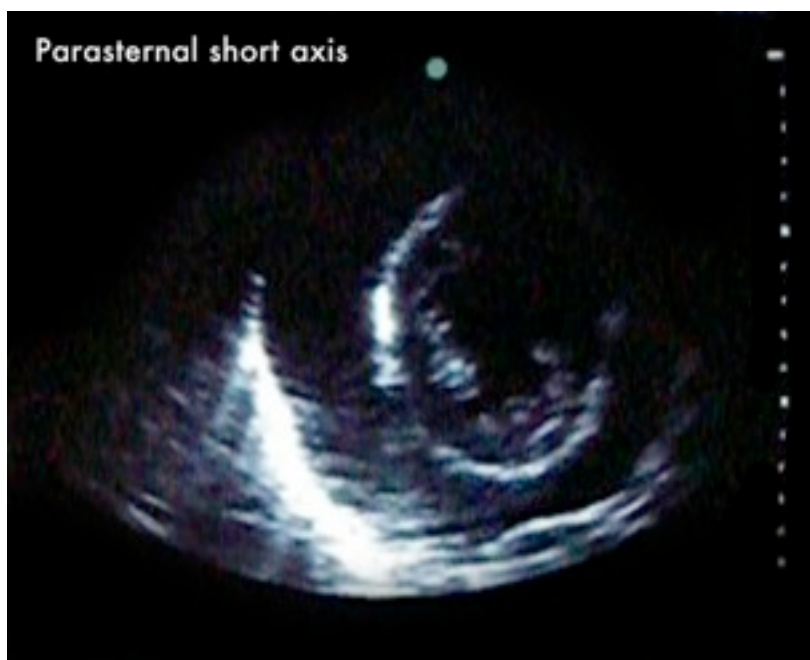In this case, bedside ultrasonography revealed a significant circumferential pericardial effusion with collapse of the right ventricular and atrial free walls during diastole. “Scalloping” of the right ventricle can also be seen.



Parasternal long axis



Parasternal short axis



Case resolution

The patient received immediate supportive care, including IV fluids. He was transferred to a referral hospital, where he remained stable. Treatment for tuberculosis was initiated, and the patient improved over the following weeks.

Cardiac tamponade is a clinical diagnosis based on a patient's hemodynamics and is most affected by the rate of pericardial fluid accumulation, rather than the amount of fluid. This patient had increased jugulo-venous pressure and distant heart sounds but was normotensive and clinically stable. However, the ultrasound images were very concerning for warning signs of developing cardiac tamponade. The patient's stable condition indicated that this was a chronic condition — most likely tuberculosis or malignant effusion. His history of chronic cough, weight loss, and night sweats helped establish the diagnosis of tuberculosis. Pericardial tuberculosis typically presents with cough, dyspnea, and vague chest discomfort. Chest radiography and ultrasound can confirm pericardial effusion. Corticosteroids may decrease the size of the

effusion, improve performance, and reduce late adhesive complications.

For more information see the Echocardiography chapter.

Case 7:

Cough & fever

PROTOGENE NGABITSINZE MD

JUVENAL MUSAVULI MD

JEAN NEPOMUSCENE KAMUGISHA MD

EMILY WROE MD

History

A 27 year old male presented to a rural Rwandan hospital with a 3 month history of cough with hemoptysis, fever, night sweats, weight loss, and anorexia. Over the preceding weeks, the hemoptysis and dyspnea had worsened. He also complained of increasing right upper quadrant pain. He had no significant medical history, took no medications at home, did not smoke tobacco, and had no known tuberculosis contacts.

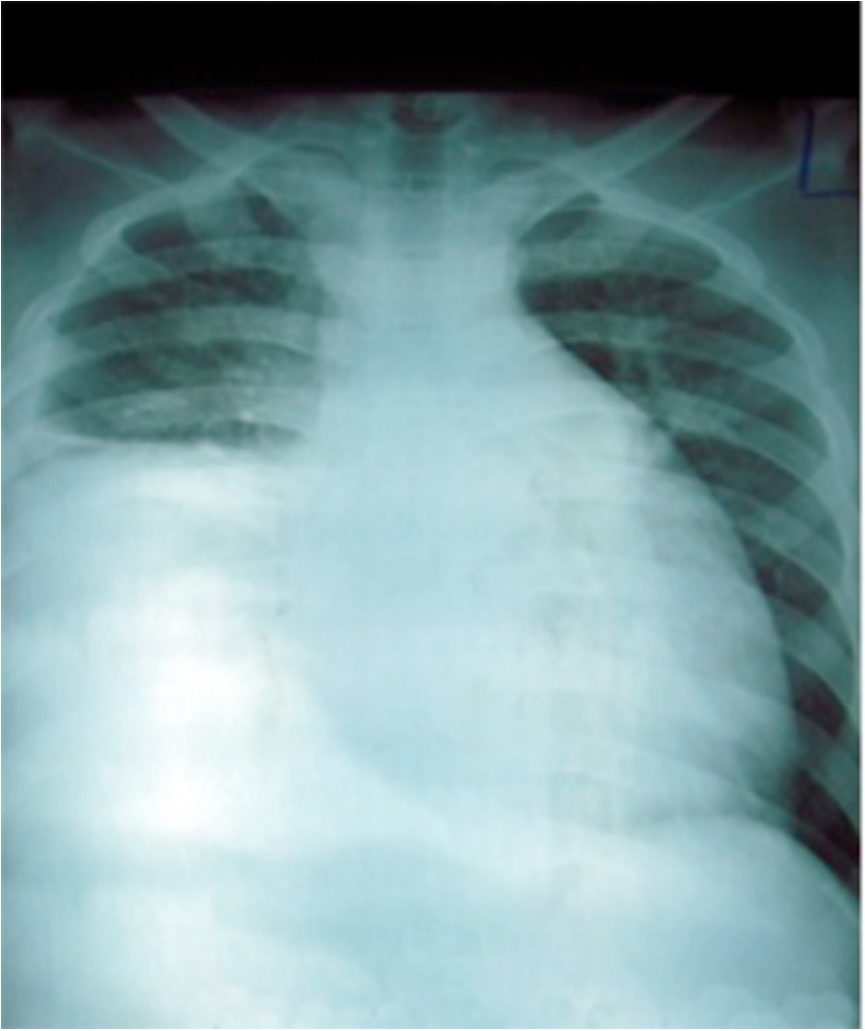
Exam

On physical examination, his heart rate was 140, blood pressure 110/80, respirations 36, and temperature 39 degrees Celsius. He appeared cachectic and had a significant amount of hemoptysis. Lung exam revealed decreased breath sounds in the right middle and lower lung fields with egophony. He had no lymphadenopathy or hepatosplenomegaly. He was significantly tender to palpation in the right upper quadrant.

Laboratory

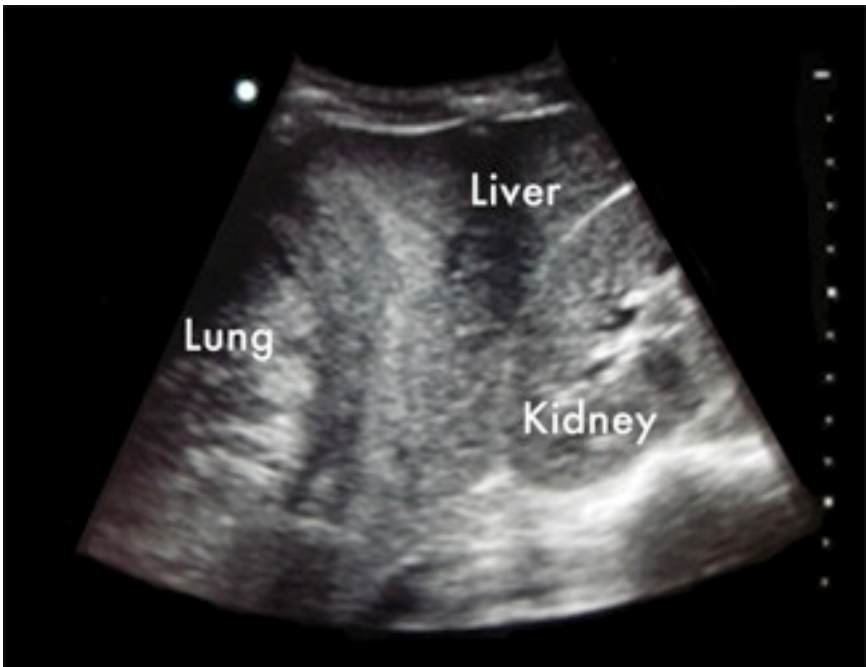Laboratory test revealed a white blood cell count of 16.2 (80% neutrophils), a hemoglobin of 6.5 mg/dL, and platelets of 496. Serum liver and kidney tests were within normal limits. Urinalysis was normal. An erythrocyte sedimentation rate was 132 mm/hr. An HIV test was negative.

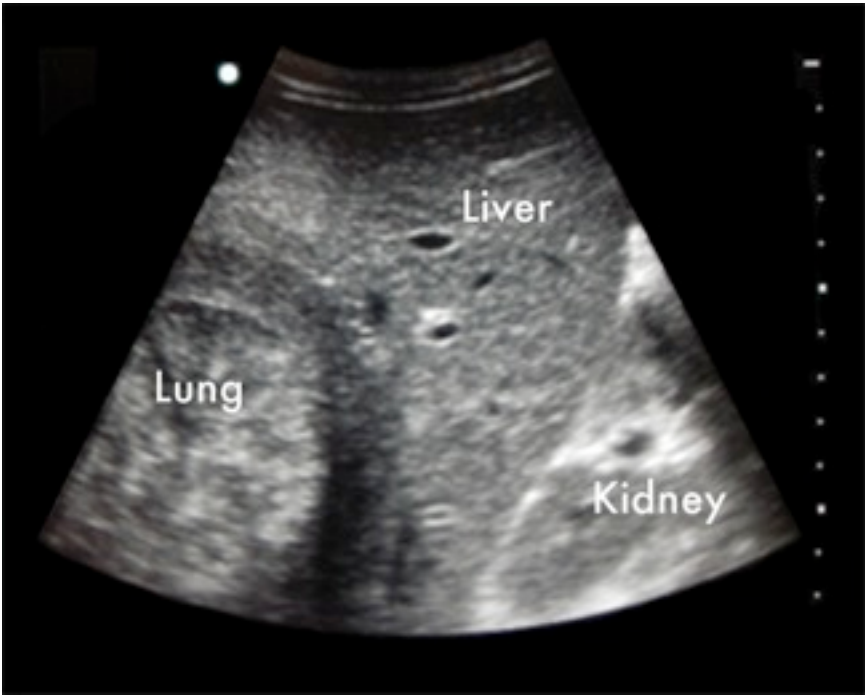
A chest X-ray showed severe consolidation of R lower and middle lobes and cardiomegaly.



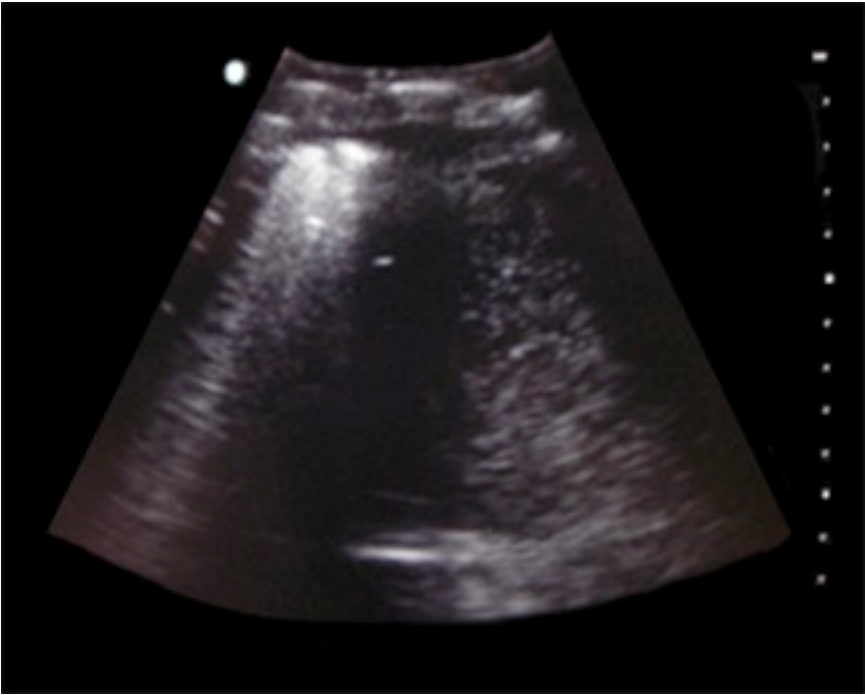Ultrasound

Ultrasound was consistent with severe consolidation of the middle and lower lobes of the right lung with minimal effusion. The lung parenchyma resembles the liver — a phenomenon known as “hepatization”, suggesting consolidation. The liver appeared normal and no ascites was seen. Below are images of the right kidney, liver, and consolidated right lower lobe of the lung.

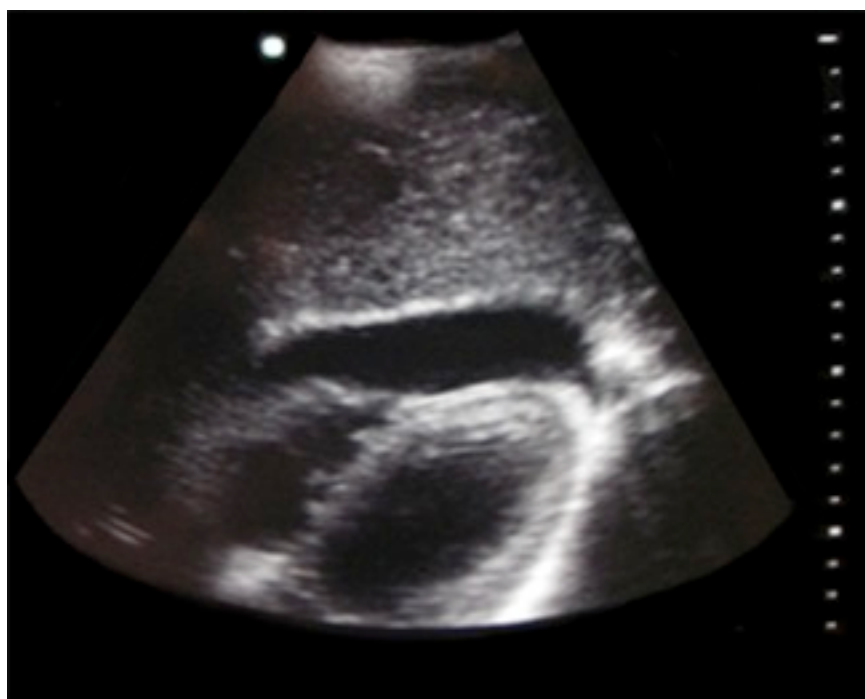




Below is an image in which normal lung tissue (left side) interfaces with the consolidated middle lobe of the right lung (right). Note that in normal lung tissue, air scatters the ultrasound beams creating moving hyperechoic beams that vary with respiration.



The patient also had a pericardial effusion.



Case resolution

The most likely diagnosis in this patient was tuberculosis, with lymphadenopathy causing an acute post-obstructive bacterial pneumonia. He was immediately started on a multi-drug regimen for tuberculosis and bacterial pneumonia. His symptoms gradually improved over the following weeks with slow resolution of the lung consolidation on chest X-ray and ultrasound.

Case 8:

Jaundice

EGIDE MPANUMUSINGO MD

THARCISSE KAMPUNGA MD

LEONIDAS BANYUZUWABO MD

EMILY WROE MD

History

An 80 year old female presented to a rural Rwandan hospital with several months of mild epigastric pain and severe jaundice. Over the past several weeks she noticed a mass in her right upper quadrant. She denied nausea, vomiting, diarrhea, and significant weight loss.

Exam

Physical exam revealed an elderly, jaundice, cachectic woman with mild tenderness in the epigastrium and right upper quadrant. A mass was palpable in her right upper quadrant. The mass was firm but not fixed. It was mobile and would shift when she rolled onto her left side. There were no signs of chronic liver disease, ascites, or edema. The remainder of the exam was unremarkable.

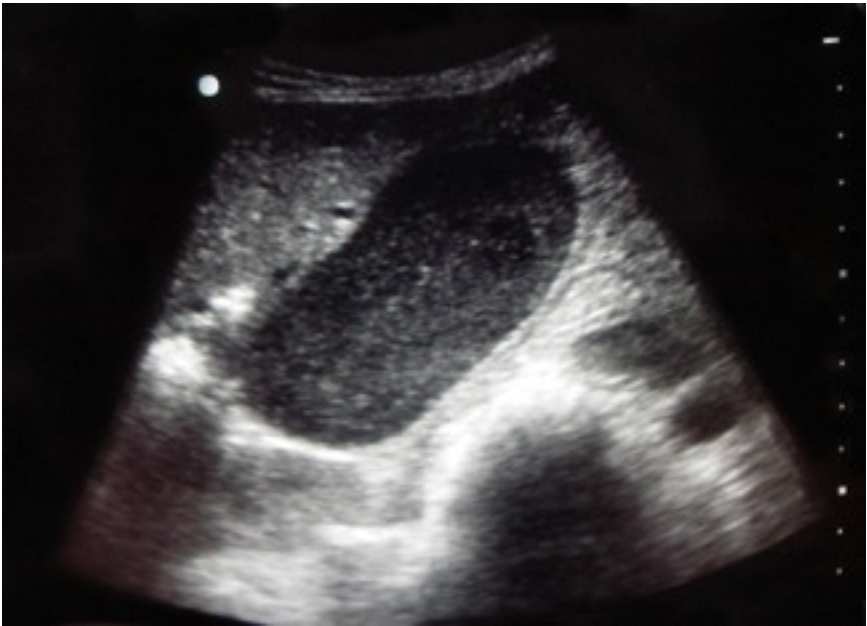Laboratory

Laboratory results include white count of 34.6 (53% lymphocytes), hemoglobin 12.3 mg/dL, platelets 266, creatinine 1.1 mg/dL, total bilirubin 26.7 (direct 6.7), AST 99, ALT 40, and ESR 25. Repeat examination of total and direct bilirubin a few days later showed the same results.

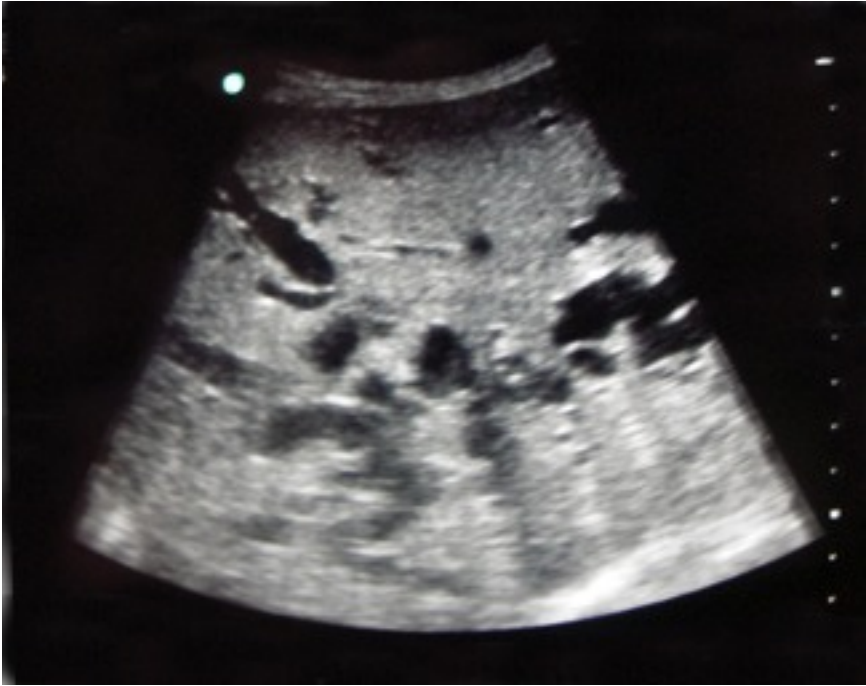Ultrasound

Ultrasound revealed a large hypoechoic ovoid mass adjacent to the liver. The mass was well circumscribed

with debris inside. This elongated mass was a very dilated gallbladder.



The surrounding liver parenchyma was intact but was notable for a dilated biliary tree.



Obstruction of the common bile duct was indicated by the dilated gallbladder and biliary tree, as well as her elevated bilirubin.

Case Resolution

On presentation, there were no symptoms of infection. In this elderly woman with severe jaundice, mild epigastric pain, and obstruction of the bile duct, the most likely diagnosis was pancreatic cancer. She was treated with surgical consultation and supportive care.

Case 9:

Vaginal bleeding

JEAN MARIE DUSHIMIYIMANA

RAYMOND DUSABE MD

FELIX SAYINZOGA MD

EMILY WROE MD

History

A 47 year old woman, who was gravida 9, para 7, miscarriage 1, presented to Kirehe Hospital emergency department in rural Rwanda complaining of vaginal bleeding for 2 months, after four months of amenorrhea. A review of symptoms revealed complaints of nausea, vomiting, and dizziness. The patient had no significant past medical or surgical history.

Exam

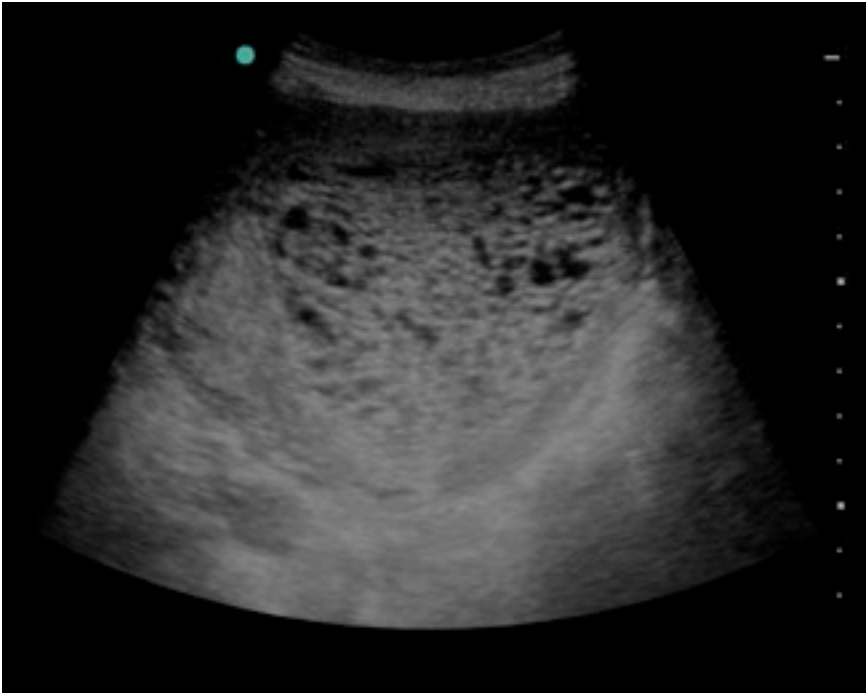
Physical examination revealed an alert, comfortable appearing female with a blood pressure of 110/60, heart rate 98 beats per minute, temperature 36.8 degrees Celsius, and pulse oximetry of 98% on room air. Her abdomen was non tender, with the uterine fundus palpated at the umbilicus. Pelvic examination demonstrated scant bleeding from a closed cervical os. The rest of the physical examination was unremarkable. and.

Laboratory

The urine hCG was positive. Other laboratory results included a white blood cell count of 34.6 (53% lymphocytes), hemoglobin 12.3 mg/dL, platelets 266, creatinine 1.1 mg/dL, total bilirubin 26.7 (direct 6.7), AST 99, ALT 40, and ESR 25. Repeat testing of total and direct bilirubin a few days later showed the same results.

Ultrasound

Bedside ultrasonography revealed abnormal intrauterine tissue typical of a molar pregnancy with the characteristic “snowstorm” appearance of multiple cystic spaces within the intrauterine tissue mass. The tissue appeared heterogeneous and no fetal parts were identified.



Case resolution

The patient was transferred to a larger city hospital for dilation and curettage. Evaluation of evacuated uterine contents by pathology confirmed the diagnosis of a complete hydatiform mole.

Molar pregnancy, a type of gestational trophoblastic disease, is an uncommon cause of first trimester vaginal bleeding. It is usually diagnosed with ultrasound.

Common presentations can include a rapidly growing uterus, absence of fetal movement, passing grape-like tissue per vagina, heavy vaginal bleeding, intractable vomiting, and signs of hyperthyroidism. Treatment involves dilation and curettage, with subsequent follow up serum hCG testing to screen for trophoblastic cancer that will occur in a small percentage of women with trophoblastic disease.

For more information see the Obstetrics: 2nd & 3rd trimester chapter.

Case 10:

Leg pain

PROTOGENE NGABITSINZE MD

JUVENAL MUSAVULI MD

EMILY WROE MD

SACHITA SHAH MD

CORRADO CANCEDDA MD MPH

History

A 9 year old boy presented to a rural Rwandan hospital after injuring his right leg during a football game 7 days previously. He presented with a limp, significant pain in the calf, and a fever to 38 degrees Celsius. He had no significant medical history.

Exam

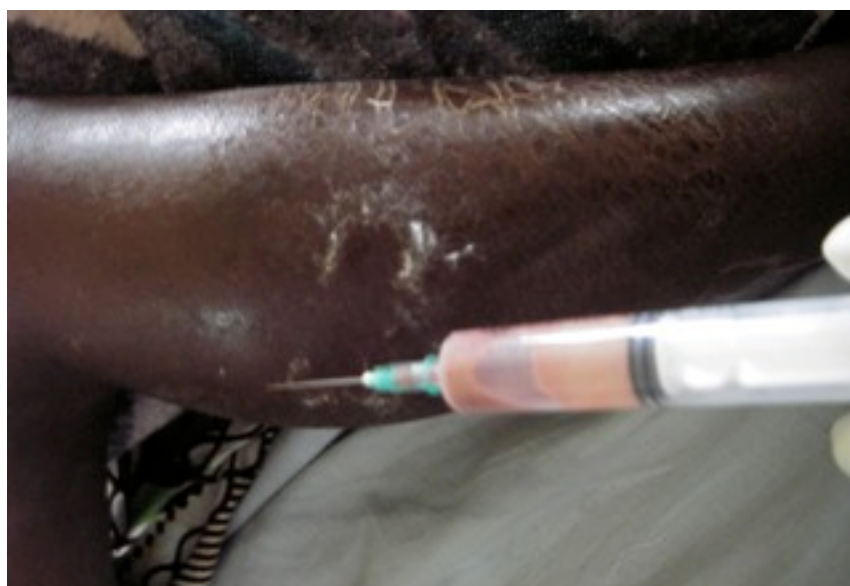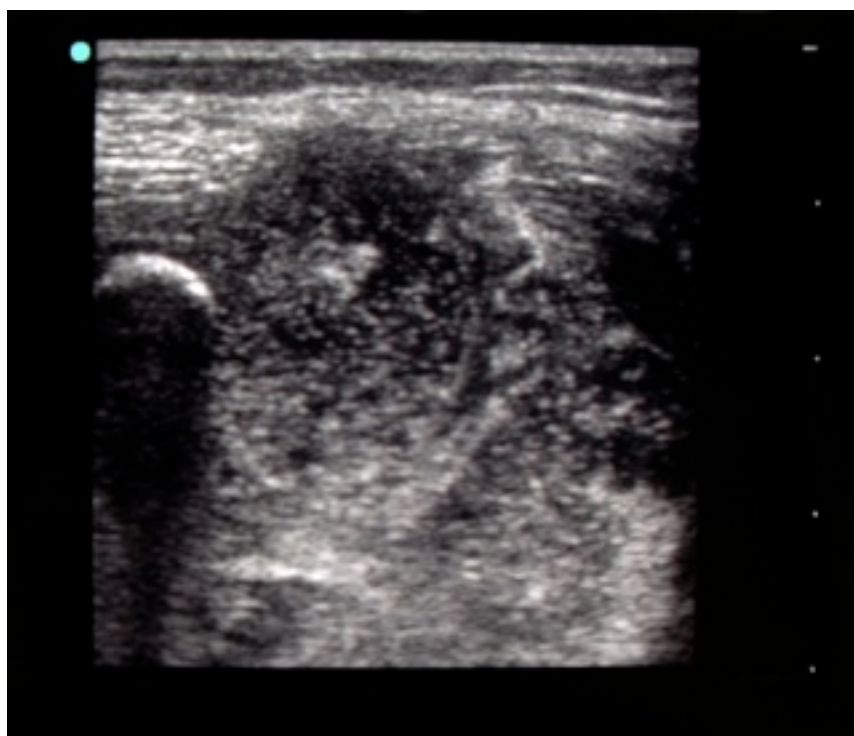Physical exam revealed tenderness in the right calf. The overlying skin was slightly warm without erythema, ecchymosis, or other changes. Distal pulses, sensation, and range of motion were all intact.

Laboratory

Laboratory results were notable for a white blood cell count of 15.2 with 85% granulocytes.

Ultrasound

Bedside ultrasonography revealed an area of liquefaction of muscle adjacent to his fibula. Note the heterogeneous area adjacent to the normal hyperechoic bone, with small hyperechoic bubbles of air. Pressure with the probe was applied to the overlying skin to demonstrate motion of the pus and confirm the liquid state of the underlying tissue. Needle aspiration revealed pus and confirmed the diagnosis of pyomyositis.



Case resolution

Incision and drainage was performed, and he was treated with a prolonged course of IV dicloxacillin.

Pyomyositis is a purulent infection of skeletal muscle that typically occurs in the tropics. Trauma is a common predisposing factor — others include immunodeficiency, injection drug use, concurrent infection, and malnutrition. In trauma, the infection may develop in relation to hematoma formation and/or increased muscle perfusion causing seeding of the hyperperfused area during bacteremia. In this case, the patient had been kicked in the calf during a football game.

Staphylococcus aureus is the most common cause of pyomyositis, especially in the tropics. Patients typically present as this patient did, with fever and pain localized to a specific muscle group, which can be followed by abscess formation and then systemic toxicity. Treatment includes abscess drainage and IV antibiotics targeting staphylococcus and streptococcus for 3 to 4 weeks, although more complicated cases may require longer courses of treatment.

For more information see the Skin chapter.

Case 11a: Cough & dyspnea

PROTOGENE NGABITSINZE MD

GENE BUKHMAN MD PHD

EMILY WROE MD

SACHITA SHAH MD

History

A 10 year old boy presented to Butaro Hospital in Rwanda with a 9 year history of shortness of breath on exertion, and a mild cough. His symptoms began when he was very young and worsened gradually over years. He denied orthopnea or lower extremity edema.

Exam

Physical exam revealed a small boy looking younger than his stated age in no apparent distress. He was afebrile, with a heart rate of 70 and oxygen saturation of 92% on room air. He weighed 20kg. His lungs were clear, and a holosystolic murmur was heard best at the lower left sternal border. No peripheral edema was present.

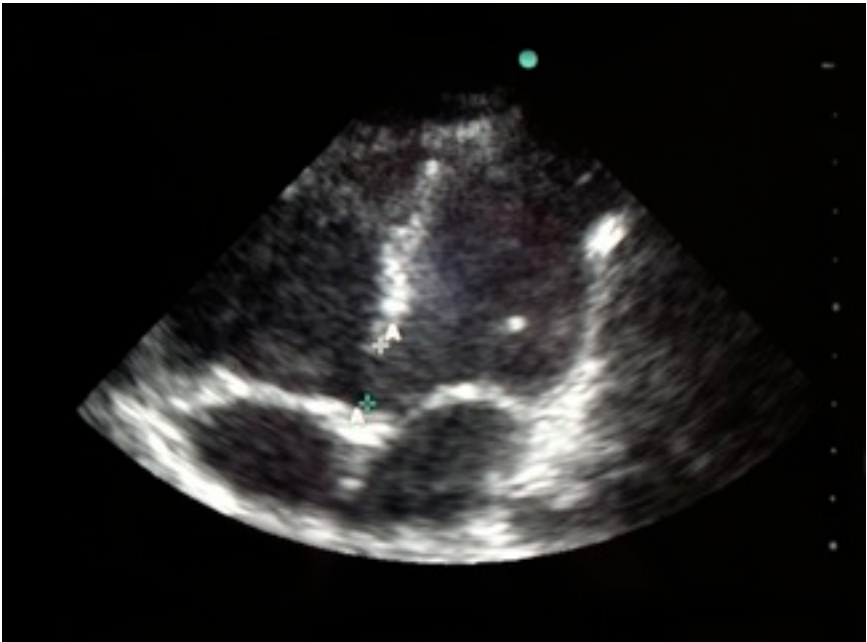
Laboratory

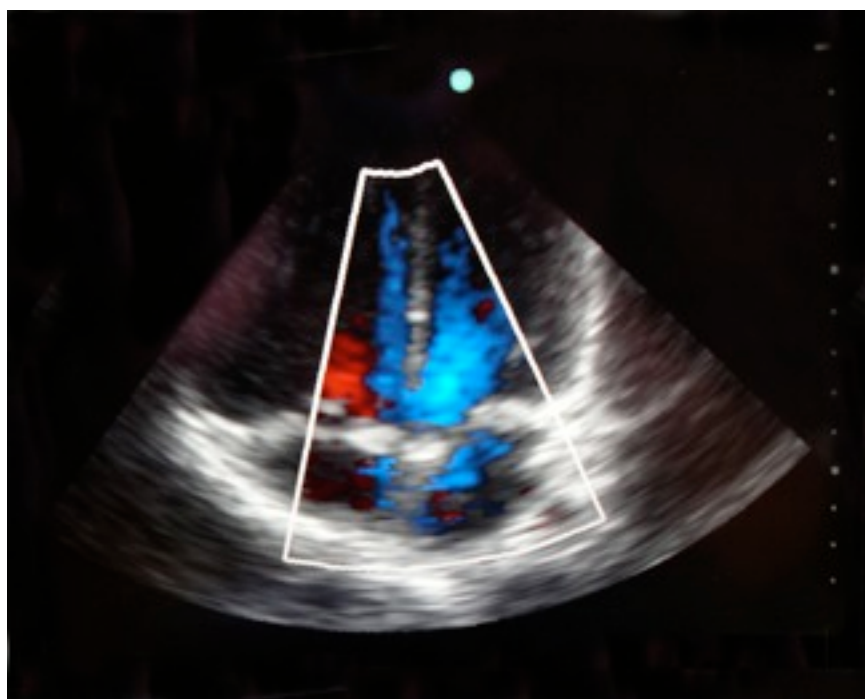
Labs, including complete blood count, liver function tests, and creatinine, were normal. An HIV test was negative.

Ultrasound

Bedside echocardiography revealed a large ventricular septal defect (VSD), subpulmonic stenosis, and an overriding aorta. These findings led to the diagnosis of Tetralogy of Fallot. Systolic function was normal, and a small patent ductus arteriosus was also present. Images of the apical four chamber view with and without color

Doppler are seen below. Doppler demonstrates flow across the septal defect.





Case resolution

A VSD is one of the most common congenital cardiac anomalies, occurring as an isolated finding or in conjunction with other anomalies. Tetralogy of Fallot accounts for 7-10% of congenital heart disease, and the presentation varies depending on the degree of right ventricular outflow tract obstruction. Children with minimal to moderate obstruction, such as this patient, may be diagnosed based on their murmur. In cases of

minimal obstruction, children may also be diagnosed when they present later with pulmonary overcirculation and heart failure. These children often exhibit dyspnea on exertion, clubbing, and erythrocytosis.

Echocardiography plays a key role in the diagnosis and evaluation for operative repair, which almost all of these patients undergo. This patient was scheduled for surgery. For more information see the Echocardiography chapter.

For more information see the Echocardiography chapter.

Case 11b:

Dyspnea

JOANEL JOASIL MD

REGINALD FILS-AIME MD

WALKENS DESIR MD

MACKINLEY SAINT LOUIS MD

ARNOULD VAL MD

MEERA MURUGANANDAN MD

SACHITA SHAH MD

History

A 27 year old man presented to the outpatient Zanmi Lasante clinic in Cange, Haiti with complaints of dyspnea on exertion and fatigue for several years.

Exam

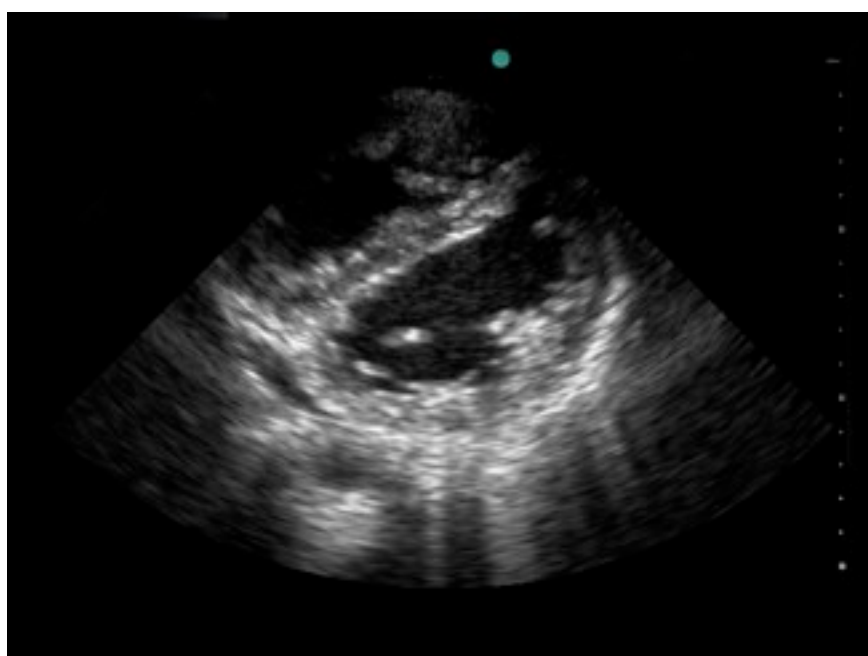
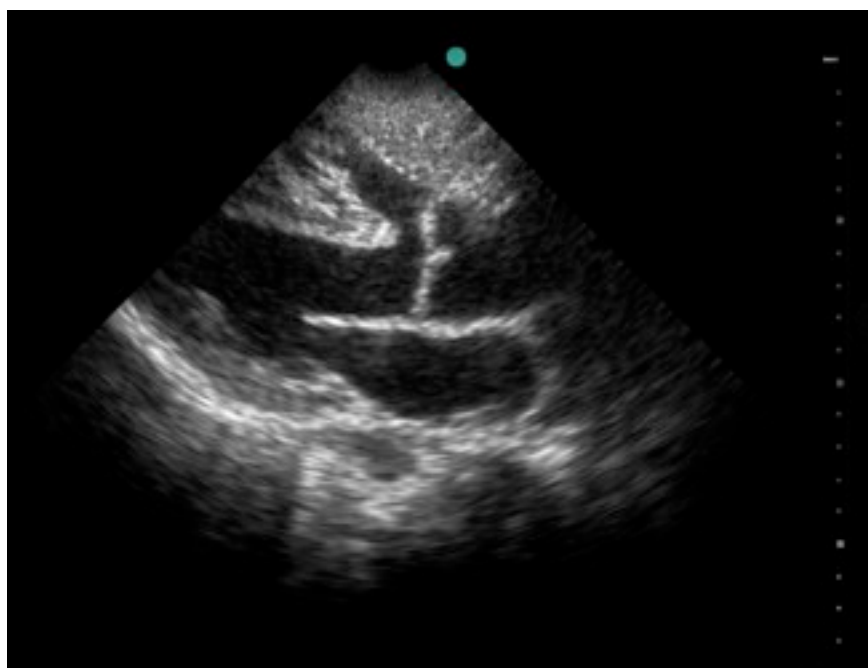Physical examination revealed a thin male with an oxygen saturation of 92% on room air. He had slight cyanosis of his lips, and. The cardiac exam was notable for a loud systolic murmur with a palpable thrill.

Radiology

Chest X-ray was notable for cardiomegaly.

Ultrasound

Bedside echocardiography revealed a ventricular septal defect, overriding aorta, and right ventricular hypertrophy. In the parasternal long axis view, it is possible to see both ventricles communicating with each other through the VSD, and providing blood flow into the aortic outflow tract. In the parasternal short axis, the muscular wall of the right ventricle is as thick as the left ventricle, suggesting long-standing response to high pressures needed to bypass a stenotic pulmonary valve.



Case resolution

A diagnosis of Tetralogy of Fallot congenital heart defect was suspected. These findings were explained to the patient, and he was sent for formal echocardiography and cardiology consultation in the capital of Port-au-Prince.

For more information see the Echocardiography chapter.

Case 12:

Decreased urine output

WALKENS DESIR MD

ROMAIN JEAN LOUIS MD

JEAN HAMILTONG PIERRE MD

MEERA MURUGANANDAN MD

History

A 72 year old male was admitted to the medical ward of Hopital Bon Sauveur, in Cange, Haiti with a complaint of decreased urine output. The patient said he had not voided in 2 days and was developing suprapubic pressure, bilateral flank pain and fatigue.

Exam

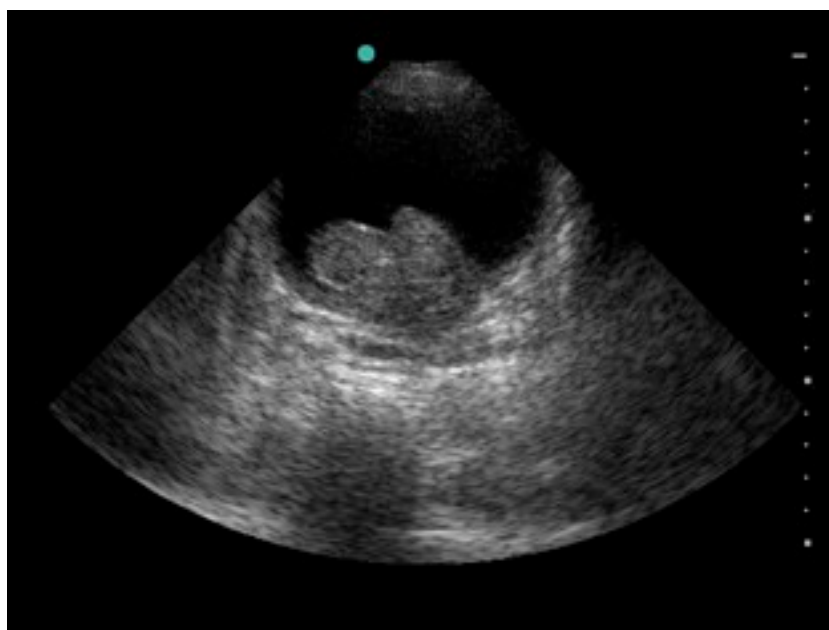
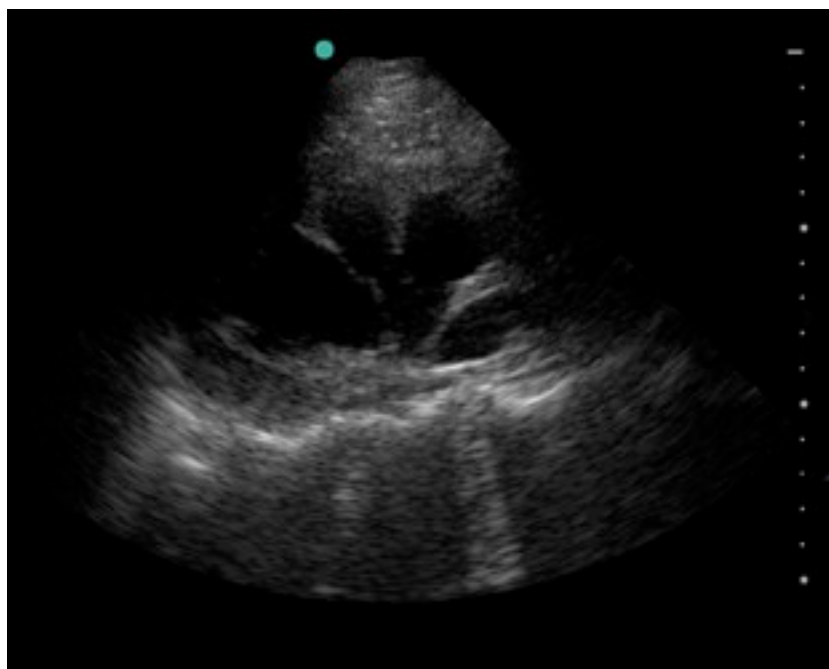
Physical exam notes a cachectic elderly male, with normal vital signs. His bladder was large on palpation.

Laboratory

The creatinine level was markedly increased at 8, which is suggestive of new renal failure.

Ultrasound

A bedside renal ultrasound showed bilateral hydro-nephrosis depicted here in a sagittal view of the left kidney. The renal pyramids and collecting system are dilated with hypoechoic fluid (urine). A transverse view of the bladder reveals a hyperechoic, fixed mass along the posterior bladder wall.



Case resolution

The patient was diagnosed with obstructive renal failure, which is likely due to the bladder mass. A foley catheter was placed. The patient's symptoms resolved, and he was able to void through the catheter. His creatinine improved, and he was discharged to follow up with a urologist for further evaluation of his bladder tumor.

For more information see the Renal chapter.

Case 13:

Hemiparesis

MELINO NDAYIZIGIYE MD

IRENEE UMULISA MD

GENE KWAN MD

GENE BUKHMAN MD PHD

SACHIN SHAH MD

History

A 16 year old girl presented to Rwinkwavu Hospital in Rwanda with acute onset right upper and lower extremity weakness, and aphasia. She denied headache, trauma, and fever.

Exam

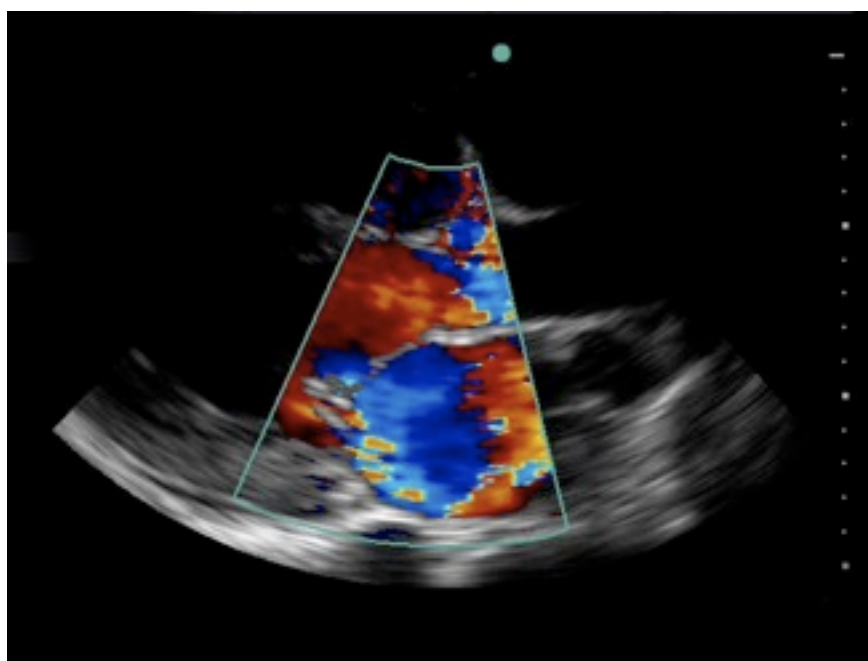
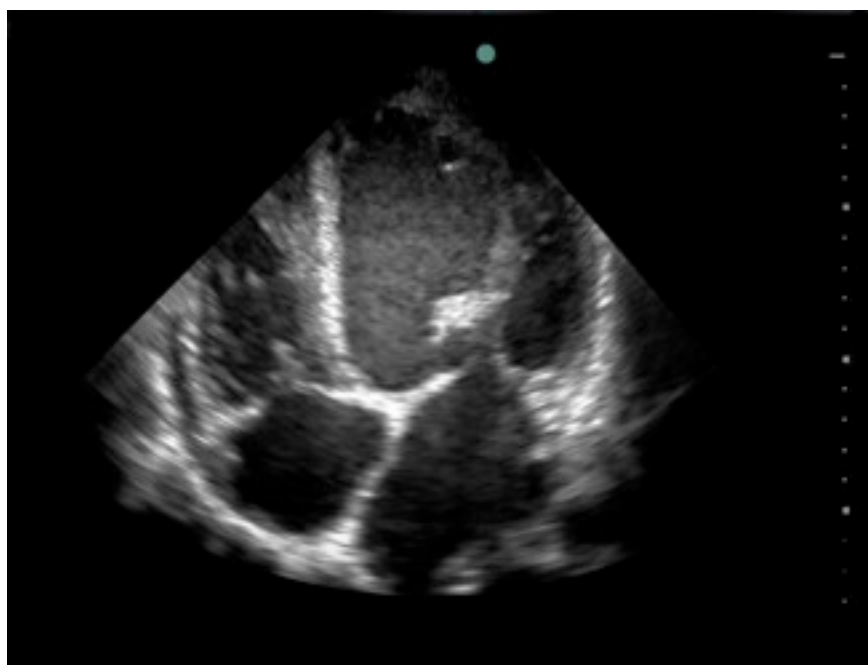
The patient's vital signs were normal, and she was alert and able to follow commands. Her cardiac exam was notable for a systolic murmur. Neurologic exam demonstrated facial droop, aphasia, and flaccid paralysis of the right upper and lower extremities consistent with a stroke.

Laboratory

HIV and syphilis tests were negative. A hemogram was within normal limits. Urine pregnancy test was negative. Blood cultures were sent to the city hospital.

Ultrasound

A bedside echocardiogram was performed. In the apical four chamber view, a vegetation was seen as a mobile, hyperechoic mass attached to the anterior mitral valve leaflet. In the parasternal long axis view, color Doppler demonstrated severe mitral regurgitation — seen here as blue color flow from the left ventricle back into the left atrium during systole.



Case resolution

The patient was diagnosed with a stroke, from likely septic emboli arising from endocarditis of the mitral valve. She was started on broad spectrum intravenous antibiotics. Physical therapy for stroke recovery was initiated. Her speech improved over the next several days, and education was provided to the patient regarding expected outcomes and post-stroke care.

For more information see the Echocardiography chapter.